

ARTICLE TITLE: Pathophysiological Basis of Human Papillomavirus in Penile Cancer: Key to Prevention and Delivery of More Effective Therapies**CONTINUING MEDICAL EDUCATION ACCREDITATION AND DESIGNATION STATEMENT:**

Blackwell Futura Media Services is accredited by the Accreditation Council for Continuing Medical Education to provide continuing medical education (CME) for physicians.

Blackwell Futura Media Services designates this enduring material for a maximum of 1.25 *AMA PRA Category 1 Credit™*. Physicians should only claim credit commensurate with the extent of their participation in the activity.

CONTINUING NURSING EDUCATION ACCREDITATION AND DESIGNATION STATEMENT:

The American Cancer Society (ACS) is accredited as a provider of continuing nursing education (CNE) by the American Nurses Credentialing Center's Commission on Accreditation.

Accredited status does not imply endorsement by the ACS or the American Nurses Credentialing Center of any commercial products displayed or discussed in conjunction with an educational activity. The ACS gratefully acknowledges the sponsorship provided by Wiley for hosting these CNE activities.

EDUCATIONAL OBJECTIVES:

After reading the article "Pathophysiological Basis of Human Papillomavirus in Penile Cancer: Key to Prevention and Delivery of More Effective Therapies," the learner should be able to:

1. Summarize the epidemiology and pathogenesis of penile cancer.
2. Review basic principles of multimodality treatment for patients with penile cancer.

ACTIVITY DISCLOSURES:

No commercial support has been accepted related to the development or publication of this activity.

ACS CONTINUING PROFESSIONAL EDUCATION COMMITTEE DISCLOSURES:

Editor, Director of Continuing Professional Education, and ACS Director of Medical Content:

Ted Gansler, MD, MBA, MPH, has no financial relationships or interests to disclose.

Deputy Editor and ACS Director of Cancer Control Intervention:

Durado Brooks, MD, MPH, has no financial relationships or interests to disclose.

Lead Nurse Planner and Associate Editor:

Marcia Grant, RN, PhD, FAAN, has no financial relationships or interests to disclose.

Nurse Planner:

Cathy Meade, PhD, RN, FAAN, has no financial relationships or interests to disclose.

Associate Editor and ACS Chief Cancer Control Officer:

Richard C. Wender, MD, has no financial relationships or interests to disclose.

NURSING ADVISORY BOARD DISCLOSURES:

Maureen Berg, RN, has no financial relationships or interests to disclose.

Susan Jackson, RN, MPH, has no financial relationships or interests to disclose.

Barbara Lesser, BSN, MSN, has no financial relationships or interests to disclose.

AUTHOR DISCLOSURES:

Peter A. Johnstone reports consulting fees from Novocure, Inc. outside the submitted work. Anna R. Giuliano reports an investigator-initiated grant from Merck & Company and serves on the Merck advisory board. Philippe E. Spiess, Jasreman Dhillon, and Adam S. Baumgarten have no financial relationships or interests to disclose.

The peer reviewers disclose no conflicts of interest. Identities of the reviewers are not disclosed, in line with the standard accepted practices of medical journal peer review.

SCORING:

A score of 70% or better is needed to pass a quiz containing 10 questions (7 correct answers), or 80% or better for 5 questions (4 correct answers).

CME INSTRUCTIONS ON RECEIVING CME CREDIT:

This activity is intended for physicians. For information concerning the applicability and acceptance of CME credit for this activity, please consult your professional licensing board.

This activity is designed to be completed within 1.25 hours; physicians should claim only those credits that reflect the time actually spent in the activity. To successfully earn credit, participants must complete the activity during the valid credit period, which is up to 2 years from the time of initial publication.

CNE INSTRUCTIONS ON RECEIVING CNE CREDIT:

This activity is intended for nurses. For information concerning the applicability and acceptance of CNE credit for this activity, please consult your professional licensing board.

This activity is designed to be completed within 1.25 hours; nurses should claim only those credits that reflect the time actually spent in the activity. To successfully earn credit, participants must complete the activity during the valid credit period, which is up to 2 years from the time of initial publication.

FOLLOW THESE STEPS TO EARN CREDIT:

- Log on to acsjournals.com/ce.
- Read the target audience, educational objectives, and activity disclosures.
- Read the activity contents in print or online format.
- Reflect on the activity contents.
- Access the examination, and choose the best answer to each question.
- Complete the required evaluation component of the activity.
- Claim your certificate.

This activity will be available for CME/CNE credit for 1 year following its launch date. At that time, it will be reviewed and potentially updated and extended for an additional 12 months.

All CME/CNE quizzes are offered online **FREE OF CHARGE**. Please log in at acsjournals.com/ce. New users can register for a **FREE** account. Registration will allow you to track your past and ongoing activities. After successfully completing each quiz, you may instantly print a certificate, and your online record of completed courses will be updated automatically.

Pathophysiological Basis of Human Papillomavirus in Penile Cancer: Key to Prevention and Delivery of More Effective Therapies

Philippe E. Spiess, MD, MS, FRCS(C)¹; Jasreman Dhillon, MD²; Adam S. Baumgarten, MD³; Peter A. Johnstone, MD, FACR⁴; Anna R. Giuliano, PhD⁵

CME

CNE

¹Associate Member, Department of Genitourinary Oncology, Moffitt Cancer Center, Tampa, FL; ²Assistant Member, Department of Anatomical Pathology, Moffitt Cancer Center, Tampa, FL; ³Urology Resident Physician, Department of Genitourinary Oncology, Moffitt Cancer Center, Tampa, FL; ⁴Senior Member, Department of Radiation Oncology, Moffitt Cancer Center, Tampa, FL; ⁵Senior Member, Department of Infection and Cancer, Moffitt Cancer Center, Tampa, FL.

Corresponding author: Philippe E. Spiess, MD, MS, FRCS(C), Department of Genitourinary Oncology, Moffitt Cancer Center, 12902 Magnolia Drive, Office 12538, Tampa, FL 33612; philippe.spiess@moffitt.org

Disclosures: No specific funding was disclosed. Peter A. Johnstone reports personal fees from Novocure outside the submitted work. Anna R. Giuliano reports an investigator-initiated grant from Merck & Company and serves on the Merck advisory board. Phillippe E. Spiess, Jasreman Dhillon, and Adam S. Baumgarten report no conflicts of interest.

doi: 10.3322/caac.21354. Available online at cancerjournal.com

ABSTRACT: Squamous cell carcinoma (SCC) of the penis is a rare malignancy in the United States, with a significantly higher incidence—up to 20 to 30 times greater—in areas of Africa and South America. This can be explained in part by the significantly greater prevalence of sexually transmitted diseases among high-risk males often having unprotected sex with multiple sexual partners. Human papillomavirus (HPV) has been implicated as the infectious pathway by which several these penile neoplasms originate from precursor lesions. In this regard, a fundamental understanding of HPV in penile carcinogenesis can have meaningful implications in understanding 1) the diagnosis of HPV-related precursor penile lesions, 2) targeting HPV-specific molecular pathways, and 3) cancer prevention. Using vaccination programs not only may improve patient outcomes but also may minimize the need for highly aggressive and often debilitating surgical resection. *CA Cancer J Clin* 2016;66:481–495. © 2016 American Cancer Society.

Keywords: diagnosis, human papillomavirus, penile cancer, prevention, review, treatment, vaccination

Practical Implications for Continuing Education

- > A significant proportion of penile cancers are related to HPV.
- > Effective prevention of penile cancer among high-risk populations should entail the adoption of HPV vaccination programs.
- > Novel therapeutic agents, including immune checkpoint inhibitors, offer great promise in the management of advanced penile cancer.

Introduction

Penile cancer is a rare malignancy, accounting for 0.24% of all neoplasms among men in the United States.¹ Squamous cell carcinoma (SCC) is the most frequently reported pathology of penile tumors, and over 90% have this histology.² The diagnosis and management of penile cancer have been plagued by disappointing outcomes because of a paucity of knowledge on the molecular pathways implicated in the development and progression of such tumors; the rarity of cases treated at individual centers, resulting in limited expertise; and the heterogeneous therapeutic approaches offered at most nontertiary care referral centers. There is no question that the implementation of national (National Comprehensive Care Network [NCCN]) and international (European Urological Association [EUA]) treatment guidelines have been pivotal not only in establishing standards of care but in providing diagnostic and treatment benchmarks that health care professionals can adopt in clinical practice using a sound, evidence-based approach.^{3,4} One of the most meaningful advances made in our fundamental understanding of penile cancer pertains to recognizing that there are 2 molecularly divergent pathways for

penile carcinogenesis: human papillomavirus (HPV)-induced and non-HPV-induced pathways.⁵ It is estimated that between 50% and 80% of penile neoplasms may be HPV-induced, making this an essential mechanism by which the majority of such tumors arise.⁶ Our recognition that HPV mediates the carcinogenesis of most penile tumors offers a unique opportunity to potentially prevent the disease using vaccination programs in specific high-risk patient populations or to diagnose lesions in precancerous or early stage/grade disease. Finally, treatment options specifically tailored to HPV status using local (surgery, radiotherapy) and systemic therapies have been proposed and are actively being investigated.⁷

The aims of this review article are to provide a comprehensive review of the molecular and pathophysiological (HPV and non-HPV) pathways in penile cancer, to highlight potential opportunities for the prevention of penile cancer and its incipient precursor lesions using targeted HPV vaccination programs, to provide clinical updates in the current diagnosis and management of penile cancer, and to discuss future horizons in penile cancer and HPV research that will likely further refine our treatment armamentarium.

Molecular and Pathophysiological Pathways in Penile Cancer

Risk factors associated with penile cancer are high-risk HPV infection, genital warts/condylomas, inflammation, lichen sclerosis, phimosis, poor hygiene, lack of circumcision during childhood, exposure to chemicals, cigarette smoking, genetic background, and smegma retention.⁸ Penile intraepithelial neoplasia (PeIN) is defined by the World Health Organization as an alteration of the penile squamous epithelium characterized by dysplastic changes with an intact basement membrane. PeIN is said to be the precursor lesion of invasive SCC and, just like penile carcinoma, can be classified as HPV-related (undifferentiated PeIN, such as warty, basaloid, and mixed warty-basaloid) or non-HPV-related (differentiated PeIN). Differentiated PeIN is usually associated with lichen sclerosis and chronic inflammation (Fig. 1).⁹

HPV is a DNA virus. Currently, there are more than 100 different known types of HPV viruses, of which 20 are known to infect the genital tract.¹⁰ The rate of HPV infection in penile cancers varies from 20% up to greater than 75%.¹¹ The frequency of HPV DNA in carcinomas of the penis varies, depending on the virus detection method used and the geographical region studied. HPV types 16, 18, 31, 33, 45, 56, and 65 are examples of high-risk HPV viruses that are frequently associated with penile cancer. Types 6 and 11 are examples of low-risk viruses that are detected frequently in benign lesions like condyloma acuminatum

and less commonly in carcinomas. Coinfection with more than one HPV type is common in patients with HPV.

The squamous epithelium is affected by the virus essentially in 2 ways: either as viral infection or as viral-associated precancer. Viral infection is responsible for lesions such as condyloma and mild dysplasia. These represent largely transient HPV infections in which the squamous epithelium supports virion production and produces a morphologic low-grade lesion; whereas, in precancerous lesions (HPV-associated PeINs), the viral genome integrates into the host genome, and viral oncogene overexpression drives cell proliferation to produce a clonal expansion of undifferentiated cells that carry a risk of malignant transformation. HPVs have circular, double-stranded DNA genomes that encode 8 genes, of which E6 and E7 have transforming properties. The viral E6 and E7 oncoproteins are necessary for malignant transformation of the host cell. Viral E6 and E7 get integrated into the host genome. E6 protein has oncogenic activities that are both dependent and independent of *p53*,¹² which plays an important role in controlling cell proliferation and growth arrest after DNA damage by ionizing radiation.¹³ E6 associates with the tumor-suppressor gene product *p53*, whereby it stimulates the degradation of *p53*, promoting cell proliferation. The E6-promoted degradation of *p53* is adenosine triphosphate-dependent and involves the ubiquitin-dependent protease system.¹² *P53* mutations are not seen in HPV-related tumors such as cervical cancers.¹⁴ In contrast, in HPV-negative tumors, *p53* is mutated and may be independently associated with lymph node metastases (Fig. 2).^{15,16}

The E7 proteins encoded by high-risk HPVs bind with the tumor-suppressor retinoblastoma (*Rb*) gene product with much higher affinity compared with those encoded by low-risk HPVs, such as HPV6 and HPV11. One of the major biochemical functions of *Rb* is to bind E2F-family transcription factors and repress the expression of replication enzyme genes.¹³ The ability to repress the expression of replication enzyme genes correlates with the tumor-suppression function of *Rb*. E7 disrupts the interaction between *Rb* and E2F, resulting in the release of E2F factors in their transcriptionally active forms.¹⁷ These complexes lead to autonomous cell proliferation without G1 cell-cycle stops. This allows nuclear accumulation of the cyclin-dependent kinase inhibitor p16ink4a, which inhibits G1 cyclin-dependent kinase 4 (CDKN4), CDKN6, and cyclin D-dependent kinases, initiating phosphorylation of the *Rb* tumor-suppressor protein. The immunohistochemical demonstration of p16ink4a overexpression serves as a surrogate marker for a transcriptionally active (transforming), high-risk HPV infection.¹⁸ Low-risk HPV infections do not lead to p16ink4a overexpression.¹⁹

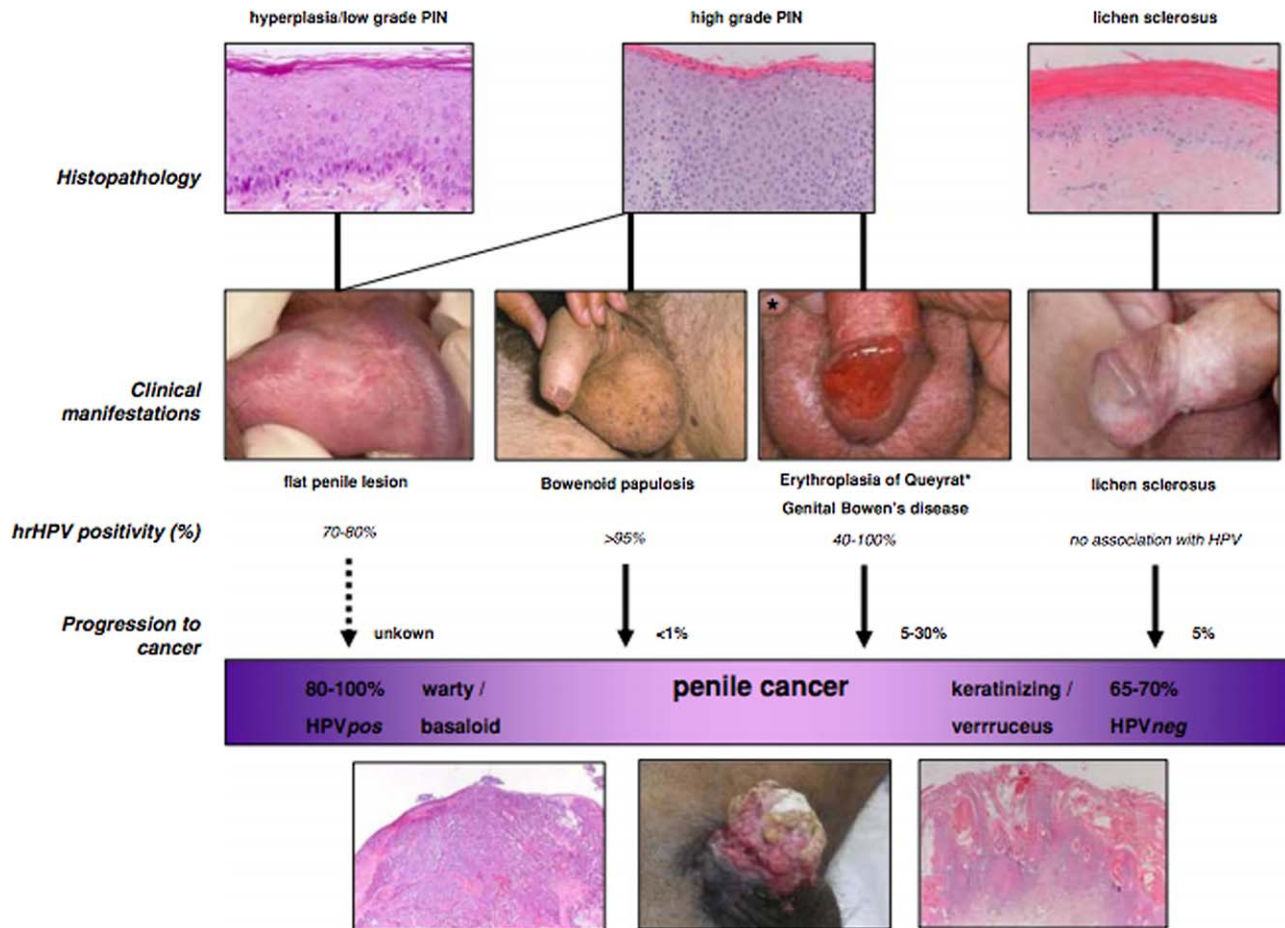


FIGURE 1. Correlations Between Histology, Human Papillomavirus Presence, Clinical Manifestation, and Putative Transformation of Penile Precursor Lesions Into Penile Cancer. hrHPV indicates high-risk human papillomavirus; neg, negative; PIN, penile intraepithelial neoplasia; pos, positive. Reprinted with explicit permission from: Bleeker MC, Heideman DA, Snijders PJ, Horenblas S, Diliner J, Meijer CJ. Penile cancer: epidemiology, pathogenesis and prevention. *World J Urol.* 2009;23:141-150.⁹

P16 immunohistochemistry measures the protein product of the tumor-suppressor gene *CDKN2A*, which is lost in the vast majority of HPV-negative tumors but is universally wild type and expressed in HPV-associated tumors. In HPV-associated tumors, E7 viral oncoproteins degrade *RB1* and enhance p16 expression. *RB1* loss can occur in HPV-negative tumors as well via mutations, resulting in p16 expression. Hence, p16 expression is not specific to HPV-associated cancers and also can occur in HPV-negative cancers.²⁰

HPV-negative penile carcinogenesis is less well understood but has been linked to *p53* mutations.²¹ These cancers are associated with lichen sclerosus and lichen planus and are believed to arise from precursor lesions identified as differentiated PeIN,^{22,23} which are considered aggressive with rapid progression to invasive cancer. Differentiated intraepithelial neoplasia lacks p16ink4a overexpression but typically shows nuclear *p53* expression in atypical basal keratinocytes.²⁴ Various studies have demonstrated that *p53* expression in tumor cells predicts a poor prognosis.²⁵⁻²⁷ P53 expression represents an independent, adverse prognostic parameter. P21 is a cyclin-dependent kinase

inhibitor that is induced by *p53*. It is a tumor-suppressor gene whose induction leads to cell cycle arrest. In a study by Gunia et al, p21 and cyclin D1 were not significantly associated with disease-specific mortality in multivariate analysis.²⁶ The major pathways and mediators involved in the development of penile preneoplastic lesions and neoplasms are listed in Table 1.¹⁶

Ki-67 is a nonhistone nuclear matrix protein that is expressed in all phases of the cell cycle except G0.²⁸ A high Ki-67 labeling index is associated with more aggressive behavior. However, it reportedly does not have any prognostic value for cancer-specific survival or overall survival.^{29,30} In a study by Kayes et al, Ki-67 expression determined by immunohistochemistry had a significant prognostic impact on overall survival in bivariate analysis. Higher levels of Ki-67 expression were associated with poorer clinical outcomes. However, it had no independent prognostic value in a multivariable model.³¹

In addition to Ki-67, other proliferation markers that have been studied in patients with penile carcinoma are minichromosome maintenance 2 (MCM2) protein and Geminin. Studies to date analyzing the role of MCM2 and

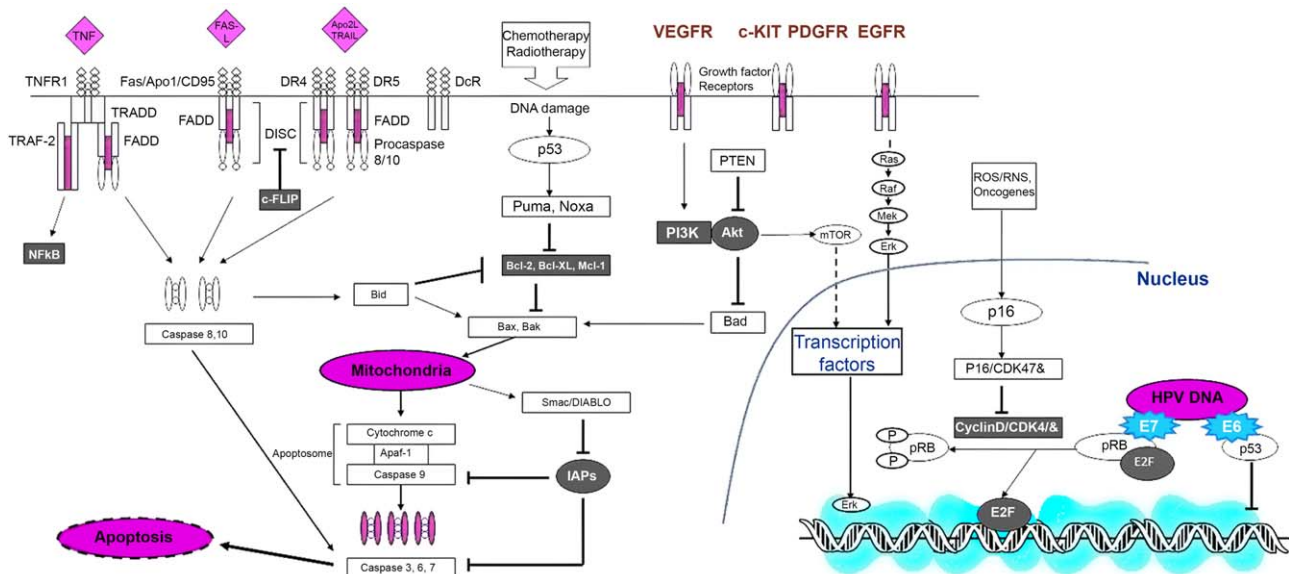


FIGURE 2. Schematic Diagram Illustrating Molecular Pathways Implicated in Human Papillomavirus (HPV)-Associated and Non-HPV-Associated Penile Cancer. Akt indicates protein kinase B; Apaf-1, apoptotic peptidase activating factor 1; Apo1, APO protein 1; Bad, B-cell lymphoma 2 (BCL2)-associated agonist of cell death; Bak, BCL2 antagonist/killer 1; Bax, BCL2-associated X protein; Bcl-2, B-cell lymphoma 2; Bcl-XL, B-cell lymphoma 2, extra large; Bid, BH3-interacting domain death agonist; CDK4/6, cyclin-dependent kinase 4/6; c-FLIP, cellular FADD-like interleukin-1 β -inhibitory protein; DcR, decoy receptor; DISC, death-inducing signaling complex; DR4/DR5, death receptors 4 and 5; E2F, gene group that codifies a family of transcription factors in higher eukaryotes; E6/E7, E6 and E7 oncoproteins; EGFR, epidermal growth factor receptor; Erk, extracellular signal-regulated kinase; FADD, tumor necrosis factor receptor superfamily 6 (Fas)-associated with death domain; Fas, tumor necrosis factor receptor super family 6; FAS-L, Fas ligand; HPV, human papillomavirus; IAPs, inhibitor of apoptosis proteins; Mcl-1, myeloid cell leukemia 1; Mek, mitogen activated protein kinase kinase; mTOR, mammalian target of rapamycin; NF- κ B, nuclear factor κ B; Noxa, phorbol-12-myristate-13-acetate-induced protein 1; P, protein; p16, cyclin-dependent kinase inhibitor 2A; p53, tumor protein 53; PDGFR, platelet-derived growth factor receptor; pRB, retinoblastoma protein; PTEN, phosphatase and tensin homolog; Puma, p53 up-regulated modular of apoptosis; Raf, v-raf murine leukemia viral oncogene homolog; Ras, rat sarcoma (a family of proteins); RNS, reactive nitrogen species; ROS, reactive oxygen species; Smac/DIABLO, second mitochondria-derived activator of caspase/direct inhibitor of apoptosis-binding protein with low isoelectric point; TNF, tumor necrosis factor; TNFR1, TNF receptor 1; TRADD, TNF receptor superfamily, member 1A-associated with death domain; TRAF-2, TNF receptor-associated factor 2; TRAIL, TNF-related apoptosis-inducing ligand; VEGFR, vascular endothelial growth factor receptor. Reprinted with explicit permission from: Protzel C, Spiess PE. Molecular research in penile cancer—lessons learned from the past and bright horizons for the future? *Int J Mol Sci.* 2013;14:19494-19505.¹⁶

Geminin in penile cancer have produced somewhat conflicting data. A study by May et al demonstrated that MCM2 and Geminin labeling indices were prognostic indicators and predictors of locoregional metastasis. However, they failed to have a significant, independent prognostic impact on cancer-specific survival.³⁰ Kayes et al found a significant prognostic impact of MCM2 on overall survival in univariate analysis. However, both MCM2 and Geminin failed to demonstrate any significant independent prognostic value in multivariate analysis.³¹

The epidermal growth factor receptor (EGFR)/human epidermal growth factor receptor (HER)/phosphoinositide 3-kinase (PI3K)/phosphatase and tensin homolog (PTEN)/ protein kinase B (Akt)/mammalian target of rapamycin (mTOR)/glycogen synthase kinase 3(GSK-3) (EGFR-HER-PI3K-PTEN-Akt-mTOR-GSK-3) pathway plays a prominent role in regulating the cell cycle. The PI3K-Akt-mTOR pathway is an intracellular signaling pathway important in regulating the cell cycle, including cell differentiation, migration, proliferation, and survival. The human epidermal growth factor receptor family is composed of EGFR, HER2, HER3, and HER4 transmembrane tyrosine kinase receptors. Extracellular ligand

binding to HER receptors leads to tyrosine phosphorylation and activation.³² Overexpression of HER family proteins has been linked to a worse prognosis in several cancers. Stankiewicz et al have suggested a greater role of EGFR in HPV-independent penile carcinogenesis. Those authors postulate that, for HPV-positive penile cancers, EGFR activation plays a role in its early stage; and, after HPV integration, it sustains cell proliferation that is independent of EGFR through disruption of the RB/p16 pathway by E6/E7 oncoproteins, as previously discussed.³² EGFR activation by overexpression is an early event in the history of penile cancer and generally is considered to have a negative impact on prognosis. In a recent study by McDaniel et al, genomic profiling was performed on penile cancer specimens, and EGFR amplifications were identified in 9% of cases.³³ However, in a study by Gou et al, no correlation was observed between EGFR expression and tumor grade, stage, or lymph node metastases.³⁴

Penile cancers are known to express HER3 and HER4 but not HER2.³² It has been suggested that, in penile cancer, HPV may up-regulate HER3 protein expression, possibly through its viral E6 and/or E7 oncoproteins, as it does with HER2 protein in human cervical keratinocytes.³⁵

TABLE 1. Molecular Changes Reported for Penile Carcinomas

CARCINOGENESIS	PROLIFERATION/INVASION	METASTASES
Inflammation	Growth factors/receptors	Metastases suppressor genes
COX-2	EGFR	<i>KA11</i>
PGE-2	HER-3/HER-4	<i>Nm23H1</i>
	VEGF	
Tumor suppressor genes	PI3K/PTEN/AKT	
<i>p53</i>		
<i>p16</i>	EMT	
<i>PTEN</i>	MMP2/MMP9	
	E-cadherin	
Oncogenes	Tenascin C	
<i>HPV E6/E7</i>	Annexins	
<i>MYC</i>	Glut1	
Apoptosis/cell death		
DR4/DR5		
Bcl-2/BAX		
<i>p53</i>		
Telomerases		

AKT, protein kinase B; BAX, B-cell lymphoma 2-associated X protein; bcl-2, B-cell lymphoma 2; COX-2, cyclooxygenase-2; DR4/DR5, death receptors 4 and 5; EGFR, epidermal growth factor receptor; EMT, epithelial-mesenchymal transition; Glut1, glucose transporter 1; HER-3/HER-4, human epidermal growth factor receptors 3 and 4; *HPV E6/E7*, human papillomavirus E6 and E7 oncoproteins; *KA11*, type I keratin KA11; MMP2/MMP9, matrix metalloproteinases 2 and 9; *MYC*, v-Myc avian myelocytomatosis viral oncogene homolog; *Nm23H1*, NME/NM23 nucleoside diphosphate kinase 1; *p16*, cyclin-dependent kinase inhibitor 2A; *p53*, tumor protein 53; PGE-2, prostaglandin E2; PI3K, phosphoinositide 3-kinase; *PTEN*, phosphatase and tensin homolog; VEGF, vascular endothelial growth factor. Reprinted with explicit permission from: Protzel C, Spiess PE. Molecular research in penile cancer—lessons learned from the past and bright horizons for the future? *Int J Mol Sci*. 2013;14:19494-19505.¹⁶

Activation of HER receptors by various growth factors stimulates intracellular signaling pathways, including the PI3K/Akt and rat sarcoma proto-oncogene–RAF proto-oncogene serine/threonine–protein kinase–mitogen-activated protein kinase kinase–extracellular signal-regulated kinase (Ras-Raf-MEK-ERK) pathways. Akt targets include B-cell lymphoma 2 (Bcl-2) family proteins; cell-cycle regulators like p53, p21, and p27; and Fas ligand and forkhead transcription factors (FOXO).³⁶ There are 3 isoforms of Akt in mammals: Akt1, Akt2, and Akt3. Various tumors overexpress different Akt isoforms.^{37,38} In penile cancer, Akt1 has been positively associated, along with HER3 and HER4, with tumor grade and progression.³²

The PI3K/Akt signaling pathway is antagonized by *PTEN*.³⁹ Loss of *PTEN* expression in penile cancer is not known to affect phosphorylated Akt protein expression, suggesting that HER3 and HER4 proteins may have a greater

impact than *PTEN* on increased activation of the PI3K/Akt pathway.³² mTOR signaling is altered in penile carcinomas. In a study by Ferrandiz-Pulido et al, phosphorylated eukaryotic initiation factor 4E (peIF4E) and phosphorylated mTOR (pmTOR) overexpression were correlated with aggressive behavior in penile cancer, and p53 and pmTOR were overexpressed particularly in HPV-negative tumors.⁴⁰

The EGFR-RAS-RAF signaling pathway plays an important role in the regulation of tumor cell survival and proliferation. There are 3 different human *RAS* genes: Kirsten rat sarcoma viral oncogene homolog (*KRAS*), Harvey rat sarcoma viral oncogene homolog (*HRAS*), and neuroblastoma rat sarcoma viral oncogene homolog (*NRAS*). RAS proteins are small guanosine triphosphate-hydrolyzing enzymes (GTPases) downstream of *EGFR* that are central mediators for cell proliferation, survival, and differentiation. *RAS* can activate several downstream effectors, including the PI3K-AKT-mTOR pathway, which is involved in cell survival, and the RAS-RAF-MEK-ERK pathway, which is involved in cell proliferation. *KRAS* mutations are mostly found in codons 12 and 13 (exon 2) and occasionally in codon 61 (exon 3) when studied in different tumor types.^{41,42} Only rare cases of penile cancers with mutations involving *KRAS* have been reported.^{34,43} Although EGFR is detected immunohistochemically in a large subset of penile cancers, it is not known whether its expression is associated with the presence of an *EGFR* gene mutation.⁴⁴ Because the *KRAS*/v-Raf murine sarcoma viral oncogene homolog B (*BRAF*) pathway is a major EGFR-dependent signaling pathway, *KRAS* mutation may lead to anti-EGFR treatment failure. However, because of high EGFR expression and rare *KRAS* mutations in penile cancer, anti-EGFR therapy may represent an effective treatment option for this disease.^{34,45,46} Currently, there are ongoing phase 2 trials with irreversible EGFR and Her2 inhibitors, afatinib and dacomitinib, for advanced/metastatic SCC of the penis.

The *BRAF* gene is a component of the EGFR-RAS-RAF signaling pathway. It encodes a RAS-regulated kinase that mediates cell growth, differentiation, apoptosis, and malignant transformation. *BRAF* mutations have not been reported in penile cancer to date.³⁴ RAS-association domain family 1A (*RASSF1A*) is expressed in all nonmalignant epithelial cells and exerts its tumor-suppressor activity via RAS-mediated apoptosis.^{47,48} In a study by Gou et al, loss of *RASSF1A* protein expression was common and was observed in 96.67% of the 150 penile carcinomas analyzed, whereas *KRAS* mutation was rare and was detected in only 1 of 94 carcinomas analyzed, suggesting that *RASSF1A* inactivation may exclude the necessity of *KRAS* activation to alter RAS signaling in carcinogenesis.³⁴

Mutually exclusive mutations have been identified in the PI3K and RAS pathways, indicating that either pathway is sufficient for the development of penile cancer.¹⁶

V-myc avian myelocytomatosis viral oncogene homolog (*MYC*) is a proto-oncogene that regulates cellular proliferation, differentiation, and apoptosis and many times is up-regulated in some forms of cancer. In penile cancer, *MYC* gains progressively increased during tumor progression and were identified as an independent factor for poor prognosis.⁴⁹ Expression of c-myc was increased in HPV-positive tumors in that study, indicating direct activation of *MYC* by the virus.

E-cadherin is a cell-to-cell adhesion molecule, low levels of which are associated with an increased risk of metastases of tumor cells. Low levels of E-cadherin expression have been reported to increase the risk of lymph node metastases in penile cancer.⁵⁰ Matrix metalloproteinase 2 (MMP-2) and MMP-9 are part of a group of enzymes that degrade type IV collagen in the basement membrane and are involved in the invasion mechanism. In the same study, the authors did not find any correlation of MMP-2 and MMP-9 immunoreactivity with the risk of lymph node metastases.⁵⁰

HPV infection induces an immune reaction in an immunocompetent host, which leads to the generation of HPV-specific memory T lymphocytes. Lohneis et al have suggested that the tumor microenvironment in HPV-positive carcinomas is different from that in HPV-negative carcinomas.⁵¹ Although additional studies are required to confirm this, one can hypothesize that the penile tumors with intense immune cell infiltrate are HPV-positive and may respond to antiprogrammed cell death protein 1 (PD-1) drugs. These drugs are currently being researched in other HPV-mediated cancers.

Cyclooxygenase-2 (COX-2) and prostaglandin E2 (PGE2) are key mediators in inflammation-induced carcinogenesis. Cyclooxygenase catalyzes the synthesis of prostaglandin H2 (PGH2), which is converted by microsomal prostaglandin E synthase (mPGES-1) into PGE2. COX-2 and mPGES-1 are overexpressed in penile cancer. Golijanin et al observed high levels of COX-2 and mPGES-1 in PeIN, invasive SCC, and lymph node metastases. Increased levels of COX-2 were detected in penile SCC arising in an HPV16 transgenic mouse, suggesting that a selective COX-2 inhibitor may inhibit the formation or growth of HPV-related SCCs.⁵² However, more studies are required to confirm this hypothesis.

So far, large numbers of biomarkers have been analyzed in cases of penile cancer, many of which have not been discussed in this review, eg, KAI1 (kangai 1), CD147 (cluster of differentiation 147 [basigin]), annexins, and the monoclonal antibody D2-40. The biomarkers have been tested in a few retrospective studies with small case numbers.

Additional studies with larger case numbers are needed to clearly establish their prognostic impact and the role of biomarker inhibitors in this relatively rare malignancy.

Prevention of Penile Cancer and Preneoplastic Lesions

Although penile cancer incidence is low, several studies among men have shown that the presence of external genitalia HPV of any HPV type can be up to 71-73%, with the incidence of new genital HPV infection being exceedingly high similar to the incidence rates reported for HPV-positive cervical tumors among women.⁵³ These observations have led to studies investigating the factors associated with genital HPV infection, the progression of infection to carcinogenesis, and the prevention of infections with HPV vaccination.

Among the first male HPV studies were those examining HPV seroprevalence in men compared with women.⁵⁴ In every study conducted, lower HPV seroprevalence was observed in men compared with women.⁵⁵ This low prevalence of serum antibodies to HPV in men has recently been explained by a low rate of seroconversion after HPV infection in men.⁵⁶ For example, approximately 60% of women will develop antibodies to HPV16 within 24 months of initial infection. In contrast, only 10% of men develop HPV antibodies after natural infection.⁵⁷ Unlike women, in whom antibodies in response to natural HPV infection confer partial protection against new infections with the same HPV type, among the men who seroconvert after natural HPV infection, no protection against subsequent infection is observed.⁵⁸ In fact, in prospective studies, subsequent recurrences of the same genital HPV genotypes were observed among men throughout the lifespan.⁵⁹ Related to the lack of immunity conferred from past HPV infection in men, a higher transmission of HPV from women to men than from men to women has been observed.^{60,61} Together, these findings indicate that men remain susceptible to genital HPV infection throughout their lifespan, a conclusion supported by epidemiologic studies showing sustained HPV prevalence and incidence throughout the lifespan of men.⁶²

Numerous modifiable and nonmodifiable factors have been associated with genital HPV burden among men. Among the modifiable factors, infrequent condom use,^{63,64} current tobacco use,^{65,66} alcohol consumption,⁶⁷ and herpes simplex virus 2 (HSV2) and chlamydia infections⁶⁸ have been associated with higher genital HPV seroprevalence and incidence in men. Infant as well as adult medical male circumcision provides partial protection against HPV (with protection varying by HPV genotype).⁶⁹⁻⁷³ Consistent with the lower penile cancer incidence among men of Asian descent, a significantly lower burden of genital HPV

infection has been observed in this population compared with that in other racial/ethnic groups.^{74,75}

The rate of progression from genital HPV infection to disease varies by HPV genotype.^{76,77} In one study, 26% of men with a genital HPV6 infection progressed to an HPV6-positive condyloma, and 24% of men with a genital HPV11 infection progressed to an HPV11-positive condyloma, with rapid rates of progression to disease after initial genital infection (ie, a median of 7.7 months). In contrast, despite the high prevalence of genital HPV16 infection observed in men (approximately 6%), progression of HPV16 infection to PeIN was rare, with only 2% progressing within a 24-month period. Progression of HPV16 infection was relatively slow, with 50% of infections requiring more than 19 months for PeIN to be detected. However, it is important to note that, in prospective studies, all diagnosed PeIN lesions were HPV-positive, and the majority were positive for HPV type 16, 6, or 11,^{77,78} genotypes that patients are protected against by Gardasil (Merck & Company, Kenilworth, NJ) vaccination.⁷⁹

As discussed above, infection with HPV rarely results in the development of antibodies in men; and, if antibodies do develop, then these are not protective against subsequent infection or neoplastic progression.⁵⁸ In contrast, 100% of young adult males vaccinated with Gardasil produce a type-specific antibody at levels log-fold higher than the levels observed after natural HPV infection.⁸⁰ In the only international phase 3 trial of the quadrivalent HPV vaccine Gardasil, the vaccine was efficacious in preventing HPV type 6, 11, 16, and 18-related external genital lesions (EGLs) in men ages 16 to 26 years (Table 2).⁷⁹ Vaccine efficacy against these HPV-related EGLs in the intent-to-treat population was high (65.5%; 95% confidence interval [CI], 45.8%-78.6%), as was its efficacy against the development of any EGL, regardless of HPV genotypes (60.2%; 95% CI, 40.8%-73.8%). In the per protocol efficacy (PPE) population, Gardasil reduced the incidence of HPV type 6, 11, 16, and 18-related EGLs by 90.4% (95% CI, 69.2%-98.1%). Efficacy against condyloma in the PPE population was 89.4% (95% CI, 65.5%-97.9%). In addition, Gardasil was efficacious against HPV type 6, 11, 16, and 18-related persistent infection and HPV DNA detection. The only cases of PeIN (grades I-III) that were diagnosed in that trial were among the placebo control group. Because only 3 cases were observed in the PPE population, efficacy (presumed to be 100%) was not reported to the US Food and Drug Administration (FDA); hence, an indication for the prevention of penile cancer is not part of the vaccine label. On the basis of the condyloma data, the FDA licensed Gardasil for use in males ages 9 to 26 years for the prevention of genital warts (condyloma) in November 2009. Altogether, these results are encouraging and hold promise for

an ultimate reduction in genital HPV infection and its related lesions among men, most notably if the vaccine is successfully disseminated among a large proportion of the male population. To this end, in 2011, the Advisory Committee on Immunization Practice of the US Centers for Disease Control and Prevention recommended routine HPV vaccination of males as well as females at the target age of 11 or 12 years and up to age 21 years for males. Since this recommendation, approximately 22% of US adolescent males between ages of 13 and 17 years have received all 3 doses of Gardasil.⁸¹ Clearly more work is needed to increase vaccine dissemination to males in the United States and other countries. To date, very few countries have gender-neutral national HPV vaccination policies, including the United States, Israel, Australia, and Austria. More recently, the immunogenicity and safety of Gardasil 9, which protects against HPV types 6, 11, 16, 18, 31, 33, 45, 52, and 58, has been demonstrated in adolescent and young adult males.^{82,83} Licensure of Gardasil 9 for adolescent males ages 9 to 15 years occurred in 2014, with the expectation that FDA licensure for young adult males ages 16 to 26 years will occur in the near future. To maintain consistent vaccine recommendations, the Advisory Committee on Immunization Practice has extended its male vaccination recommendation (males ages 9-21 years) to Gardasil 9 in 2015 with an increase in the upper age range to 26 years for high-risk and immunocompromised males.

Clinical Updates in Penile Cancer

The diagnosis and management of penile cancer has undergone a significant paradigm shift in recent years, with the fundamental understanding that patients and health care professionals alike have been hesitant to recommend aggressive surgical resection attributable to the life-altering change and poor quality of life faced by patients when undergoing such potentially debilitating treatment.⁸⁴ As a consequence, patients with favorable primary penile malignancies (in situ, Ta, and select T1 tumors of lower grade) may be suitable candidates to undergo penile-sparing treatment approaches, including topical therapy, wide local excision with primary reapproximation or reconstruction, and penile brachytherapy (at centers with expertise in this area).⁸⁵⁻⁸⁸ Prior studies have similarly refuted the previously held belief that 2-cm surgical margins are required to ensure tumor eradication in favor of less than 5-mm margins. The smaller margin is adequate without compromising oncological outcomes and has corroborated the merits of penile sparing surgery in many cases.⁸⁹ Selective adoption of such treatment modalities in select patients now offers the ability to maintain sexual function and minimally disturb quality of life—most importantly, not at the expense of a worse oncological outcome. As a result, the

TABLE 2. Efficacy of Quadrivalent Vaccine Against the Development of External Genital Lesions in the Intention-to-Treat Population^a

VARIABLE	QUADRIVALENT HPV VACCINE			PLACEBO			OBSERVED EFFICACY (95% CI), %
	CASES OF EGL, NO.	PERSON-YEARS AT RISK	RATE: NO./100 PERSON-YEARS AT RISK	CASES OF EGL, NO.	PERSON-YEARS AT RISK	RATE: NO./100 PERSON-YEARS AT RISK	
HPV type							
Any type	36	4612.6	0.80	89	4538.6	2.00	60.2 (40.8 to 73.8)
Type 6, 11, 16, or 18	27	4625.7	0.58	77	4556.5	1.69	65.5 (45.8 to 78.6)
Type 6	21	4635.8	0.45	51	4576.0	1.11	59.4 (31.2 to 76.8)
Type 11	6	4663.7	0.13	25	4606.6	0.54	76.3 (40.8 to 92.0)
Type 16	3	4663.1	0.06	10	4621.9	0.22	70.3 (−15.5 to 94.7)
Type 18	2	4670.0	0.04	3	4627.9	0.06	33.9 (−476.7 to 94.5)
Sexual orientation ^b							
Heterosexual males	21	4153.9	0.51	57	4087.5	1.39	63.7 (39.3 to 79.1)
Males who had sex with male partners	6	471.8	1.27	20	469.0	4.26	70.2 (23.0 to 90.2)
Lesion type ^c							
Condyloma acuminatum	24	4635.4	0.52	72	4558.8	1.58	67.2 (47.3 to 80.3)
All PIN lesions	6	4658.7	0.13	5	4628.2	0.11	−19.2 (−393.8 to 69.7)
PIN grade 1	3	4666.1	0.06	4	4629.7	0.09	25.6 (−339.9 to 89.1)
PIN grade 2 or 4	3	4663.1	0.06	2	4628.6	0.04	−48.9 (−1682.6 to 82.9)
Penile, perianal, or perineal cancer	0	4670.6	0	0	4630.5	0.00	−

95% CI indicates 95% confidence interval; EGL, external genital lesions external genital lesions with diagnosis of condyloma acuminatum; HPV, human papillomavirus; PIN, penile, perianal, or perineal intraepithelial neoplasia. ^aData shown are for patients who had at least one follow-up visit after day 1. Patients were counted once in each applicable category. A patient may have been included in more than one category. ^bThere were 1653 heterosexual males and 290 males who had sex with male partners. ^cThere were 115 cases of condylomata acuminata associated with any HPV type in the intention-to-treat population (32 in the vaccine group and 83 in the placebo group). Of these 115 cases, 20 involved patients with biopsy specimens that tested positive for more than 1 of the 14 HPV types tested (2 in the vaccine group and 18 in the placebo group). Reprinted with explicit permission from the Massachusetts Medical Society: Giuliano AR, Palefsky JM, Goldstone S, et al. Efficacy of quadrivalent HPV vaccine against HPV infection and disease in males. *N Engl J Med*. 2011;364:401-411.⁷⁹ ©2011 the Massachusetts Medical Society.

suitable recommendation of penile-sparing treatment approaches has been integrated into NCCN and EUA guidelines.^{3,4} However, it is important to emphasize that treatment-specific outcomes depend on appropriate clinical staging, which sometimes may require magnetic resonance imaging and/or penile ultrasound to rule out a more locally advanced, primary penile tumor (T2-T4).^{90,91} Similarly, very rigorous follow-up after treatment cannot be overemphasized. With most recurrences occurring within the first 12 months, surveillance every 3 months over that period is recommended, with the unequivocal performance of a biopsy of any suspected local recurrence.⁹²

The involvement of inguinal lymph nodes in patients with penile cancer remains the single most important prognostic factor, and the benefits of early versus delayed inguinal lymph node dissection have been established.^{93,94} Similarly, the indication for conducting an inguinal lymph node dissection (ILND) in the absence of palpable inguinal

lymphadenopathy has been strongly correlated with pathological findings of the primary penile tumor. Patients with pathologic T1 (pT1) tumors that are high grade or have the presence of lymphovascular invasion and patients with pT2 to pT4 tumors currently are recommended for ILND.⁹⁵ Recently however, the consistency in primary tumor grade assignment has been called into question, with prior single blinded studies among genitourinary pathologists demonstrating a high degree of inconsistency in uniformly assigning a given grade.^{96,97} Consequently, one may question the accuracy of using the present primary tumor characteristics in deciding which patients who have penile cancer without palpable inguinal lymphadenopathy should undergo an ILND. The diagnostic and therapeutic benefits of ILND are unquestionable, particularly when conducted in the setting of low-volume clinical lymph node (cN1) metastasis; however, there has been some reticence in the more widespread recommendation for ILND, in large part because of

the high risk of perioperative complications.⁹⁸ Prior retrospective studies have documented that, despite the many advances in surgical technique and clinical care pathways, the incidence of such complications remains disappointingly high. Most complications pertain to wound-related complications; and many of these can be predicted based on patient characteristics, postoperative pathology, and surgery-specific details.^{99,100} In an effort to reduce the morbidity of evaluating inguinal lymph nodes in patients with penile cancer, a group from the Netherlands Cancer Institute has pioneered the approach of dynamic sentinel lymph node biopsy using a combination of radiotracer and blue dye, with quite favorable outcomes (sensitivity, $\geq 88\%$); however, few sites have the required volume or expertise with such techniques, making this treatment available only at certain centers of excellence worldwide.¹⁰¹

A similar effort to surgically resect and evaluate inguinal lymph nodes with a minimally invasive technique using pure laparoscopic or robotic-assisted techniques has been reported with promising results, although the findings are limited by a relatively short-term follow-up.^{102,103} This technique adheres to the anatomic boundaries of surgical dissection established in open surgery but avoids many wound-related complications because of the limited size of the necessary laparoscopic sites (typically 12–15 mm each). More widespread adoption of this technique is cautioned, particularly in the setting of bulky inguinal adenopathy (cN2/cN3) or after previous neoadjuvant chemotherapy, radiation, or both.

The potential role of positron emission tomography-computed tomography imaging using the nuclear radiotracer ¹⁸F-fluorodeoxyglucose in the evaluation of inguinal lymph nodes among patients with penile cancer has been actively pursued in recent years and shows great promise. Currently, this modality is best used in the setting of patients with palpable inguinal adenopathy in deciphering the potential occult metastatic nature of a given lymph node(s). Its utility in patients who have penile cancer without palpable inguinal lymph nodes has been disappointing, with little to no clinical yield when used in this setting.^{104,105}

One of the clinical conundrums in the management of penile cancer involves which patients should undergo pelvic lymph node dissection. Previous retrospective studies have indicated that the size of inguinal lymph nodes (>3 cm), the presence of 3 more involved inguinal lymph nodes with metastases identified on ILND, and the presence of extranodal extension within the resected inguinal lymph node as useful criteria for making this clinical decision.^{106,107} In addition, a bilateral versus unilateral pelvic lymph node dissection should be contemplated if 4 or more positive inguinal lymph nodes (cumulatively, on both sides) are identified at the time of ILND.¹⁰⁸ Subsequent studies report improved overall survival in patients who have undergone a more extensive pelvic

lymph node dissection,¹⁰⁹ especially those who have positive pelvic lymph nodes with extranodal extension who are followed with adjuvant, systemic chemotherapy.¹¹⁰

The management of inguinal recurrences after a prior ILND has been associated with poor overall survival (typically less than 1 year). Salvage radiotherapy has provided a limited survival benefit.¹¹¹ Results from a recent multicenter trial suggest that, in the absence of other sites of metastatic disease, inguinal recurrences are surgically managed best by salvage ILND after neoadjuvant systemic chemotherapy, appreciating that such salvage surgery has an exceedingly high risk (over 50%) of perioperative complications because of wound-related complications.¹¹² Patients who have penile cancer with bulky inguinal lymph nodes (cN2/cN3 at presentation) are best approached in a multimodal approach consisting of neoadjuvant, systemic chemotherapy (typically using a platinum-based regimen) followed by aggressive surgical resection in appropriate responders.¹¹³ The landmark phase 2 study by Pagliaro et al nicely depicted the merit of such a treatment paradigm, with a 50% objective response reported. Subsequent consolidative ILND surgery revealed that 10% of these patients had no viable tumor on final pathology.¹¹⁴

Despite these great strides in our understanding and uniform approach to diagnosing and managing penile cancer, a recent study disappointingly highlighted that the overall prognosis of patients who have penile cancer with positive inguinal lymph nodes has not improved over recent years.¹¹⁵ Novel emerging therapies, such as the application of targeted therapies and EGFR monoclonal antibodies, have produced promising preliminary results when applied to select patients with advanced penile cancer exhibiting chemorefractory disease and may be a therapeutic consideration in select patients at this time.^{43,116} Nevertheless, the most promising avenue is the development of a more personalized and refined approach to advanced penile cancer, taking into account the HPV status of the lesions and the specific targetable molecular pathways in penile carcinogenesis, which are discussed below.

Future Horizons in Penile Cancer and HPV Research

Advances and refinements in the care of patients with penile cancer hold increasing promise thanks to meaningful progress in our fundamental understanding of the disease, with a plethora of novel systemic therapies presently being investigated in preclinical and early clinical trials.¹¹⁷

The present and future advances in the management of penile cancer are particularly promising in the area of HPV-directed prevention and treatment. This is available in large part because of significant advances in our appreciation of the interplay between HPV and host immunity of SCC in other organ sites, such as head and neck cancer.^{118–120} Focusing our attention on penile cancer prevention, the

initial approval by the FDA in 2009 of the quadrivalent HPV vaccine and, most recently, of the 9-valent HPV vaccine for use in females ages 9 to 26 years and in males ages 9 to 15 years, with the primary indication of HPV prevention, in all likelihood will have a meaningful impact on the incidence and natural history of penile cancer.^{121,122} The pivotal decision taken by the FDA to approve HPV vaccination in an effort to positively impact the incidence and natural history of HPV-related infections and malignancies was primarily based on research advances in the area of HPV-related cervical cancer.¹²³ One such randomized screening trial (the ARTISTIC trial) was conducted in the United Kingdom. That trial effectively demonstrated that HPV testing was a more effective way of cervical cancer screening than cervical cytology, and the investigators proposed that a substantial decrease in high-grade cervical cytology can be expected as a consequence of the institution of a primary HPV vaccination program.¹²⁴ The merits of adopting an HPV vaccination program is multifold, in that it can help prevent the progression of high-risk preneoplastic lesions with the appropriate implementation of primary screening within high-risk young male and female patient subsets.¹²⁵ The appreciation of the impact of HPV vaccination in its downstream prevention of HPV-related malignancies has fostered some very novel drug-delivery systems, like plasmid and nanoparticle novel gene systems, which are anticipated to significantly improve the effectiveness and adoption of HPV therapeutic vaccines in the years to come.^{126,127}

A recent systematic review evaluated which factors most accurately could predict the adoption of an HPV vaccination program.¹²⁸ Of the 28 studies reviewed, vaccination adoption was highest when 3 criteria were met: 1) patients believed the vaccine was effective, 2) treating physicians recommended it, and 3) HPV infection was likely. Hindrances to compliance with HPV vaccination included cost and concerns of some parents that this would promote adolescent sexual behavior. Clearly, these are all important topics that must be touched upon by parents and providers when discussing the merits of including young adolescent males and females in an HPV vaccination program.

In summary, great strides have been made in our appreciation of the positive impact that HPV vaccination can play in minimizing such infections and downstream infection-related cancers. This is a great area of promise that all health care providers must not only actively discuss with patients but similarly should promote ongoing research initiatives while breaking down current barriers to its more widespread adoption.

The therapeutic applicability of HPV status to the diagnosis and management of penile cancer is multifold. A study by Fujita et al suggests that HPV-positive and HPV-negative tumors in fact may exhibit unique radiographic features on contrast-enhanced computed tomography imaging that can be exploited in our approach to such tumors.¹²⁹ Although most

of our efforts pertaining to devising treatment approaches based on HPV-seropositivity status have been developing novel systemic therapies, several studies have emphasized that local therapies should take HPV status into consideration in ongoing treatment refinements. In a recent review, Mirghani et al highlight their findings that HPV-positive head and neck SCC is in fact more radiosensitive than non-HPV-related lesions.¹³⁰ In addition, a recent phase 2/3 trial highlighted that the combination of surgery and adjuvant radiotherapy could be tailored based on the HPV status of tumors.¹³¹ Clearly, there is still much to learn about how our locoregional therapies can be tailored based on HPV status. This has far-reaching implications not only for improving the efficacy of our treatment approaches but also for decreasing the morbidity of therapy.

Our fundamental understanding about how the HPV status of a given SCC tumor can impact the local immune milieu has truly been instrumental.¹³² It has been appreciated for the past decade or so that patients with HPV-positive head and neck tumors have a better clinical outcome than those with HPV-negative tumors, and similar subsequent conclusions have been made in penile SCC.¹⁰⁰ For some time, this clinical observation has been poorly understood, and no translational research studies or observations have corroborated these clinical findings. However, recently, it has been demonstrated that HPV-positive tumors have significantly higher numbers of infiltrating interferon/CD8-positive T lymphocytes, interleukin-17/CD8-positive T lymphocytes, myeloid dendritic cells, and proinflammatory chemokines.¹³³ In addition, HPV-positive tumors exhibited significantly lower Cox-2 messenger RNA (mRNA) and higher PD-1 mRNA levels compared with HPV-negative tumors. These very meaningful findings may significantly help decipher the improved prognosis attributed to HPV-positive SCC tumors. A recent study by Stevanovic et al provided some proof of concept by treating patients with metastatic cervical cancer who had previously received platinum-based chemotherapy or chemoradiotherapy in a prospective clinical trial.¹³⁴ Patients were treated with a single infusion of tumor-infiltrating T cells (TILs), which were selected preferably for HPV E6 and E7 reactivity. This cell infusion had been preceded by lymphocyte-depleting chemotherapy and was followed by aldesleukin. Three treatment responses (33%) were observed, 2 of which were complete responses at 15 and 22 months posttherapy. The HPV reactivity of T cells was strongly correlated with clinical response, providing a glimpse of the great promise of such directed therapy based on HPV status in SCC tumors. A prior study by Badoual et al similarly demonstrated that PD-1-expressing TILs are a favorable prognostic biomarker in patients with HPV-seropositive head and neck tumors.¹³⁵ In that study, using a mouse model, administration of an HPV vaccine

increased PD-1 expression on T cells with subsequent tumor regression. In this regard, the potential imparted to PD-1 blockade synergized with HPV vaccination in displaying antitumor activity was shown and clearly offers similar great promise in our future therapeutic approach to penile cancer. Recent translational studies similarly suggest that the PD-1 and PD-L1 pathways maybe instrumental in explaining the immune resistance of HPV related tumors, hence targeting them constitutes a new therapeutic approach to chemo-refractory tumors which have until now constituted a treatment conundrum.^{136,137} This paradigm shift in all likelihood may result in such patients (who, until now, typically were offered palliative/supportive treatment) now embarking on a new treatment paradigm specifically targeting the PD-1/PD-ligand 1 axis either as monomodal or multimodal therapy. In this regard, the combination of dual-blockade PD-1 and CTLA-4 (cytotoxic T-lymphocyte-associated protein 4) has been proposed and maybe one of the many avenues we use in a multifold mechanistic approach to improve therapeutic outcomes for our patients with advanced HPV-seropositive tumors.¹³⁸

Conclusion

Over the past decade, we have made some instrumental advances in our understanding of the molecular pathways implicated in penile carcinogenesis. In this regard, HPV infection is responsible for a majority of penile cancer cases seen worldwide. Although one may consider this malignancy of inconsequential importance compared with more common cancers, one must consider: 1) the significantly higher incidence and mortality rates in certain areas of South America and Africa; 2) the debilitating and adverse prognosis attributable to advanced disease, often requiring mutilating surgery for locoregional control; 3) the heterogeneous and often inconsistent patterns of diagnosis and care at most centers because of the paucity of cases; and 4) the lack of effective systemic agents for patients with metastatic disease. The creation and implementation of

evidence-based treatment guidelines for penile cancer both in North America and Europe (NCCN and EAU, respectively) have been instrumental in standardizing the diagnostic and therapeutic approach to this malignancy. In addition, an appreciation that penile-sparing treatment can be adapted to primary tumors of appropriate stage and grade and that multimodal approaches of systemic chemotherapy followed by consolidative surgery in favorable responders can be used in patients with bulky inguinal metastases (cN2/N3) are just 2 examples of how advances have been made in our evolving treatment paradigm. The greatest area of promise as it pertains to penile cancer results from the fundamental role played by HPV in the majority of penile tumors. This can be exploited to develop vaccination programs in high-risk male populations to decrease the incidence of penile cancer and similarly tailoring our local and systemic therapies based on the molecular pathways and immune-modulating environment disrupted by individual tumors. The future of penile cancer diagnosis and management without question will further refine HPV-targeted approaches in part using novel drug-delivery systems, such as nanoparticle HPV vaccination and emerging systemic therapies with HPV-directed TILs and PD-1/PD-L1 inhibitors, either as monotherapies or in combination with other novel agents. We have finally reached the era of personalized therapy in penile cancer and are exploiting HPV status to refine our treatment armamentarium. ■

Acknowledgement: The authors would like to thank Nicholas Gould for his expertise in the preparation of the figures included in this article and Linda Shepard in her administrative and editorial support.

Author Contributions: **Philippe E. Spiess:** Conceptualization, resources, writing—original draft, writing—review and editing, and supervision. **Jasreman Dhillon:** Conceptualization, resources, writing—original draft, and writing—review and editing. **Adam S. Baumgarten:** Conceptualization, resources, writing—original draft, writing—review and editing, and visualization. **Peter A. Johnstone:** Conceptualization, resources, writing—original draft, writing—review and editing, and visualization. **Anna R. Giuliano:** Conceptualization, resources, writing—original draft, writing—review and editing, visualization, and supervision.

References

1. Siegel RL, Miller KD, Jemal A. Cancer statistics, 2016. *CA Cancer J Clin*. 2016;66:7-30.
2. Cubilla AL, Velazquez EF, Young RH. Pseudohyperplastic squamous cell carcinoma of the penis associated with lichen sclerosus. An extremely well-differentiated, nonverruciform neoplasm that preferentially affects the foreskin and is frequently misdiagnosed: a report of 10 cases of a distinctive clinicopathologic entity. *Am J Surg Pathol*. 2004;28:895-900.
3. Clark PE, Spiess PE, Agarwal N, et al. Penile cancer: Clinical Practice Guidelines in Oncology. *J Natl Compr Canc Netw*. 2013;11:594-615.
4. Hakenberg OW, Comperat EM, Minhas S, Necchi A, Protzel C, Watkin N. EAU guidelines on penile cancer: 2014 update. *Eur Urol*. 2015;67:142-150.
5. Mannweiler S, Sygulla S, Winter E, Regauer S. Two major pathways of penile carcinogenesis: HPV-induced penile cancers overexpress p16ink4a, HPV-negative cancers associated with dermatoses express p53, but lack p16ink4a overexpression. *J Am Acad Dermatol*. 2013;69:73-81.
6. Backes DM, Kurman RJ, Pimenta JM, Smith JS. Systematic review of human papillomavirus prevalence in invasive penile cancer. *Cancer Causes Control*. 2009;20:449-457.
7. Hellner K, Munger K. Human papillomaviruses as therapeutic targets in human cancer. *Am J Clin Oncol*. 2011;29:1785-1794.
8. Mosconi AM, Roila F, Gatta G, Theodore C. Cancer of the penis. *Crit Rev Oncol Hematol*. 2005;53:165-177.
9. Bleeker MC, Heideman DA, Snijders PJ, Horenblas S, Diliner J, Meijer CJ. Penile cancer: epidemiology, pathogenesis and prevention. *World J Urol*. 2009;23:141-150.
10. Leto M, Santos Junior GF, Porro AM, Tomimori J. Human papillomavirus infection: etiopathogenesis, molecular biology and clinical manifestations. *An Bras Dermatol*. 2011;86:306-317.
11. Heideman DA, Waterboer T, Pawlita M, et al. Human papillomavirus-16 is the predominant type etiologically involved in penile squamous cell carcinoma. *Am J Clin Oncol*. 2007;25:4550-4556.

12. Scheffner M, Werness BA, Huibregtse JM, Levine AJ, Howley PM. The E6 oncoprotein encoded by human papillomavirus types 16 and 18 promotes the degradation of p53. *Cell*. 1990;63:1129-1136.
13. Lipinski MM, Jacks T. The retinoblastoma gene family in differentiation and development. *Oncogene*. 1999;18:7873-7882.
14. Crook T, Vousden KH. Properties of p53 mutations detected in primary and secondary cervical cancers suggest mechanisms of metastasis and involvement of environmental carcinogens. *EMBO J*. 1992;11:3935-3940.
15. Wichmann G, Rosolowski M, Krohn K, et al. The role of HPV RNA transcription, immune response-related gene expression and disruptive TP53 mutations in diagnostic and prognostic profiling of head and neck cancer. *Int J Cancer*. 2015;137:2846-2857.
16. Protzel C, Spiess PE. Molecular research in penile cancer—lessons learned from the past and bright horizons of the future? *Int J Mol Sci*. 2013;14:19494-19505.
17. Chellappan S, Kraus VB, Kroger B, et al. Adenovirus E1A, simian virus 40 tumor antigen, and human papillomavirus E7 protein share the capacity to disrupt the interaction between transcription factor E2F and the retinoblastoma gene product. *Proc Natl Acad Sci U S A*. 1992;89:4549-4553.
18. Reuschenbach M, Seiz M, von Knebel Doeberitz C, et al. Evaluation of cervical cone biopsies for coexpression of p16INK4a and Ki-67 in epithelial cells. *Int J Cancer*. 2012;130:388-394.
19. Gage JR, Meyers C, Wettstein FO. The E7 proteins of the nononcogenic human papillomavirus type 6b (HPV-6b) and of the oncogenic HPV-16 differ in retinoblastoma protein binding and other properties. *J Virol*. 1990;64:723-730.
20. Deng Z, Hasegawa M, Aoki K, et al. A comprehensive evaluation of human papillomavirus positive status and p16INK4a overexpression as a prognostic biomarker in head and neck squamous cell carcinoma. *Int J Oncol*. 2014;45:67-76.
21. Rocha RM, Ignacio JA, Jordan J, et al. A clinical, pathologic, and molecular study of p53 and murine double minute 2 in penile carcinogenesis and its relation to prognosis. *Hum Pathol*. 2012;43:481-488.
22. Oertell J, Caballero C, Iglesias M, et al. Differentiated precursor lesions and low-grade variants of squamous cell carcinomas are frequent findings in foreskins of patients from a region of high penile cancer incidence. *Histopathology*. 2011;58:925-933.
23. Velazquez EF, Chaux A, Cubilla AL. Histologic classification of penile intraepithelial neoplasia. *Semin Diagn Pathol*. 2012;29:96-102.
24. Chaux A, Pfannl R, Rodriguez IM, et al. Distinctive immunohistochemical profile of penile intraepithelial lesions: a study of 74 cases. *Am J Surg Pathol*. 2011;35:553-562.
25. Zhu Y, Zhou XY, Yao XD, Dai B, Ye DW. The prognostic significance of p53, Ki-67, epithelial cadherin and matrix metalloproteinase-9 in penile squamous cell carcinoma treated with surgery. *BJU Int*. 2007;100:204-208.
26. Gunia S, Kakies C, Erbersdobler A, Hakenberg OW, Koch S, May M. Expression of p53, p21 and cyclin D1 in penile cancer: p53 predicts poor prognosis. *J Clin Pathol*. 2012;65:232-236.
27. Soufir N, Queille S, Liboutet M, et al. Inactivation of the CDKN2A and the p53 tumour suppressor genes in external genital carcinomas and their precursors. *Br J Dermatol*. 2007;156:448-453.
28. Scholzen T, Gerdes J. The Ki-67 protein: from the known and the unknown. *J Cell Physiol*. 2000;182:311-322.
29. Stankiewicz E, Ng M, Cuzick J, et al. The prognostic value of Ki-67 expression in penile squamous cell carcinoma. *J Clin Pathol*. 2012;65:534-537.
30. May M, Burger M, Otto W, et al. Ki-67, mini-chromosome maintenance 2 protein (MCM2) and geminin have no independent prognostic relevance for cancer-specific survival in surgically treated squamous cell carcinoma of the penis. *BJU Int*. 2013;112:E383-E390.
31. Kayes OJ, Loddo M, Patel N, et al. DNA replication licensing factors and aneuploidy are linked to tumor cell cycle state and clinical outcome in penile carcinoma. *Clin Cancer Res*. 2009;15:7335-7344.
32. Stankiewicz E, Prowse DM, Ng M, et al. Alternative HER/PTEN/Akt pathway activation in HPV positive and negative penile carcinomas [serial online]. *PLoS One*. 2011;6:e17517.
33. McDaniel AS, Hovelson DH, Cani AK, et al. Genomic profiling of penile squamous cell carcinoma reveals new opportunities for targeted therapy. *Cancer Res*. 2015;75:5219-5227.
34. Gou HF, Li X, Qiu M, et al. Epidermal growth factor receptor (EGFR)-RAS signaling pathway in penile squamous cell carcinoma [serial online]. *PLoS One*. 2013;8:e62175.
35. Narisawa-Saito M, Handa K, Yugawa T, Ohno S, Fujita M, Kiyono T. HPV16 E6-mediated stabilization of ErbB2 in neoplastic transformation of human cervical keratinocytes. *Oncogene*. 2007;26:2988-2996.
36. Webster KA. Aktin in the nucleus. *Circ Res*. 2004;94:856-859.
37. Gonzalez E, McGraw TE. The Akt kinases: isoform specificity in metabolism and cancer. *Cell Cycle*. 2009;8:2502-2508.
38. Koseoglu S, Lu Z, Kumar K, Kirschmeier P, Zou J. AKT1, AKT2 and AKT3-dependent cell survival is cell line-specific and knockdown of all three isoforms selectively induces apoptosis in 20 human tumor cell lines. *Cancer Biol Ther*. 2007;6:755-762.
39. Wyatt LA, Filbin MT, Keirstead HS. PTEN inhibition enhances neurite outgrowth in human embryonic stem cell-derived neuronal progenitor cells. *J Comp Neurol*. 2014;522:2741-2755.
40. Ferrandiz-Pulido C, Masferrer E, Toll A, et al. mTOR signaling pathway in penile squamous cell carcinoma: pmTOR and pelf4E over expression correlate with aggressive tumor behavior. *J Urol*. 2013;190:2288-2295.
41. Lievre A, Bachet JB, Le Corre D, et al. KRAS mutation status is predictive of response to cetuximab therapy in colorectal cancer. *Cancer Res*. 2006;66:3992-3995.
42. Basavaraj C, Sierra P, Shivu J, Melarkode R, Montero E, Nair P. Nimotuzumab with chemoradiation confers a survival advantage in treatment-naive head and neck tumors over expressing EGFR. *Cancer Biol Ther*. 2010;10:673-681.
43. Andersson P, Kolaric A, Windahl T, Kirrander P, Soderkvist P, Karlsson MG. PIK3CA, HRAS and KRAS gene mutations in human penile cancer. *J Urol*. 2008;179:2030-2034.
44. Chaux A, Munari E, Katz B, et al. The epidermal growth factor receptor is frequently overexpressed in penile squamous cell carcinomas: a tissue microarray and digital image analysis study of 112 cases. *Hum Pathol*. 2013;44:2690-2695.
45. Carthon BC, Ng CS, Pettaway CA, Pagliaro LC. Epidermal growth factor receptor-targeted therapy in locally advanced or metastatic squamous cell carcinoma of the penis. *BJU Int*. 2014;113:871-877.
46. Necchi A, Nicolai N, Colechia M, et al. Proof of activity of anti-epidermal growth factor receptor-targeted therapy for relapsed squamous cell carcinoma of the penis. *J Clin Oncol*. 2011;29:e650-e652.
47. Dammann R, Li C, Yoon JH, Chin PL, Bates S, Pfeifer GP. Epigenetic inactivation of a RAS association domain family protein from the lung tumour suppressor locus 3p21.3. *Nat Genet*. 2000;25:315-319.
48. Vos MD, Ellis CA, Bell A, Birrer MJ, Clark GJ. Ras uses the novel tumor suppressor RASSF1 as an effector to mediate apoptosis. *J Biol Chem*. 2000;275:35669-35672.
49. Masferrer E, Ferrandiz-Pulido C, Lloveras B, et al. MYC copy number gains are associated with poor outcome in penile squamous cell carcinoma. *J Urol*. 2012;188:1965-1971.
50. Campos RS, Lopes A, Guimaraes GC, Carvalho AL, Soares FA. E-cadherin, MMP-2, and MMP-9 as prognostic markers in penile cancer: analysis of 125 patients. *Urology*. 2006;67:797-802.
51. Lohneis P, Boral S, Kaufmann AM, et al. Human papilloma virus status of penile squamous cell carcinoma is associated with differences in tumour-infiltrating T lymphocytes. *Virchows Arch*. 2015;466:323-331.
52. Golijanin D, Tan JY, Kazior A, et al. Cyclooxygenase-2 and microsomal prostaglandin E synthase-1 are overexpressed in squamous cell carcinoma of the penis. *Cancer Res*. 2004;10:1024-1031.
53. Giuliano AR, Lee JH, Fulp W, et al. Incidence and clearance of genital human papillomavirus infection in men (HIM): a cohort study. *Lancet*. 2011;377:932-940.
54. Giuliano AR, Nyitray AG, Kreimer AR, et al. EUROGIN 2014 roadmap: differences in human papillomavirus infection natural history, transmission and human papillomavirus-related cancer incidence by gender and anatomic site of infection. *Int J Cancer*. 2015;136:2752-2760.
55. Lu B, Viscidi RP, Wu Y, et al. Seroprevalence of human papillomavirus (HPV) type 6 and 16 vary by anatomic site of HPV infection in men. *Cancer Epidemiol Biomarkers Prev*. 2012;21:1542-1546.

56. Lu B, Viscidi RP, Villa LL, et al. Capsid antibody response to genital HPV 6, 11, 16, and 18 infection in healthy men. Paper presented at: 28th International Papillomavirus Conference and Clinical Workshop; November 30-December 6, 2012; San Juan, Puerto Rico.
57. Giuliano AR, Viscidi R, Torres BN, et al. Seroconversion following anal and genital HPV infection in men: the HIM study. *Papillomavirus Res.* 2015;1:109-115.
58. Lu B, Viscidi RP, Wu Y, et al. Prevalent serum antibody is not a marker of immune protection against acquisition of oncogenic HPV16 in men. *Cancer Res.* 2012;72:676-685.
59. Lu B, Lin HY, Nyitray AG, et al. Reinfection with type-specific genital human papillomavirus (HPV) is associated with age and duration of initial HPV infection. Paper presented at: 28th International Papillomavirus Conference and Clinical Workshop; November 30-December 6, 2012; San Juan, Puerto Rico.
60. Nyitray AG. Comparing and contrasting the natural history of anal HPV among women and men. Paper presented at: EUROGIN International Multidisciplinary Congress; November 3-6, 2013; Florence, Italy.
61. Nyitray AG, Fulp WJ, Lin HY, et al. Genital HPV transmission rates between heterosexual sexual partners. Paper presented at: 28th International Papillomavirus Conference and Clinical Workshop; November 30-December 6, 2012; San Juan, Puerto Rico.
62. Giuliano AR, Lazcano-Ponce E, Villa LL, et al. The human papillomavirus infection in men study: human papillomavirus prevalence and type distribution among men residing in Brazil, Mexico, and the United States. *Cancer Epidemiol Biomarkers Prev.* 2008;17:2036-2043.
63. Repp KK, Nielson CM, Fu R, et al. Male human papillomavirus prevalence and association with condom use in Brazil, Mexico, and the United States. *J Infect Dis.* 2012;205:1287-1293.
64. Pierce Campbell CM, Lin HY, Fulp W, et al. Consistent condom use reduces the genital human papillomavirus burden among high-risk men: the HPV Infection in Men study. *J Infect Dis.* 2013;208:373-384.
65. Schabath MB, Villa LL, Lazcano-Ponce E, Salmemon J, Quiterio M, Giuliano AR. Smoking and human papillomavirus (HPV) infection in the HPV in Men (HIM) study. *Cancer Epidemiol Biomarkers Prev.* 2012;21:102-110.
66. Schabath MB, Villa LL, Lin HY, et al. A prospective analysis of smoking and human papillomavirus infection among men in the HPV in Men study. *Int J Cancer.* 2014;134:2448-2457.
67. Schabath MB, Thompson ZJ, Egan KM, et al. Alcohol consumption and prevalence of human papillomavirus (HPV) infection among US men in the HPV in Men (HIM) study. *Sex Transm Infect.* 2015;91:61-67.
68. Alberts CJ, Schim van der Loeff MF, Papenfuss MR, et al. Association of Chlamydia trachomatis infection and herpes simplex virus type 2 serostatus with genital human papillomavirus infection in men: the HPV in Men study. *Sex Transm Infect.* 2013;40:508-515.
69. Albero G, Castellsague X, Lin HY, et al. Male circumcision and the incidence and clearance of genital human papillomavirus (HPV) infection in men: the HPV Infection in Men (HIM) cohort study [serial online]. *BMC Infect Dis.* 2014;14:75.
70. Giuliano AR, Lazcano E, Villa LL, et al. Circumcision and sexual behavior: factors independently associated with human papillomavirus detection among men in the HIM study. *Int J Cancer.* 2009;124:1251-1257.
71. Albero G, Villa LL, Lazcano-Ponce E, et al. Male circumcision and prevalence of genital human papillomavirus infection in men: a multinational study [serial online]. *BMC Infect Dis.* 2013;13:18.
72. Rositch AF, Mao L, Hudgens MG, et al. Risk of HIV acquisition among circumcised and uncircumcised young men with penile human papillomavirus infection. *AIDS.* 2014;28:745-752.
73. Wilson LE, Gravitt P, Tobian AA, et al. Male circumcision reduces penile high-risk human papillomavirus viral load in a randomised clinical trial in Rakai, Uganda. *Sex Transm Infect.* 2013;89:262-266.
74. Schabath MB, Villa LL, Lin HY, et al. Racial differences in the incidence and clearance of human papilloma virus (HPV): the HPV in Men (HIM) study. *Cancer Epidemiol Biomarkers Prev.* 2013;22:1762-1770.
75. Akogbe GO, Ajidahun A, Sirak B, et al. Race and prevalence of human papillomavirus infection among men residing in Brazil, Mexico and the United States. *Int J Cancer.* 2012;131:E282-E291.
76. Ingles DJ, Pierce Campbell CM, Messina JA, et al. HPV genotype- and age-specific analyses of external genital lesions among men in the HPV Infection in Men (HIM) study. *J Infect Dis.* 2014;211:1060-1067.
77. Sudenga SL, Ingles DJ, Pierce Campbell CM, et al. Genital HPV infection and progression to external genital lesions: The HIM Study. *Eur Urol.* 2016;69:166-173.
78. Ingles DJ, Pierce Campbell CM, Messina JA, et al. Human papillomavirus virus (HPV) genotype- and age-specific analyses of external genital lesions among men in the HPV Infection in Men (HIM) study. *J Infect Dis.* 2015;211:1060-1067.
79. Giuliano AR, Palefsky JM, Goldstone S, et al. Efficacy of quadrivalent HPV vaccine against HPV Infection and disease in males. *N Engl J Med.* 2011;364:401-411.
80. Hillman RJ, Giuliano AR, Palefsky JM, et al. Immunogenicity of the quadrivalent human papillomavirus (type 6/11/16/18) vaccine in males 16 to 26 years old. *Clin Vaccine Immunol.* 2012;19:261-267.
81. Reagan-Steiner S, Yankey D, Jeyarajah J, et al. National, regional, state, and selected local area vaccination coverage among adolescents aged 13-17 years—United States, 2014. *MMWR Morb Mortal Wkly Rep.* 2015;64:784-792.
82. Van Damme P, Olsson SE, Block S, et al. Immunogenicity and safety of a 9-valent HPV vaccine. *Pediatrics.* 2015;136:e28-e39.
83. Giuliano AR, Isaacs-Soriano K, Torres BN, et al. Immunogenicity and safety of Gardasil among mid-adult aged men (27-45 years)—the MAM Study. *Vaccine.* 2015;33:5640-5646.
84. Kieffer JM, Djajadiningrat RS, van Muilekom EA, Graafland NM, Horenblas S, Aaronson NK. Quality of life for patients treated for penile cancer. *J Urol.* 2014;192:1105-1110.
85. Alnajjar HM, Lam W, Bolgeri M, Rees RW, Perry MJ, Watkin NA. Treatment of carcinoma in situ of the glans penis with topical chemotherapy agents. *Eur Urol.* 2012;62:923-928.
86. Feldman AS, McDougal WS. Long-term outcome of excisional organ sparing surgery for carcinoma of the penis. *J Urol.* 2011;186:1303-1307.
87. Yang J, Chen J, Wu XF, et al. Glans preservation contributes to postoperative restoration of male sexual function: a multicenter clinical study of glans preserving surgery. *J Urol.* 2014;192:1410-1417.
88. Hasan S, Francis A, Hagenauer A, et al. The role of brachytherapy in organ preservation for penile cancer: a meta-analysis and review of the literature. *Brachytherapy.* 2015;14:517-524.
89. Philippou P, Shabbir M, Malone P, et al. Conservative surgery for squamous cell carcinoma of the penis: resection margins and long-term oncological control. *J Urol.* 2012;188:803-808.
90. Hanchanale V, Yeo L, Subedi N, et al. The accuracy of magnetic resonance imaging (MRI) in predicting the invasion of the tunica albuginea and the urethra during the primary staging of penile cancer. *BJU Int.* 2016;117:439-443.
91. Rocher L, Glas L, Cluzel G, Ifergan J, Bellin MF. Imaging tumours of the penis. *Diagn Interv Imaging.* 2012;93:319-328.
92. Leijte JA, Kirrander P, Antonini N, Windahl T, Horenblas S. Recurrence patterns of squamous cell carcinoma of the penis: recommendations for follow-up based on a two-centre analysis of 700 patients. *Eur Urol.* 2008;54:161-168.
93. Kroon BK, Horenblas S, Lont AP, Tanis PJ, Gallee MP, Nieweg OE. Patients with penile carcinoma benefit from immediate resection of clinically occult lymph node metastases. *J Urol.* 2005;173:816-819.
94. Spiess PE, Horenblas S, Pagliaro LC, et al. Current concepts in penile cancer. *J Natl Compr Canc Netw.* 2013;11:617-624.
95. Slaton JW, Morgenstern N, Levy DA, et al. Tumor stage, vascular invasion and the percentage of poorly differentiated cancer: independent prognosticators for inguinal lymph node metastasis in penile squamous cancer. *J Urol.* 2001;165:1138-1142.
96. Chaux A, Torres J, Pfannl R, et al. Histologic grade in penile squamous cell carcinoma: visual estimation versus digital measurement of proportions of grades, adverse prognosis with any proportion of grade 3 and correlation of a Gleason-like system with nodal metastasis. *Am J Surg Pathol.* 2009;33:1042-1048.
97. Kakies C, Lopez-Beltran A, Comperat E, et al. Reproducibility of histopathologic tumor grading in penile cancer—results of a European project. *Virchows Arch.* 2014;464:453-461.

98. Spiess PE, Hernandez MS, Pettaway CA. Contemporary inguinal lymph node dissection: minimizing complications. *World J Urol.* 2009;27:205-212.
99. Stuijver MM, Djajadiningrat RS, Graafland NM, Vincent AD, Lucas C, Horenblas S. Early wound complications after inguinal lymphadenectomy in penile cancer: a historical cohort study and risk-factor analysis. *Eur Urol.* 2013;64:486-492.
100. Gopman JM, Djajadiningrat RS, Baumgarten AS, et al. Predicting postoperative complications of inguinal lymph node dissection for penile cancer in an international multicentre cohort. *BJU Int.* 2015;116:196-201.
101. Sadeghi R, Gholami H, Zakavi SR, Kakhki VR, Tabasi KT, Horenblas S. Accuracy of sentinel lymph node biopsy for inguinal lymph node staging of penile squamous cell carcinoma: systematic review and meta-analysis of the literature. *J Urol.* 2012;187:25-31.
102. Josephson DY, Jacobsohn KM, Link BA, Wilson TG. Robotic-assisted endoscopic inguinal lymphadenectomy. *Urology.* 2009;73:167-170; discussion 170-161.
103. Master VA, Jafri SM, Moses KA, Ogan K, Kooby DA, Delman KA. Minimally invasive inguinal lymphadenectomy via endoscopic groin dissection: comprehensive assessment of immediate and long-term complications. *J Urol.* 2012;188:1176-1180.
104. Souillac I, Rigaud J, Ansquer C, Marconnet L, Bouchot O. Prospective evaluation of (18)F-fluorodeoxyglucose positron emission tomography-computerized tomography to assess inguinal lymph node status in invasive squamous cell carcinoma of the penis. *J Urol.* 2012;187:493-497.
105. Schlenker B, Scher B, Tiling R, et al. Detection of inguinal lymph node involvement in penile squamous cell carcinoma by 18F-fluorodeoxyglucose PET/CT: a prospective single-center study. *Urol Oncol.* 2012;30:55-59.
106. Lughezzani G, Catanzaro M, Torelli T, et al. The relationship between characteristics of inguinal lymph nodes and pelvic lymph node involvement in penile squamous cell carcinoma: a single institution experience. *J Urol.* 2014;191:977-982.
107. Djajadiningrat RS, van Werkhoven E, Horenblas S. Prophylactic pelvic lymph node dissection in patients with penile cancer. *J Urol.* 2015;193:1976-1980.
108. Zargar-Shoshtari K, Djajadiningrat R, Sharma P, et al. Establishing criteria for bilateral pelvic lymph node dissection in the management of penile cancer: lessons learned from an international multicenter collaboration. *J Urol.* 2015;194:696-701.
109. Zargar-Shoshtari K, Sharma P, Djajadiningrat R, et al. Extent of pelvic lymph node dissection in penile cancer may impact survival. *World J Urol.* 2016;34:353-359.
110. Sharma P, Djajadiningrat R, Zargar-Shoshtari K, et al. Adjuvant chemotherapy is associated with improved overall survival in pelvic node-positive penile cancer after lymph node dissection: a multi-institutional study [serial online]. *Urol Oncol.* 2015;33:496.e17-e23.
111. Graafland NM, Moonen LM, van Boven HH, van Werkhoven E, Kerst JM, Horenblas S. Inguinal recurrence following therapeutic lymphadenectomy for node positive penile carcinoma: outcome and implications for management. *J Urol.* 2011;185:888-893.
112. Baumgarten AS, Alhammali E, Hakky TS, et al. Salvage surgical resection for isolated locally recurrent inguinal lymph node metastasis of penile cancer: international study collaboration. *J Urol.* 2014;192:760-764.
113. Bermejo C, Busby JE, Spiess PE, Heller L, Pagliaro LC, Pettaway CA. Neoadjuvant chemotherapy followed by aggressive surgical consolidation for metastatic penile squamous cell carcinoma. *J Urol.* 2007;177:1335-1338.
114. Pagliaro LC, Williams DL, Daliani D, et al. Neoadjuvant paclitaxel, ifosfamide, and cisplatin chemotherapy for metastatic penile cancer: a phase II study. *J Clin Oncol.* 2010;28:3851-3857.
115. Djajadiningrat RS, Graafland NM, van Werkhoven E, et al. Contemporary management of regional nodes in penile cancer-improvement of survival? *J Urol.* 2014;191:68-73.
116. Necchi A, Giannatempo P, Lo Vullo S, et al. Panitumumab treatment for advanced penile squamous cell carcinoma when surgery and chemotherapy have failed [published online ahead of print August 11, 2015]. *Clin Genitourin Cancer.* doi: 10.1016/j.clgc.2015.08.001.
117. Agarwal G, Gupta S, Spiess PE. Novel targeted therapies for the treatment of penile cancer. *Expert Opin Drug Discov.* 2014;9:959-968.
118. Andersen AS, Koldjaer Solling AS, Ovesen T, Rusan M. The interplay between HPV and host immunity in head and neck squamous cell carcinoma. *Int J Cancer.* 2014;134:2755-2763.
119. Devaraj K, Gillison ML, Wu TC. Development of HPV vaccines for HPV-associated head and neck squamous cell carcinoma. *Crit Rev Oral Biol Med.* 2003;14:345-362.
120. Albers A, Abe K, Hunt J, et al. Antitumor activity of human papillomavirus type 16 E7-specific T cells against virally infected squamous cell carcinoma of the head and neck. *Cancer Res.* 2005;65:11146-11155.
121. Sledge JA. The male factor: human papillomavirus (HPV) and HPV4 vaccine acceptance among African American young men. *J Community Health.* 2015;40:834-842.
122. Petrosky E, Bocchini JA Jr, Hariri S, et al. Use of 9-valent human papillomavirus (HPV) vaccine: updated HPV vaccination recommendations of the advisory committee on immunization practices. *MMWR Morb Mortal Wkly Rep.* 2015;64:300-304.
123. Valdez M, Jeronimo J, Bansil P, et al. Effectiveness of novel, lower cost molecular human papillomavirus-based tests for cervical cancer screening in rural china. *Int J Cancer.* 2016;138:1452-1461.
124. C Kitchner H, Canfell K, Gilham C, et al. The clinical effectiveness and cost-effectiveness of primary human papillomavirus cervical screening in England: extended follow-up of the ARTISTIC randomised trial cohort through three screening rounds. *Health Technol Assess.* 2014;18:1-196.
125. Arbyn M, Ronco G, Anttila A, et al. Evidence regarding human papillomavirus testing in secondary prevention of cervical cancer. *Vaccine.* 2012;30(suppl 5):F88-F99.
126. Bolhassani A, Ghasemi N, Servis C, Taghikhani M, Rafati S. The efficiency of a novel delivery system (PEI600-Tat) in development of potent DNA vaccine using HPV16 E7 as a model antigen. *Drug Deliv.* 2009;16:196-204.
127. Saleh T, Bolhassani A, Shojaosadati SA, Aghasadeghi MR. MPG-based nanoparticle: an efficient delivery system for enhancing the potency of DNA vaccine expressing HPV16E7. *Vaccine.* 2015;33:3164-3170.
128. Brewer NT, Fazekas KI. Predictors of HPV vaccine acceptability: a theory-informed, systematic review. *Prev Med.* 2007;45:107-114.
129. Fujita A, Buch K, Li B, Kawashima Y, Qureshi MM, Sakai O. Difference between HPV-positive and HPV-negative non-oro-pharyngeal head and neck cancer: texture analysis features on CT. *J Comput Assist Tomogr.* 2016;40:43-47.
130. Mirghani H, Amen F, Tao Y, Deutsch E, Levy A. Increased radiosensitivity of HPV-positive head and neck cancers: Molecular basis and therapeutic perspectives. *Cancer Treat Rev.* 2015;41:844-852.
131. Owadally W, Hurt C, Timmins H, et al. PATHOS: a phase II/III trial of risk-stratified, reduced intensity adjuvant treatment in patients undergoing transoral surgery for human papillomavirus (HPV) positive oropharyngeal cancer [serial online]. *BMC Cancer.* 2015;15:602.
132. Partlova S, Boucek J, Kloudova K, et al. Distinct patterns of intratumoral immune cell infiltrates in patients with HPV-associated compared to non-virally induced head and neck squamous cell carcinoma [serial online]. *Oncoimmunology.* 2015;4:e965570.
133. Djajadiningrat RS, Jordanova ES, Kroon BK, et al. Human papillomavirus prevalence in invasive penile cancer and association with clinical outcome. *J Urol.* 2015;193:526-531.
134. Stevanovic S, Draper LM, Langhan MM, et al. Complete regression of metastatic cervical cancer after treatment with human papillomavirus-targeted tumor-infiltrating T cells. *J Clin Oncol.* 2015;33:1543-1550.
135. Badoual C, Hans S, Merillon N, et al. PD-1-expressing tumor-infiltrating T cells are a favorable prognostic biomarker in HPV-associated head and neck cancer. *Cancer Res.* 2013;73:128-138.
136. Lyford-Pike S, Peng S, Young GD, et al. Evidence for a role of the PD-1:PD-L1 pathway in immune resistance of HPV-associated head and neck squamous cell carcinoma. *Cancer Res.* 2013;73:1733-1741.
137. Yang W, Song Y, Lu YL, Sun JZ, Wang HW. Increased expression of programmed death (PD)-1 and its ligand PD-L1 correlates with impaired cell-mediated immunity in high-risk human papillomavirus-related cervical intraepithelial neoplasia. *Immunology.* 2013;139:513-522.
138. Swanson MS, Sinha UK. Rationale for combined blockade of PD-1 and CTLA-4 in advanced head and neck squamous cell cancer-review of current data. *Oral Oncol.* 2015;51:12-15.