

# Guidelines on Urological Trauma

D.J. Summertom (chair), N. Djakovic, N.D. Kitrey, F. Kuehhas,  
N. Lumen, E. Serafetinidis

# TABLE OF CONTENTS

# PAGE

|         |   |    |
|---------|---|----|
| 1.      | Background                                    | 6  |
| 1.1     | Methodology                                   | 6  |
| 1.1.1   | Evidence sources                              | 6  |
| 1.1.2   | Publication history                           | 6  |
| 1.1.3   | Potential conflict of interest statement      | 6  |
| 1.2     | Definition and Epidemiology                   | 7  |
| 1.2.1   | Genito-Urinary Trauma                         | 7  |
| 1.2.2   | Classification of trauma                      | 7  |
| 1.2.3   | Initial evaluation and treatment              | 8  |
| 1.3     | References                                    | 8  |
| 2.      | RENAL TRAUMA                                  | 9  |
| 2.1     | Introduction                                  | 9  |
| 2.2     | Mode of injury                                | 9  |
| 2.2.1   | Blunt renal injuries                          | 9  |
| 2.2.2   | Penetrating renal injuries                    | 9  |
| 2.2.3   | Injury classification                         | 10 |
| 2.3     | Diagnosis                                     | 10 |
| 2.3.1   | History and physical examination              | 10 |
| 2.3.1.1 | Recommendations                               | 11 |
| 2.3.2   | Laboratory evaluation                         | 11 |
| 2.3.2.1 | Recommendations                               | 11 |
| 2.3.3   | Imaging: criteria for radiographic assessment | 11 |
| 2.3.3.1 | Ultrasonography                               | 12 |
| 2.3.3.2 | Intravenous pyelography                       | 12 |
| 2.3.3.3 | One-shot intraoperative IVP                   | 12 |
| 2.3.3.4 | Computed tomography (CT)                      | 12 |
| 2.3.3.5 | Magnetic resonance imaging (MRI)              | 13 |
| 2.3.3.6 | Angiography                                   | 13 |
| 2.3.3.7 | Radionuclide scans                            | 13 |
| 2.3.3.8 | Recommendations                               | 13 |
| 2.4     | Treatment                                     | 14 |
| 2.4.1   | Indications for renal exploration             | 14 |
| 2.4.2   | Interventional radiology                      | 14 |
| 2.4.3   | Operative findings and reconstruction         | 15 |
| 2.4.4   | Non-operative management of renal injuries    | 15 |
| 2.4.4.1 | Blunt renal injuries                          | 15 |
| 2.4.4.2 | Penetrating renal injuries                    | 16 |
| 2.4.5   | Recommendations                               | 16 |
| 2.4.6   | Postoperative care and follow-up              | 17 |
| 2.4.7   | Recommendations                               | 17 |
| 2.4.8   | Complications                                 | 17 |
| 2.4.9   | Recommendations                               | 18 |
| 2.4.10  | Renal injury in the polytrauma patient        | 18 |
| 2.4.11  | Recommendations                               | 18 |
| 2.5     | Iatrogenic renal injuries                     | 18 |
| 2.5.1   | Introduction                                  | 18 |
| 2.5.2   | Incidence and aetiology                       | 18 |
| 2.5.3   | Diagnosis (clinical signs, imaging)           | 19 |
| 2.5.4   | Management                                    | 20 |
| 2.5.5   | Statements and recommendations                | 21 |
| 2.6     | Algorithms                                    | 21 |
| 2.7     | References                                    | 24 |
| 3.      | URETERAL TRAUMA                               | 32 |
| 3.1     | Aetiology                                     | 32 |
| 3.2     | Diagnosis                                     | 33 |
| 3.2.1   | Clinical diagnosis                            | 33 |

|           |   |    |
|-----------|---|----|
| 3.2.2     | Radiological diagnosis  | 33 |
| 3.3       | Prevention of iatrogenic trauma   | 33 |
| 3.4       | Management  | 33 |
| 3.4.1     | Uretero-ureterostomy  | 34 |
| 3.4.2     | Uretero-calycostomy   | 34 |
| 3.4.3     | Transuretero-ureterostomy   | 34 |
| 3.4.4     | Ureteral reimplantation with a psoas hitch  | 34 |
| 3.4.5     | Ureteral reimplantation with a Boari flap   | 35 |
| 3.4.6     | Ileal interposition graft   | 35 |
| 3.4.7     | Autotransplantation   | 35 |
| 3.5       | Statements and recommendations on ureteral trauma   | 35 |
| 3.6       | References  | 35 |
| 4.        | BLADDER TRAUMA  | 37 |
| 4.1       | Background, incidence and aetiology   | 37 |
| 4.1.1     | External (non-iatrogenic) trauma  | 37 |
| 4.1.2     | Iatrogenic trauma   | 37 |
| 4.2       | Risk factors  | 38 |
| 4.3       | Clinical signs and symptoms   | 38 |
| 4.3.1     | External trauma   | 38 |
| 4.3.2     | Iatrogenic trauma   | 39 |
| 4.3.2.1   | Perioperative: external iatrogenic bladder trauma   | 39 |
| 4.3.2.2   | Perioperative: internal iatrogenic bladder trauma   | 39 |
| 4.3.2.3   | Postoperative: unrecognised bladder injury  | 39 |
| 4.3.3     | Intravesical foreign body   | 39 |
| 4.4       | Imaging   | 39 |
| 4.4.1     | Cystography (conventional or CT)  | 39 |
| 4.4.2     | Cystoscopy  | 39 |
| 4.4.3     | Excretory phase of CT or IVP  | 40 |
| 4.4.4     | Ultrasound  | 40 |
| 4.5       | Treatment   | 40 |
| 4.5.1     | External trauma   | 40 |
| 4.5.1.1   | Blunt trauma: extraperitoneal rupture   | 40 |
| 4.5.1.2   | Blunt trauma: intraperitoneal rupture   | 40 |
| 4.5.1.3   | Penetrating injuries  | 40 |
| 4.5.1.4   | Bladder injuries with avulsion of lower abdominal wall or perineum and/or bladder tissue loss | 40 |
| 4.5.2     | Iatrogenic injuries   | 41 |
| 4.5.3     | Intravesical foreign body   | 41 |
| 4.5.4     | Postoperative management  | 41 |
| 4.6       | Recommendations   | 41 |
| 4.6.1     | Statements  | 41 |
| 4.6.2     | Recommendations   | 41 |
| 4.7       | References  | 42 |
| 5         | URETHRAL TRAUMA   | 45 |
| 5.1       | Anterior urethral injuries  | 45 |
| 5.2       | Posterior urethral injuries   | 46 |
| 5.3       | Urethral injuries in women  | 47 |
| 5.4       | Penetrating injuries to the perineum  | 47 |
| 5.5       | Diagnosis: initial emergency assessment   | 47 |
| 5.5.1     | Clinical assessment   | 47 |
| 5.5.2     | Radiographic examination  | 48 |
| 5.6       | Management  | 48 |
| 5.6.1     | Anterior urethral injuries  | 49 |
| 5.6.1.1   | Blunt anterior urethral injuries  | 49 |
| 5.6.1.1.1 | Acute management  | 49 |
| 5.6.1.1.2 | Delayed management  | 49 |
| 5.6.1.2   | Penetrating anterior urethral injuries  | 49 |
| 5.6.1.2.1 | Acute management  | 49 |

|             |   |    |
|-------------|---|----|
| 5.6.1.2.2   | Delayed management  | 49 |
| 5.6.2       | Posterior urethral injuries   | 50 |
| 5.6.2.1     | Blunt posterior urethral injuries   | 50 |
| 5.6.2.1.1   | Acute management  | 50 |
| 5.6.2.1.1.1 | Partial posterior urethral rupture  | 50 |
| 5.6.2.1.1.2 | Complete posterior urethral rupture   | 50 |
| 5.6.2.1.2   | Delayed management of posterior urethral injuries                             | 51 |
| 5.6.2.2     | Penetrating posterior urethral injuries                                       | 53 |
| 5.6.2.3     | Management of failed repair of posterior urethral rupture                     | 53 |
| 5.7         | Treatment algorithms  | 53 |
| 5.8         | Statements and recommendation on trauma of the urethra                        | 55 |
| 5.9         | Iatrogenic urethral trauma (IUhT)   | 56 |
| 5.9.1       | Introduction  | 56 |
| 5.9.2       | Causes of iatrogenic urethral trauma  | 56 |
| 5.9.2.1     | Transurethral catheterisation   | 56 |
| 5.9.2.2     | Transurethral surgery   | 57 |
| 5.9.2.3     | Surgical treatment for prostate cancer  | 57 |
| 5.9.2.4     | Radiotherapy for prostate cancer  | 58 |
| 5.9.2.5     | Major abdominal surgery and cystectomy  | 58 |
| 5.9.3       | Symptoms of iatrogenic urethral injury  | 59 |
| 5.9.4       | Diagnosis   | 59 |
| 5.9.5       | Treatment   | 59 |
| 5.9.6       | References  | 59 |
| 6.          | GENITAL TRAUMA  | 66 |
| 6.1         | Introduction and background   | 66 |
| 6.2         | General Principles and pathophysiology  | 67 |
| 6.2.1       | Gunshot wounds  | 67 |
| 6.2.2       | Bites   | 67 |
| 6.2.3       | Sexual Assault.   | 68 |
| 6.3         | Penile Trauma   | 68 |
| 6.3.1       | Blunt penile trauma   | 68 |
| 6.3.1.1     | Penile Fracture   | 68 |
| 6.3.2       | Penetrating penile trauma   | 68 |
| 6.3.3       | Penile avulsion injuries and amputation                                       | 69 |
| 6.4         | Scrotal Trauma  | 69 |
| 6.4.1       | Blunt scrotal trauma  | 69 |
| 6.4.1.1     | Testicular dislocation  | 70 |
| 6.4.1.2     | Haematocoele  | 70 |
| 6.4.1.3     | Testicular Rupture  | 70 |
| 6.4.2       | Penetrating scrotal trauma  | 70 |
| 6.5         | Genital Trauma in Females   | 71 |
| 6.5.1       | Blunt Vulvar Injuries   | 71 |
| 6.6         | References  | 71 |
| 7.          | MASS CASUALTY EVENTS, TRIAGE AND DAMAGE CONTROL                               | 74 |
| 7.1         | Definition  | 74 |
| 7.2         | Causes of mass casualty events  | 74 |
| 7.3         | Mechanisms of explosive injury  | 75 |
| 7.4         | Triage  | 75 |
| 7.4.1       | Primary triage  | 75 |
| 7.4.2       | Secondary triage  | 75 |
| 7.4.3       | Re-triage   | 75 |
| 7.5         | Principles of 'damage control'  | 75 |
| 7.6         | Urological aspects of 'damage control'  | 76 |
| 7.6.1       | The urological consultation in the emergency room during mass casualty events | 76 |
| 7.6.1.1     | Responsibility and primary overall assessment                                 | 76 |
| 7.6.1.2     | Imaging   | 76 |
| 7.6.1.3     | Primary management  | 76 |
| 7.6.2       | The urological consultation in the operating room during mass casualty events | 77 |

|     |   |    |
|-----|---|----|
|     | 7.6.2.1 Renal trauma                        | 77 |
|     | 7.6.2.2 Ureteral injuries                   | 78 |
|     | 7.6.2.3 Bladder injury                      | 79 |
|     | 7.6.2.4 Urethral injury                     | 79 |
|     | 7.6.2.5 Injury of the external genitalia    | 79 |
|     | 7.6.2.5.1 Temporary damage control measures | 79 |
| 7.7 | Summary                                     | 79 |
| 7.8 | References                                  | 79 |
| 8.  | ABBREVIATIONS USED IN THE TEXT              | 82 |

# 1. BACKGROUND

The European Association of Urology (EAU) Guidelines Group for Urological Trauma prepared these guidelines in order to assist medical professionals in the management of urological trauma.

## 1.1 Methodology

### 1.1.1 Evidence sources

The Urological Trauma guidelines are based on a review of the relevant literature, using on-line searches of the following databases: Medline, Embase, Cochrane, and other source documents published between 2002 and 2012. A critical assessment of the findings was made. The majority of publications on the subject are comprised of case reports and retrospective case series. The paucity of high-powered randomized controlled trials makes it difficult to draw meaningful conclusions. The panel recognizes this critical limitation.

A level of evidence (LE) and/or grade of recommendation (GR) have been assigned where possible. The aim of grading recommendations is to provide transparency between the underlying evidence and the recommendation given.

Levels of evidence and grade of guideline recommendations\*

**Table 1: Level of evidence (1)\***

| Level | Type of evidence  |
|-------|---|
| 1a    | Evidence obtained from meta-analysis of randomised trials.  |
| 1b    | Evidence obtained from at least one randomised trial.   |
| 2a    | Evidence obtained from one well-designed controlled study without randomisation.  |
| 2b    | Evidence obtained from at least one other type of well-designed quasi-experimental study.   |
| 3     | Evidence obtained from well-designed non-experimental studies, such as comparative studies, correlation studies and case reports. |
| 4     | Evidence obtained from expert committee reports or opinions or clinical experience of respected authorities.                      |

**Table 2: Grade of recommendation (1)\***

| Grade | Nature of recommendations  |
|-------|--|
| A     | Based on clinical studies of good quality and consistency addressing the specific recommendations and including at least one randomised trial. |
| B     | Based on well-conducted clinical studies, but without randomised clinical trials.  |
| C     | Made despite the absence of directly applicable clinical studies of good quality.  |

\* Modified from Oxford Centre for Evidence-based Medicine (1).

### 1.1.2 Publication history

The Urological Trauma Guidelines were first published in 2003; partial or full updates were available in 2006 and 2009. In 2012, the panel published comprehensive guidelines for the evaluation and treatment of iatrogenic urologic trauma (iatrogenic trauma Euro Urology paper). The entire Urological Trauma Guidelines have now been updated, with the exception of the "Mass casualty events, triage, and damage control" which has not been revised in this current version of the trauma guidelines. This will be extensively reworked for the next edition of the Guidelines. Paediatric trauma is addressed in the paediatric urology guidelines, and not in this urological trauma document.

A quick reference document presenting the main findings of the Trauma guidelines is also available alongside several scientific publications in the EAU scientific journal European Urology (2,3).

All texts can be viewed and downloaded for personal use at the EAU website:  
<http://www.uroweb.org/guidelines/online-guidelines/>.

This document was peer-reviewed prior to publication.

### 1.1.3 Potential conflict of interest statement

The expert panel have submitted potential conflict of interest statements which can be viewed on the EAU website: <http://www.uroweb.org/guidelines/online-guidelines/>.

## 1.2 Definition and Epidemiology

Trauma is defined as a physical injury or a wound to living tissue caused by an extrinsic agent. Trauma is the sixth leading cause of death worldwide, accounting for 10% of all mortalities. It accounts for approximately 5 million deaths each year worldwide and causes disability to millions more (4,5).

About half of all deaths due to trauma are in people aged 15–45 years and in this age it is the leading cause of death. Death from injury is twice as common in males as females, especially from motor vehicle accidents (MVA) and interpersonal violence. Trauma is therefore a serious public health problem with significant social and economic costs.

Significant differences exist in the causes and the effects of traumatic injuries between geographical areas, and between low, middle, and high-income countries. It should be noted that alcohol and drug abuse increase the rate of traumatic injuries by precipitating interpersonal violence, child and sexual abuse, and motor vehicle accidents.

### 1.2.1 Genito-Urinary Trauma

Genito-urinary trauma is seen in both sexes and in all age groups, but is more common in males.

The kidney is the most commonly injured organ in the genito-urinary system and renal trauma is seen in up to 5% of all trauma cases (6,7), and in 10% of all abdominal trauma cases (8). In MVAs, renal trauma is seen after direct impact into the seatbelt or steering wheel (frontal crashes) or from body panel intrusion in side-impact crashes (9).

Ureteral trauma is relatively rare but due mainly to iatrogenic injuries, and in penetrating gunshot wounds – both in military and civilian settings (10).

Traumatic bladder injuries are usually due to blunt (MVA) causes and associated with pelvic fracture (11), although may also be a result of iatrogenic trauma.

The anterior urethra is most commonly injured by blunt or “fall-astride” trauma, whereas the posterior urethra is usually injured in pelvic fracture cases – the majority of which are seen in MVAs (12).

Genital trauma is much more common in males due to anatomical considerations and more frequent participation in physical sports, violence and war-fighting. Of all genitor-urinary injuries, 1/3-2/3rds involve the external genitalia (13).

### 1.2.2 Classification of trauma

Traumatic injuries are classified by the world health organization (WHO) into intentional (either interpersonal violence related, war-related or self-inflicted injury), and unintentional injury - mainly motor vehicle collisions, falls, and other domestic accidents. Intentional trauma accounts for approximately half of the trauma-related deaths worldwide (5). A specific type of unintentional injury consists of iatrogenic injury which is created during treatment or diagnostic procedures by healthcare personnel.

Traumatic injuries are classified according to the basic mechanism into penetrating when an object pierces the skin, and blunt.

Penetrating trauma is further classified according to the velocity of the projectile:

1. High-velocity projectiles (e.g. rifle bullets – 800-1000m/sec)
2. Medium-velocity (e.g. handgun bullets – 200-300 m/sec)
3. Low-velocity items (e.g. knife stab)

High-velocity weapons inflict greater damage because the bullets transmit large amounts of energy to the tissues. They form temporary expansive cavitation that immediately collapses and creates shear forces and destruction in a much larger area than the projectile tract itself. Cavity formation disrupts tissue, ruptures blood vessels and nerves, and may fracture bones away from the missile path. In lower velocity injuries, the damage is usually confined to the track of the projectile.

Blast injury is a complex cause of trauma because it commonly includes both blunt and penetrating trauma, and may also be accompanied by a burn injury.

Several classifications are used to describe the severity and the features of a traumatic injury. The most common is the AAST (American Association for the Surgery of Trauma) injury scoring scale, which is widely used in renal trauma (see the relevant section) (14). For the other urological organs, general practice is that injuries are described by their anatomical site and severity (partial/complete), therefore the elaborated AAST tables were omitted from these guidelines.

### 1.2.3 Initial evaluation and treatment

The initial emergency assessment of the trauma patient is beyond the focus of these guidelines, and is usually carried out by emergency medicine and trauma specialised personnel. The first priority is stabilisation of the patient and treatment of associated life-threatening injuries. The initial treatment should include securing the airway, controlling external bleeding and resuscitation of shock. In many cases, physical examination is carried out during the stabilisation of the patient.

A direct history is obtained from conscious patients. Witnesses and emergency personnel can provide valuable information about unconscious or seriously injured patients. In penetrating injuries, important information includes the size of the weapon in stabbings, and the type and calibre of the weapon used in gunshot wounds. The medical history should be as detailed as possible, as pre-existing organ dysfunction can have a negative effect on trauma patient outcome (15,16).

It is essential that all persons treating trauma patients are aware of the risk of hepatitis B and C infection. An infection rate of 38% was reported among males with penetrating wounds to the external genitalia (17). In any penetrating trauma, tetanus vaccination should be considered according to the patient's vaccination history and the features of the wound itself (CDC tetanus wound management) (18).

### 1.3 References

1. Oxford Centre for Evidence-based Medicine Levels of Evidence (May 2001). Produced by Bob Phillips, Chris Ball, Dave Sackett, Doug Badenoch, Sharon Straus, Brian Haynes, Martin Dawes. <http://www.cebm.net/index.aspx?o=1025> [accessed December 2012].
2. Summerton DJ, Kitrey ND, Lumen N, et al. EAU guidelines on iatrogenic trauma. *Eur Urol* 2012 Oct;62(4):628-39. <http://www.ncbi.nlm.nih.gov/pubmed/22717550>
3. Martínez-Piñero L, Djakovic N, Plas E, et al; European Association of Urology EAU Guidelines on Urethral Trauma. *Eur Urol*. 2010 May;57(5):791-803 <http://www.ncbi.nlm.nih.gov/pubmed/20122789>
4. Søreide K. Epidemiology of major trauma. *Br J Surg* 2009 Jul;96(7):697-8. <http://www.ncbi.nlm.nih.gov/pubmed/19526611>
5. Middleton P. The trauma epidemic. In Jason Smith, Ian Greaves, Keith (2010). Major trauma (1. publ. ed.). Oxford: Oxford University Press. p. 2. ISBN 978-0-19-954332-8.
6. Baverstock, R, Simons, R, McLoughlin, M. Severe blunt renal trauma: a 7-year retrospective review from a provincial trauma centre. *Can J Urol* 2001 Oct;8(5):1372-6. <http://www.ncbi.nlm.nih.gov/pubmed/11718633>
7. Meng MV, Brandes SB, McAninch JW. Renal trauma: indications and techniques for surgical exploration. *World J Urol* 1999 Apr;17(2):71-7. <http://www.ncbi.nlm.nih.gov/pubmed/10367364>
8. Bruce LM, Croce MA, Santaniello JM, et al. Blunt renal artery injury: incidence, diagnosis, and management. *Am Surg* 2001 Jun;67(6):550-4; discussion 555-6. <http://www.ncbi.nlm.nih.gov/pubmed/11409803>
9. Kuan JK, Kaufman R, Wright JL, et al. Renal injury mechanisms of motor vehicle collisions: analysis of the crash injury research and engineering network data set. *J Urol* 2007 Sep;178(3Pt1):935-40; discussion 940. <http://www.ncbi.nlm.nih.gov/pubmed/17632156>
10. Pereira BM, Ogilvie MP, Gomez-Rodriguez JC, et al. A review of ureteral injuries after external trauma. *Scand J Trauma Resusc Emerg Med* 2010 Feb 3;18:6. <http://www.ncbi.nlm.nih.gov/pubmed/20128905>
11. Bjurlin MA, Fantus RJ, Mellett MM, et al. Genitourinary injuries in pelvic fracture morbidity and mortality using the National Trauma Data Bank. *J Trauma* 2009 Nov;67(5):1033-9. <http://www.ncbi.nlm.nih.gov/pubmed/19901665>
12. Dixon CM. Diagnosis and acute management of posterior urethral disruptions, In: McAninch JW (ed). Traumatic and reconstructive urology. Philadelphia: WB Saunders, 1996, pp. 347-355.
13. Brandes SB, Buckman RF, Chelsky MJ, et al. External genitalia gunshot wounds: a ten-year experience with fifty-six cases. *J Trauma* 1995 Aug;39(2):266-71. <http://www.ncbi.nlm.nih.gov/pubmed/7674395>
14. Moore EE, Shackford SR, Pachter HL, et al. Organ injury scaling: spleen, liver, and kidney. *J Trauma* 1989 Dec;29(12):1664-6. <http://www.ncbi.nlm.nih.gov/pubmed/2593197>



15. Wutzler S, Maegele M, Marzi I, et al. Association of preexisting medical conditions with in-hospital mortality in multiple-trauma patients. *J Am Coll Surg* 2009 Jul;209(1):75-81.  
<http://www.ncbi.nlm.nih.gov/pubmed/19651066>
16. Shoko T, Shiraishi A, Kaji M, et al. Effect of pre-existing medical conditions on in-hospital mortality: analysis of 20,257 trauma patients in Japan. *J Am Coll Surg* 2010 Sep;211(3):338-46.  
<http://www.ncbi.nlm.nih.gov/pubmed/20800190>
17. Cline KJ, Mata JA, Venable DD, et al. Penetrating trauma to the male external genitalia. *J Trauma* 1998 Mar;44(3):492-4.  
<http://www.ncbi.nlm.nih.gov/pubmed/9529176>
18. CDC. Tetanus wound management. Available at:  
<http://www.cdc.gov/vaccines/pubs/pinkbook/downloads/tetanus.pdf>

## 2. RENAL TRAUMA

### 2.1 Introduction

The incidence of urological tract injury following abdominal trauma is approximately 10%. Renal trauma occurs in approximately 1-5% of all trauma cases (1,2). The kidney is the most commonly injured genitourinary organ in all ages, with the male to female ratio being 3:1 (3-5). Although renal trauma can be acutely life-threatening, most injuries can be managed conservatively (6). During the past 20 years, advances in imaging and treatment strategies have decreased the need for surgical intervention and increased renal preservation (7-9).

### 2.2 Mode of injury

Renal injuries are classified by their mechanism as blunt or penetrating. In rural settings, blunt trauma can account for the largest percentage (90-95%), while in urban settings, the percentage of penetrating injuries can increase to 20% or higher (10,11)

#### 2.2.1 *Blunt renal injuries*

Blunt mechanisms, include motor vehicle collision, falls, vehicle-associated pedestrian accidents, sports and assault. Traffic accidents are the major cause of almost half the blunt injuries (12). Renal injury in frontal and side-impact collisions appears to occur after direct impact from objects in the vehicle compartment. For frontal crashes, the acceleration of the occupant(s) into the seat belt or steering wheel seems to result in renal injuries. Side-impact injuries occur when the vehicle side panel intrudes into the compartment, striking the occupant (13). Passengers in automobiles with frontal and side airbags were associated with a 45.3% and 52.8% reduction in renal injury, respectively, compared with those without airbags (14). A 20-year review of renal injuries following free falls found a rate of 16% (15). A direct blow to the flank or abdomen during sports activities is another cause of blunt trauma injury. Sudden deceleration or a crash injury may result in contusion, laceration or avulsion of the renal parenchyma.

Renal vascular injuries in general occur in less than 5% of blunt abdominal trauma patients. The incidence of blunt renal artery injury is even less, with estimated incidences ranging between 0.05% and 0.08% among blunt trauma patients (16). Renal artery occlusion is associated with rapid deceleration injuries. In theory, the kidney is displaced causing renal artery traction; the resulting tear in the inelastic intima and subsequent haemorrhage into the vessel wall leads to thrombosis. Compression of the renal artery between the anterior abdominal wall and the vertebral bodies may result in thrombosis of the renal artery.

#### 2.2.2 *Penetrating renal injuries*

Gunshot and stab wounds represent the most common causes of penetrating injuries. Renal injuries from penetrating trauma tend to be more severe and less predictable than those from blunt trauma. Bullets, because of their higher kinetic energy, have the potential for greater parenchymal destruction and are most often associated with multiple-organ injuries (17). Penetrating injury produces direct tissue disruption of the renal parenchyma, vascular pedicles, or collecting system.

In wartime, the kidney is the most commonly injured urogenital organ. Most are associated with major abdominal injuries, and the rate of nephrectomies is high (25-65%) (18-20).

### 2.2.3 Injury classification

Twenty six classifications for renal injuries have been presented in the literature in the past 60 years (21), but the committee on organ injury scaling of the AAST has developed a renal-injury scaling system that is now widely used (22). Renal injuries are classified as grade 1 to 5 (Table 3). Abdominal computed tomography (CT) or direct renal exploration is used to classify injuries. All recent publications have adopted this classification. The AAST scaling system is the most important variable predicting the need for kidney repair or removal (23,24) and it also predicts for morbidity after blunt or penetrating injury and for mortality after blunt injury (25).

**Table 3: AAST renal injury grading scale (22)**

| Grade* | Description of injury  |
|--------|--|
| 1      | Contusion or non-expanding subcapsular haematoma   |
|        | No laceration  |
| 2      | Non-expanding peri-renal haematoma   |
|        | Cortical laceration < 1 cm deep without extravasation  |
| 3      | Cortical laceration > 1 cm without urinary extravasation   |
| 4      | Laceration: through corticomedullary junction into collecting system   |
|        | Or   |
|        | Vascular: segmental renal artery or vein injury with contained haematoma, or partial vessel laceration, or vessel thrombosis |
| 5      | Laceration: shattered kidney   |
|        | Or   |
|        | Vascular: renal pedicle or avulsion  |

\*Advance one grade for bilateral injuries up to grade III.

Proposals for changes include a substratification of the intermediate grade renal injury into grade 4a (low risk-cases likely to be managed non-operatively) and grade 4b (high risk-cases likely to benefit from angiographic embolisation, renal repair or nephrectomy), based on the presence or absence of a series of important radiographic risk factors, including peri-renal haematoma, intravascular contrast extravasation and renal laceration complexity (26), and a suggestion that grade 4 injuries comprise all collecting system injuries, including ureteropelvic junction (UPJ) injury of any severity and segmental arterial and venous injuries. According to the last proposal, grade 5 injuries should include only renal hilar injuries, including thrombotic events (27).

## 2.3 Diagnosis

When renal injury is suspected during clinical examination, further evaluation (CT scan, laparotomy) is required for a prompt diagnosis.

### 2.3.1 History and physical examination

Possible indicators of major renal injury include a rapid deceleration event (fall, high-speed MVAs) or a direct blow to the flank. In assessing trauma patients after MVAs, the history should include the vehicle's speed and whether the patient was a passenger or pedestrian.

In the early resuscitation phase, special consideration should be given to pre-existing renal disease (28). Patients with solitary kidney present a special group and in case of renal injury, the whole functioning renal mass might be endangered (29).

Pre-existing renal abnormality makes renal injury more likely following trauma. Pre-existing renal pathology should be noted. Hydronephrosis due to UPJ abnormality, renal calculi, cysts and tumours are the most commonly reported entities that may complicate a minor renal injury (30). The overall percentage of these cases varies from 4% to 22% (31,32).

Haemodynamic stability is the primary criterion for the management of all renal injuries. Vital signs should be recorded throughout diagnostic evaluation. Physical examination may reveal an obvious penetrating trauma from a stab wound to the lower thoracic back, flanks and upper abdomen, or bullet entry or exit wounds in this area. In stab wounds, the extent of the entrance wound may not accurately reflect the depth of penetration.

Blunt trauma to the back, flank, lower thorax or upper abdomen may result in renal injury. The following

findings on physical examination raise the suspicion of renal involvement:

- haematuria;
- flank pain;
- flank ecchymoses;
- flank abrasions;
- fractured ribs;
- abdominal distension;
- abdominal mass;
- abdominal tenderness.

### 2.3.1.1 Recommendations

|  | GR |
|--|----|
| Haemodynamic stability should be assessed upon admission:  |    |
| - History should be taken from conscious patients, witnesses and rescue team personnel with regard to the time and setting of the incident.  | A  |
| - Past renal surgery, and known pre-existing renal abnormalities (ureteropelvic junction obstruction, large cysts, lithiasis) should be recorded.  | A  |
| A thorough examination should be made of the thorax, abdomen, flanks and back for penetrating wounds. Findings on physical examination such as haematuria, flank pain, flank abrasions and bruising ecchymoses, fractured ribs, abdominal tenderness, distension or mass, could indicate possible renal involvement. | B  |

GR = grade of recommendation.

### 2.3.2 Laboratory evaluation

Urinalysis, haematocrit and baseline creatinine are the most important tests for evaluating renal trauma.

Haematuria, either microscopic or gross is often seen in renal injury, but is neither sensitive nor specific enough for differentiating minor and major injuries. It does not necessarily correlate with the degree of injury (33).

Major renal injury, such as disruption of the ureteropelvic junction, renal pedicle injuries or segmental arterial thrombosis may occur without haematuria (34). In a study by Eastham et al., 9% of patients with stab wounds and resultant proven renal injury did not manifest haematuria (35).

Haematuria that is out of proportion to the history of trauma may suggest pre-existing renal pathology (36).

A urine dipstick is an acceptably reliable and rapid test to evaluate haematuria. However, some studies have shown false-negative result rates ranging from 3-10% using the dipstick test for haematuria (37).

Serial haematocrit determination in combination with vital signs are used for continuous evaluation of the trauma patient. The decrease in haematocrit and the requirement for blood transfusions is an indirect sign of the rate of blood loss and, along with the patient's response to resuscitation, is valuable in the decision-making process. However, until evaluation is complete, it will not be clear whether it is due to renal trauma and/or associated injuries.

As most trauma patients are evaluated within 1 hour of injury, creatinine measurement reflects renal function prior to the injury. An increased creatinine level usually reflects pre-existing renal pathology.

### 2.3.2.1 Recommendations

|   | GR |
|---|----|
| Urine from a patient with suspected renal injury should be inspected for haematuria (visually or by dipstick analysis). | B  |
| A decrease in serial haematocrit measurement indicates blood loss.  | B  |
| Creatinine levels should be measured to identify patients with impaired renal function prior to injury.                 | C  |

GR = grade of recommendation

### 2.3.3 Imaging: criteria for radiographic assessment

Decisions about radiographic imaging in cases of suspected renal trauma are based on the clinical findings and the mechanism of injury. Since the majority of renal injuries are not significant and resolve without any intervention, many attempts have been made to identify which patients could be spared the discomfort, radiation exposure, possible allergic reaction, time and expense of a radiographic evaluation (38).

Some patients do not require radiographic evaluation following blunt renal trauma. Patients with microscopic

haematuria and no shock after blunt trauma have a low likelihood of concealing significant renal injury. The indications for radiographic evaluation are gross haematuria, microscopic haematuria and shock, or the presence of major associated injuries. However, patients with a history of rapid deceleration injury with clinical indicators of renal trauma or associated injuries also need immediate imaging to rule out ureteral avulsion or renal pedicle injury (39).

Patients with penetrating trauma to the torso have a high incidence of significant renal injuries. If renal injury is clinically suspected on the basis of an entry or exit wound, renal imaging should be performed, regardless of the degree of haematuria (40).

#### 2.3.3.1 *Ultrasonography*

Ultrasonography provides a quick, non-invasive, low-cost means of detecting peritoneal fluid collections without exposure to radiation (41). Focused assessment with sonography for Trauma (FAST) rapidly assesses for haemoperitoneum and haemopericardium. The major disadvantage of using FAST is that the results are highly dependent on the operator and the patient.

Ultrasound scans can detect renal lacerations but cannot accurately assess their depth and extent. They do not provide functional information about renal excretion or urine leakage. Ultrasound is useful for the routine follow-up of parenchymal lesions or haematomas in the intensive care unit and for serially evaluating stable injuries for the resolution of urinomas and retroperitoneal haematomas (33).

Since ultrasound scans are used in the triage of patients with blunt abdominal trauma in many centres, they can be helpful in identifying which patients require a more aggressive radiological exploration to obtain a certain diagnosis, as well as following up injuries and hematomas (42).

Contrast-enhanced sonography is described as more sensitive than conventional ultrasound in the detection of renal injuries but it is not commonly used. In haemodynamically stable patients, it is a useful tool in the assessment of blunt injuries (43).

#### 2.3.3.2 *Intravenous pyelography*

Although intravenous pyelography (IVP) is a sensitive modality for renal trauma, it is not the study of choice and has largely been replaced by CT scanning (44). Use of IVP is recommended only in centres where it is the only modality available (45). Intravenous pyelography can be used to establish the presence or absence of one or both of the kidneys, clearly define the parenchyma and outline the collecting system. The most significant findings from IVP are non-function and extravasation. Non-function is usually a sign of extensive trauma to the kidney, pedicle injury (vascular avulsion or thrombosis), or a severely shattered kidney. Extravasation of the contrast medium also implies a severe degree of trauma, involving the capsule, parenchyma and collecting system. Other less reliable signs are delayed excretion, incomplete filling, caliceal distortion and obscuring of the renal shadow. Non-visualisation, contour deformity or contrast extravasation should prompt further radiological evaluation. The sensitivity of IVP is high (> 92%) for all degrees of trauma severity.

#### 2.3.3.3 *One-shot intraoperative IVP*

In unstable patients with signs or symptoms of renal injury selected for immediate operative intervention, one-shot IVP provides important information for decision making in the critical time of urgent laparotomy concerning the injured kidney, as well as the presence of a normal functioning kidney on the contralateral side (46).

The technique consists of a bolus intravenous injection of 2 mL/kg of radiographic contrast followed by a single plain film taken after 10 minutes. The study is safe, efficient, and of high quality in most cases. It provides important information for decision-making, although in cases of penetrating abdominal trauma 80% of patients with normal oneshot IVP findings had renal injuries not detected by the IVP (47).

#### 2.3.3.4 *Computed tomography (CT)*

Computed tomography is the gold standard method for the radiographic assessment of stable patients with renal trauma. Computed tomography is more sensitive and specific than IVP, ultrasonography or angiography, and more accurately defines the location of injuries, easily detects contusions and devitalised segments, visualises the entire retroperitoneum and any associated haematomas, and simultaneously provides a view of both the abdomen and pelvis. It demonstrates superior anatomical detail, including the depth and location of renal laceration and presence of associated abdominal injuries, and establishes the presence and location of the contralateral kidney (48).

CT is particularly useful in evaluating traumatic injuries to kidneys with pre-existing abnormalities (49).

Intravenous contrast should be administered for renal evaluation. A lack of contrast enhancement of the injured kidney is a hallmark of renal pedicle injury. In cases where this typical finding is not demonstrated, central parahilar haematoma increases the possibility of renal pedicle injury. This sign should be considered even if the renal parenchyma is well enhanced (50). Renal vein injury remains difficult to diagnose with any type of radiographic study. However, the presence on CT of a large haematoma, medial to the kidney and displacing the renal vasculature, should raise the suspicion of venous injury.

Spiral CT provides shorter scanning time and thus fewer artefacts in the examinations of patients who cannot co-operate adequately (51). Three-dimensional post-processing modalities allow assessment of the renal vascular pedicle by CT angiography and improve the demonstration of complex lacerations of the renal parenchyma (52). However, injury to the renal collecting system may be missed during routine spiral CT. In all cases of suspected renal trauma evaluated with spiral CT, repeat scans of the kidneys should be performed 10-15 minutes after contrast injection (53). Most blunt ureteral and ureteropelvic junction injuries can be identified if delayed excretory CT scans are performed (54).

Computed tomography scanning is also safe as part of the diagnostic procedure for patients with gunshot wounds who are being considered for non-operative management (55). Missed renal injuries are common but minor and do not alter the patients' clinical course (56).

#### 2.3.3.5 Magnetic resonance imaging (MRI)

Although MRI is not used in the majority of renal trauma patients, it is a sensitive study in the evaluation of blunt renal trauma (57). Magnetic resonance imaging is not the first choice in managing patients with trauma because it requires a longer imaging time and limits access to patients when they are in the magnet during the examination. Magnetic resonance imaging is therefore useful in renal trauma only if CT is not available, in patients with iodine allergy, or in the very few cases where the findings on CT are equivocal (58).

#### 2.3.3.6 Angiography

Angiography is indicated mainly for stable patients who are candidates for radiological control of haemorrhage defined on CT (35). Angiography is less specific, more time-consuming and more invasive than CT but is more specific for defining the exact location and degree of vascular injuries. It is indicated in the management of persistent or delayed management of haemorrhage from branching renal vessels (49).

Angiography can define renal lacerations, extravasation and pedicle injury. Additionally, it is the test of choice for evaluating renal venous injuries. Another indication for the use of angiography is nonenhancement of the renal cortex on CT scan caused by total avulsion of the renal vessels, renal artery thrombosis and severe contusion causing major vascular spasm.

#### 2.3.3.7 Radionuclide scans

Radionuclide scans are generally used or required only in trauma patients with allergy to iodinated contrast material (49).

#### 2.3.3.8 Recommendations

|   | GR |
|---|----|
| Blunt trauma patients with macroscopic haematuria or microscopic haematuria and haemodynamic instability should undergo radiographic evaluation.  | B  |
| Radiographic evaluation is recommended for all patients with a history of rapid deceleration injury and/or significant associated injuries.   | B  |
| All patients with or without haematuria after penetrating abdominal or thoracic injury require urgent renal imaging.  | B  |
| Ultrasonography alone should not be used to set the diagnosis of renal injury since it cannot provide sufficient information. However, it can be informative during the primary evaluation of polytrauma patients and for the follow-up of recuperating patients. | C  |
| A CT scan with enhancement of intravenous contrast material and delayed images is the gold standard for the diagnosis and staging of renal injuries in haemodynamically stable patients.  | A  |
| In the absence of or contraindication for CT, IVP, MRI and radiographic scintigraphy are reasonable alternatives for imaging renal trauma.  | C  |
| One-shot IVP should be considered in unstable patients who require emergency surgical exploration.  | C  |
| Angiography is a safe and reliable diagnostic examination.  | B  |

GR = grade of recommendation; CT = computed tomography; IVP = intravenous pyelography; MRI = magnetic resonance imaging.

## **2.4 Treatment**

### **2.4.1 Indications for renal exploration**

The need for renal exploration can be predicted considering the type of injury, transfusion requirements, blood urea nitrogen (BUN), creatinine and injury grade (59). However, the management of renal injury may be influenced by the decision to explore or observe associated abdominal injuries (60).

A life-threatening haemodynamic instability due to renal haemorrhage is an absolute indication for renal exploration, irrespective of the mode of injury (61,62). Other indications include an expanding or pulsatile peri-renal haematoma identified at exploratory laparotomy performed for associated injuries.

Persistent extravasation or urinoma are usually managed successfully with endourological techniques. Inconclusive renal imaging and a pre-existing renal abnormality or an incidentally diagnosed tumour could require surgery even after relatively minor renal injury (36).

Grade 5 vascular renal injuries are regarded as an absolute indication for exploration. An increasing number of reports suggest that parenchymal grade 5 patients who are haemodynamically stable at presentation might be safely treated conservatively (63-66). In these patients, intervention is predicted by the need for continued fluid and blood resuscitation. Other factors that increase the risk of surgical intervention are peri-renal haematoma size > 3.5 cm, presence of intravascular contrast extravasation and presence of grade 4-5 injuries (26). Injury Severity Score (ISS) 16 and grade 4 renal injury are predictive factors for an operation, while higher injury severity (ISS > 16) and lower consciousness level (GCS < 8) are significantly associated with mortality in patients with renal injuries (67).

### **2.4.2 Interventional radiology**

Interventional radiology provided the most important advance in renal trauma management in the last decade. Decisions regarding major renal lacerations must balance the increased incidence of nephrectomy in patients undergoing immediate versus delayed surgical exploration, with the increased morbidity of patients who are managed expectantly. Endovascular treatment is an important and less invasive option for managing renovascular trauma that may allow for maximum tissue/organ preservation.

Angiography with selective renal embolisation is a reasonable alternative to laparotomy provided that no other indication for immediate open surgery exists. Haemodynamically stable patients with grade 3 injuries or higher should be considered for formal angiography followed by embolisation if active bleeding is noticed (68). Positive radiological findings, such as massive extravasation, presence of a large devascularised segment or identification of grade 4 or 5 lesions, arterial laceration, avulsion, global or segmental hypoperfusion of kidney, intimal tear or false aneurysm, segmental or subsegmental arterial bleeding and thrombosis indicate the need for angiography.

Peri-renal haematoma size compressing the kidney and impairing perfusion (peri-nephric compartment syndrome or 'page kidney') and intravascular contrast extravasation are also readily detectible radiographic features, associated with the need for angiographic embolisation (69).

Some polytrauma patients will undergo laparotomy and open repair of intra-peritoneal organ injuries but then undergo angio-embolisation of renal injuries identified on CT or suspected by an expanding retroperitoneal haematoma at the time of surgery. Angio-embolisation also has a role in patients with persistent post-traumatic haematuria. Since the success rate is equally high for initial and repeat interventions, re-intervention is justified when the clinical course allows (70).

The most common injury to the main renal artery is dissection, usually with partial or complete occlusion. Complete arterial avulsion is less common. The management of renal artery occlusion remains controversial. Arterial bleeding may spontaneously cease when tamponade develops within Gerota's fascia. However, when the fascia has been violated, tamponade will not occur and the haematoma will extend to the pararenal space. Without transcatheter embolisation, attempts to stabilise such patients are unlikely to be successful so that the only option is emergency laparotomy (71).

The reported clinical success rate of renal embolisation for trauma is 65% (72) but angiography has a success rate of 94.45% for blunt injuries in stable patients (73). Cure of haematuria after superselective transarterial embolisation is reported as high as 98%, which is similar for both blunt and penetrating injuries (74). The complication rate is minimal and although it has been proven effective for grade 4 injuries initially selected for conservative therapy, it failed when applied to grade 5 injuries (72).

Renal pedicle injuries are normally managed surgically, but there are increasing reports of endovascular treatment options for traumatic arterial dissections and ruptures. In specific clinical circumstances, such as severe polytrauma or a patient with high operative risk, the main renal artery may be embolised, either

as a definitive treatment or to be followed by interval nephrectomy after the patient's clinical condition has improved. The angiographic findings in more peripheral renal artery injuries include contrast extravasation, pseudoaneurysm, arterial transection, arterial wall irregularity, arteriovenous fistulae (AVF) and arterio-caliceal fistula.

Angio-embolisation for grade 4-5 injuries should be done with caution since the initial success rate is low and usually requires additional procedures. However, the procedure itself is safe and not associated with intermediate-term adverse events (73,75). Such patients, who have no other indications for immediate abdominal surgery, benefit from arteriography and possible embolisation. The additional contrast agent needed for arteriography does not increase the incidence of nephropathy (76).

### **2.4.3 Operative findings and reconstruction**

The overall exploration rate for blunt trauma is less than 10% (61), and may be even lower as more centres adopt a conservative approach to the management of these patients (77). The goal of renal exploration following renal trauma is control of haemorrhage and renal salvage. Most large series suggest the transperitoneal approach for surgery (78,79). Access to the renal vascular pedicle is then obtained through the posterior parietal peritoneum, which is incised over the aorta, just medial to the inferior mesenteric vein. Temporary vascular occlusion before opening Gerota's fascia is a safe and effective method during exploration and renal reconstruction (80). It tends to lower blood loss and the nephrectomy rate appears not to increase postoperative azotaemia or mortality (81). Stable perirenal hematomas detected during exploration for associated injuries should not be opened.

Renal reconstruction is feasible in most cases. The overall rate of patients who have a nephrectomy during exploration is around 13%, usually in patients with penetrating injury and higher rates of transfusion requirements, haemodynamic instability, and higher injury severity scores (82).

Other intra-abdominal injuries also slightly increase the need for nephrectomy (83). Mortality is associated with the overall severity of the injury and is not often a consequence of the renal injury itself (84).

In gunshot injuries caused by a high-velocity bullet, reconstruction can be difficult and nephrectomy is often required (85). Renorrhaphy is the most common reconstructive technique. Partial nephrectomy is required when non-viable tissue is detected. Watertight closure of the collecting system, if open, might be desirable, although some experts merely close the parenchyma over the injured collecting system with good results. If the renal capsule is not preserved, an omental pedicle flap or perirenal fat bolster may be used for coverage (86). The use of haemostatic agents and sealants in traumatic renal reconstruction can be helpful (87). In all cases, drainage of the ipsilateral retroperitoneum is recommended to provide an outlet for any temporary leakage of urine.

Renovascular injuries are associated with extensive associated trauma and increased peri- and postoperative mortality and morbidity. Blunt renal artery injury is rare. Non-operative management should be considered as an acceptable therapeutic option (10). Following blunt trauma, repair of grade 5 vascular injury is seldom, if ever, effective (88). Repair might be attempted in patients with a solitary kidney or bilateral injuries (89). Revascularisation is no longer used in the presence of a functioning contralateral kidney (8,12). Nephrectomy for main renal artery injury has outcomes similar to those of vascular repair. It does not worsen post-treatment renal function in the short term.

### **2.4.4 Non-operative management of renal injuries**

#### **2.4.4.1 Blunt renal injuries**

As the indications for renal exploration become clearer, non-operative management has become the treatment of choice for most renal injuries. In stable patients, this means supportive care with bed-rest and observation, though some authors also advocate the use of prophylactic antibiotics (8). Primary conservative management is associated with a lower rate of nephrectomy, without any increase in the immediate or long-term morbidity (90).

Hospitalisation or prolonged observation for evaluation of possible renal injury after a normal abdominal CT scan, when combined with clinical judgment, is unnecessary in most cases (91). All grade 1 and 2 renal injuries can be managed non-operatively, whether due to blunt or penetrating trauma. The treatment of grade 3 injuries has been controversial, but recent studies support expectant treatment (92-94). Patients diagnosed with urinary extravasation in solitary injuries can be managed without major intervention and a resolution rate of > 90% [98]. Persistent bleeding is the main indication for a reconstruction attempt (96).

Most patients with grade 4 and 5 renal injuries present with major associated injuries, and consequently

experience high exploration and nephrectomy rates (97), although emerging data indicate that many of these patients can be managed safely with an expectant approach (98). An initially conservative approach is feasible in stable patients with devitalised fragments (99), although these injuries are associated with an increased rate of complications and late surgery (100).

Non-operative management for segmental renal artery injury results in excellent outcomes (101). Unilateral main renal arterial injuries will normally be managed non-operatively in a haemodynamically stable patient with surgical repair reserved for bilateral renal artery injuries or injuries involving a solitary functional kidney. Conservative management is advised in the treatment of unilateral complete blunt renal artery thrombosis. These patients need close follow-up for the risk of hypertension. Blunt renal artery thrombosis in multiple trauma patients indicates severe injury. Surgeons should critically assess the added risk of mortality against chances of recovering the renal function (102).

#### 2.4.4.2 Penetrating renal injuries

Although almost all grade 4 patients with penetrating injury require renal exploration, only 20% of those with blunt trauma do (103). Isolated grade 4 renal injuries represent a unique situation to treat the patient based solely on the extent of the renal injury. Non-operative management is used more often.

Persistent bleeding represents the main indication for renal exploration and reconstruction. In all cases of severe renal injury, non-operative management should occur only after complete renal staging in haemodynamically stable patients (96).

Penetrating wounds have traditionally been approached surgically. However, stable patients should undergo complete staging to define the full extent of the injury. Renal gunshot injuries should be explored only if they involve the hilum or are accompanied by signs of continued bleeding, ureteral injuries, or renal pelvis lacerations (104).

Low-velocity gunshot and stab wounds of minor degree may be managed conservatively with an acceptably good outcome (105). In contrast, tissue damage from high-velocity gunshot injuries can be more extensive and nephrectomy may be required. Non-operative management of penetrating renal injuries in selected stable patients is associated with a high rate of successful management in approximately 50% of patients with stab wounds and up to approximately 40% of patients with gunshot wounds (106-108).

If the site of penetration by stab wound is posterior to the anterior axillary line, 88% of such renal injuries can be managed non-operatively (109). Injuries to the flank are more likely to be grade 3, while injuries to the abdomen are more likely to be grade 1. A systematic approach based on clinical, laboratory and radiological evaluation might minimise negative exploration without increasing morbidity from a missed injury (62). Renal stab wounds producing major renal injuries (grade 3 or higher) are more unpredictable and are associated with a higher rate of delayed complications if treated expectantly (110). In recent years, selective non-operative management of abdominal stab wounds is generally accepted by an increasing proportion of trauma centres (111).

All patients sustaining a gunshot wound that are evaluable, haemodynamically stable and without diffuse abdominal pain or peritonitis are candidates for non-operative management. A positive FAST is not a contra-indication to non-operative management as this may be a result of an isolated solid organ injury. Computed tomography remains critical in delineating the extent of solid organ damage, the absence of hollow viscus injury, and the presence of any acute complications requiring invasive radiological treatment. With this intensive approach, selected liver, spleen and kidney injuries after gunshot wounding can be managed non-operatively with good functional outcomes (106). The excellent outcomes in patients observed following segmental arterial injury support a role for conservative management in this subgroup (101).

#### 2.4.5 Recommendations

|   | GR |
|---|----|
| Following blunt renal trauma, stable patients should be managed conservatively with bed rest and close monitoring of vital signs until gross haematuria resolves.   | B  |
| Following grade 1-3 stab and low-velocity gunshot wounds, stable patients, after complete staging, should be selected for expectant management.<br>Indications for renal exploration include:<br>– haemodynamic instability;<br>– exploration for associated injuries;<br>– expanding or pulsatile peri-renal haematoma identified during laparotomy;<br>– grade 5 vascular injury. | B  |



|   |   |
|---|---|
| Interventional radiology is indicated in patients with active bleeding from renal injury but without other indications for immediate abdominal operation.                 | B |
| Renal reconstruction should be attempted in cases in which the primary goal of controlling haemorrhage is achieved and a sufficient amount of renal parenchyma is viable. | B |

GR = grade of recommendation.

#### 2.4.6 Postoperative care and follow-up

The risk of complications in patients who have been treated conservatively increases with grade. Repeat imaging 2-4 days after trauma minimises the risk of missed complications, especially in grade 3-5 blunt renal injuries (112). However, the usefulness of frequent CT scanning after injury has never been satisfactorily proven and its use should be weighed against the risk of increased radiation exposure. Computed tomography scans should always be performed on patients with fever, unexplained decreasing haematocrit or significant flank pain. Repeat imaging can be safely omitted for patients with grade 1-4 injuries as long as they remain clinically well (113).

Nuclear renal scans are useful for documenting and tracking functional recovery in patients following renal reconstruction (114). Follow-up should involve physical examination, urinalysis, individualised radiological investigation, serial blood pressure measurement and serum determination of renal function (99). A decline in renal function directly correlates with AAST renal injury grade; this is independent of the mechanism of injury (blunt vs. penetrating) and the method of management (nonoperative vs. renal repair) (115,116). Follow-up examinations should continue until healing is documented and laboratory findings have stabilised, although checking for latent renovascular hypertension may need to continue for years (117). The literature is generally inadequate on the subject of the long-term consequences of trauma on renal tissue.

#### 2.4.7 Recommendations

|  | GR |
|--|----|
| Repeat imaging is recommended in cases of suspected complications, cases of fever, flank pain, or falling haematocrit.   | B  |
| Nuclear scintigraphy is useful for documenting functional recovery.  | C  |
| First follow-up should be at approximately 3 months after major renal injury with hospitalization. Each follow up should include:<br>1. Physical examination.<br>2. Urinalysis.<br>3. Individualised radiological investigation.<br>4. Serial blood pressure measurement.<br>5. Serum determination of renal function. | C  |
| Long-term follow-up should be decided on a case-by-case basis.   | C  |

GR = grade of recommendation.

#### 2.4.8 Complications

Early complications, occurring less than 1 month after injury, can be bleeding, infection, perinephric abscess, sepsis, urinary fistulae, hypertension, urinary extravasation and urinoma. Delayed complications include bleeding, hydronephrosis, calculus formation, chronic pyelonephritis, hypertension, arteriovenous fistulae, hydronephrosis and pseudoaneurysms. Delayed retroperitoneal bleeding may be life-threatening and selective angiographic embolisation is the preferred treatment (118). Perinephric abscess formation is usually best managed by percutaneous drainage, although open drainage may sometimes be required. Percutaneous management of complications may pose less risk of renal loss than re-operation, which may lead to nephrectomy when infected tissues make reconstruction difficult (61).

Renal trauma is a rare cause of hypertension, mostly in young men. The frequency of posttraumatic hypertension is estimated to be less than 5% in all published series (119,120). Hypertension may occur acutely as a result of external compression from perirenal haematoma (Page kidney), or chronically because of compressive scar formation. Hypertension is usually renin-dependent and associated with parenchymal injury. Renin-mediated hypertension may occur as a long-term complication; aetiologies include renal artery thrombosis, segmental arterial thrombosis, renal artery stenosis (Goldblatt kidney), devitalised fragments and AVF. Arteriography is informative in cases of post-traumatic hypertension (121). Treatment is required if the hypertension persists and could include medical management, excision of the ischaemic parenchymal segment, vascular reconstruction, or total nephrectomy (121).

Urinary extravasation after renal reconstruction often subsides without intervention as long as ureteral obstruction and infection are not present. Ureteral retrograde stenting may improve drainage and allow healing (122). Persistent urinary extravasation from an otherwise viable kidney after blunt trauma often responds to stent placement and/or percutaneous drainage as necessary (123).

Arteriovenous fistulae usually present with delayed onset of significant haematuria, most often after penetrating trauma. Percutaneous embolisation is often effective for symptomatic AVF, but larger ones may require surgery (124). Post-procedural complications include infection, sepsis, urinary fistulae, and renal infarction (125).

The development of pseudoaneurysm is a rare complication following blunt renal trauma. In numerous case reports, transcatheter embolisation appears to be a reliable minimally invasive solution (126,127).

Acute renal colic from a retained missile has been reported, and can be managed endoscopically if possible (128). Other unusual late complications, such as duodenal obstruction, may result from retroperitoneal haematoma following blunt renal trauma (129).

#### 2.4.9 **Recommendations**

|  | <b>GR</b> |
|--|-----------|
| Complications following renal trauma require a thorough radiographic evaluation.                                     | B         |
| Medical management and minimally invasive techniques should be the first choice for the management of complications. | C         |

*GR = grade of recommendation.*

#### 2.4.10 **Renal injury in the polytrauma patient**

Approximately 8-10% of blunt and penetrating abdominal injuries involve the kidneys. The incidence of associated injury in penetrating renal trauma ranges from 77% to 100%. Gunshot wounds are associated with organ injury more often than are stab wounds. Most patients with penetrating renal trauma have associated adjacent organ injuries that may complicate treatment. In the absence of an expanding haematoma with haemodynamic instability, associated multiorgan injuries do not increase the risk of nephrectomy (11). Blunt and penetrating trauma equally contributed to combined renal and pancreatic injury, as reported by Rosen and McAninch. Renal preservation was achieved in most patients, and the complication rate of the series was 15% (130). A similar rate of complications (16%) was reported in patients with simultaneous colon and renal injury. In a report reviewing this combination of injuries over a period of 17 years, 58% of patients underwent an exploration, with nephrectomies performed in 16% of explorations (131).

Renal injuries seem to be rather rare in patients with blunt chest trauma. In a study of polytrauma patients, conservative management was safely attempted without increasing morbidity (65).

#### 2.4.11 **Recommendations**

|   | <b>GR</b> |
|---|-----------|
| Polytrauma patients with associated renal injuries should be evaluated on the basis of the most threatening injury.                   | C         |
| In cases where surgical intervention is chosen, all associated abdominal injuries should be managed where appropriate simultaneously. | C         |
| The decision for conservative management should consider all injuries independently.  | C         |

*GR = grade of recommendation.*

## 2.5 **Iatrogenic renal injuries**

### 2.5.1 **Introduction**

Iatrogenic renal trauma (IRT) is rare but can lead to significant morbidity.

### 2.5.2 **Incidence and aetiology**

The commonest causes of IRT are listed in Table 4 (132).

**Table 4: Incidence and aetiology of commonest iatrogenic renal trauma during various procedures**

| Procedure                           | Haemorrhage  | AVF | Pseudo-aneurysm | Renal pelvis injury | Aorto-caliceal fistula | Foreign body |
|-------------------------------------|--------------|-----|-----------------|---------------------|------------------------|--------------|
| Nephrostomy                         | +            |     | +               | +                   |                        |              |
| Biopsy                              | + (0.5-1.5%) | +   | + (0.9%)        |                     |                        |              |
| Percutaneous nephrolithotomy (PCNL) | +            | +   |                 | +                   |                        |              |
| Laparoscopic surgery (oncology)     | +            |     |                 |                     |                        |              |
| Open surgery (oncology)             | +            |     | + (0.43%)       |                     |                        | +            |
| Transplantation                     | +            | +   | +               |                     | +                      |              |
| Endopyelotomy                       | +            |     |                 | +                   |                        | +            |
| Endovascular procedure              | + (1.6%)     |     |                 |                     |                        |              |

AVF = arteriovenous fistulae; PCNL = percutaneous nephrolithotomy.

Large haematomas after biopsy (0.5-1.5%) are caused by laceration or arterial damage [136]. Renal artery and intraparenchymal pseudoaneurysms (0.9%) may be caused by percutaneous biopsy, nephrostomy, and partial nephrectomy (0.43%) (133). In percutaneous nephrolithotomy (PCNL), haemorrhage is the most dangerous IRT. Vascular injuries are quite common at any stage of the procedure, especially when punctures are too medial or directly of the renal pelvis.

Other injuries include AVFs or a tear in the pelvicaliceal system, causing extravasation and absorption of irrigation fluid. Iatrogenic renal traumas in renal transplantation are more common and include AVFs, intrarenal pseudoaneurysms, arterial dissection and arterio-caliceal fistulae. Pseudoaneurysm is a rare complication of allograft biopsy. Although the overall complication rate with biopsies in transplant kidneys is 9% (including haematoma, AVF, macroscopic haematuria and infection), vascular complications requiring intervention account for 0.2-2.0% (134). Predisposing factors include hypertension, renal medullary disease, central biopsies, and numerous needle passes (135). Arteriovenous fistulae and pseudoaneurysms can occur in 1-18% of allograft biopsies, and may coexist in up to 30% of cases (136).

Extrarenal pseudoaneurysms after transplantation procedures generally occur at the anastomosis, in association with local or haematogenous infection. Arterial dissection related to transplantation is rare and presents in the early postoperative period (137).

Iatrogenic renal traumas associated with endopyelotomy are classified as major (vascular injury), and minor (urinoma) (138). Patients undergoing cryoablation for small masses via the percutaneous or the laparoscopic approach may have minor IRTs, including asymptomatic perinephric haematoma and self-limited urine leakage.

Vascular injury is a rare complication (1.6%) of endovascular interventions in contrast to patients with surgical injuries. The renal vessels are vulnerable mainly during oncological procedures (139). Renal foreign bodies, with retained sponges or wires during open or endourological procedures, are uncommon.

### 2.5.3 **Diagnosis (clinical signs, imaging)**

Haematuria is common after nephrostomy, but massive retroperitoneal haemorrhage is rare. If a nephrostomy catheter appears to transfix the renal pelvis, significant arterial injury is possible. The misplaced catheter should be withdrawn over a guide wire and embolisation may arrest the haemorrhage rapidly. Computed tomography can also successfully guide repositioning of the catheter into the collecting system (140). Haemorrhage can be prevented by avoiding puncture in patients receiving anticoagulation treatment or with coagulopathy, by careful targeting the calices and by avoiding medial puncture. Injuries to the renal pelvis are less likely to occur if the dilator is not advanced further than the calix, sheaths are handled with care, especially during advancement around the pelviureteric junction, and kinking of the guide wires is avoided (141). After percutaneous biopsy, arteriovenous fistulae may present with severe hypertension. A pseudoaneurysm should be suspected if the patient presents with flank pain and decreasing haematocrit, even in the absence of haematuria.

During PCNL, acute bleeding may be caused by injury to the anterior or posterior segmental arteries, or late postoperative bleeding may be caused by interlobar and lower-pole arterial lesions, AVF and post-traumatic aneurysms (142). Duplex ultrasound and CT angiography can be used to diagnose vascular injuries. A close watch on irrigation fluid input and output is required to ensure early recognition

of extravasation of fluid. Intra-operative evaluation of serum electrolytes, acid-base status, oxygenation, and monitoring of airway pressure are good indicators of this complication, since metabolic acidosis, hyponatraemia, hypokalaemia, peritonitis and ileus may occur.

In arterial dissection related to transplantation, symptoms include anuria and a prolonged dependence on dialysis. Doppler ultrasound can demonstrate compromised arterial flow. Dissection can lead to thrombosis of the renal artery and/or vein.

After angioplasty and stent-graft placement in the renal artery, during which wire or catheters may enter the parenchyma and penetrate through the capsule, possible radiological findings include AVF, pseudoaneurysm, arterial dissection and contrast extravasation. Common symptoms of pseudoaneurysms are flank pain and gross haematuria within 2 or 3 weeks after surgery (143). Transplant AVF and pseudoaneurysms may be asymptomatic or may cause gross haematuria or hypovolemia due to shunting and 'steal' phenomenon, renal insufficiency, hypertension, and high-output cardiac failure. Patients with extrarenal pseudoaneurysms may present with infection/bleeding, swelling, pain and intermittent claudication. Doppler ultrasound findings for AVF include high-velocity, low-resistance, spectral waveforms, with focal areas of disorganised colour flow outside the normal vascular borders, and possibly a dilated vein (144). Pseudoaneurysms appear on ultrasound as anechoic cysts, with intracystic flow on colour Doppler.

Potential complications of retained sponges include abscess formation, fistulisation to the skin or intestinal tract, and sepsis. Retained sponges may cause pseudotumours or appear as solid masses. Magnetic resonance imaging clearly shows the characteristic features (145). Absorbable haemostatic agents may also produce a foreign-body giant cell reaction, but the imaging characteristics are not specific. Retained stents, wires, or fractured Acucise cutting wires may also present as foreign bodies and can serve as a nidus for stone formation (146).

#### 2.5.4 **Management**

Small subcapsular haematomas after nephrostomy resolve spontaneously, while AVFs are best managed by embolisation. Arteriovenous fistulae and pseudoaneurysms after biopsy are also managed by embolisation (147).

During PCNL, bleeding can be venous or arterial. In major venous trauma with haemorrhage, patients with concomitant renal insufficiency can be treated without open exploration or angiographic embolisation using a Council-tip balloon catheter (148). In the case of profuse bleeding at the end of a PCNL, conservative management is usually effective. The patient should be placed in a supine position, clamping the nephrostomy catheter and forcing diuresis. Superselective embolisation is required in less than 1% of cases and has proved effective in more than 90% of cases (149). Short-term deleterious effects are more pronounced in patients with a solitary kidney, but long-term follow-up shows functional and morphological improvements (150). Termination of PCNL if the renal pelvis is torn or ruptured is a safe choice. Management requires close monitoring, placement of an abdominal or retroperitoneal drain and supportive measures (151). Most surgical venous injuries have partial lacerations that can be managed with techniques, such as venorrhaphy, patch angioplasty with autologous vein, or expanded polytetrafluoroethylene (ePTFE) graft (152).

If conservative measures fail in cases of pseudoaneurysm and clinical symptoms or a relevant decrease in haemoglobin occurs, transarterial embolisation should be considered (153). As the success rate is similar for initial and repeat interventions, a repeat intervention is justified when the clinical course allows this (70). Traditionally, patients with postoperative haemorrhage following intra-abdominal laparoscopic surgery of the kidney require laparotomy. Pseudoaneurysms and AVF are uncommon after minimally invasive partial nephrectomy, but can lead to significant morbidity. Temporary haemostasis occurs with coagulation and/or tamponade, but later degradation of the clot, connection with the extravascular space, and possible fistulisation with the collecting system may develop. Patients typically present with gross haematuria, although they may also experience flank pain, dizziness and fever. Embolisation is the reference standard for both diagnosis and treatment in the acute setting, although CT can be used if the symptoms are not severe and/or the diagnosis is ambiguous. Reports have described good preservation of renal function after embolisation (154).

Endoluminal management after renal transplantation consists of stabilising the intimal flap with stent placement. Embolisation is the treatment of choice for a symptomatic transplant AVF or enlarging pseudoaneurysm (155). Superselective embolisation with a coaxial catheter and metallic coils helps limit the loss of normal functioning graft tissue (156). A success rate of 71-100% has been reported, with alleviation of symptoms in 57-88% of cases. Major infarcts involving more than 30-50% of the allograft and leading to

allograft loss have been reported in up to 28.6% of cases in which combined coil embolisation and polyvinyl alcohol or Gelfoam were used. If symptoms persist, a second angiogram with a possible repeat embolisation is warranted (157). Failure of embolisation is associated with a high nephrectomy rate. The long-term outcome depends on the course of the transplant and the amount of contrast medium used during the procedure. Surgical treatment for AVF consists of partial or total nephrectomy or arterial ligation, which results in loss of part of the transplant or the entire transplant.

Surgery has to date been the main approach in the treatment of renal vascular injuries. In patients with retroperitoneal haematoma, AVFs, and haemorrhagic shock, interventional therapy is associated with a lower level of risk than surgery (72). Renal arteriography followed by selective embolisation can confirm the injury. In injuries during angioplasty and stent-graft placement, transcatheter embolisation is the first choice of treatment (158). The treatment for acute iatrogenic rupture of the main renal artery is balloon tamponade. If this fails, immediate availability of a stent graft is vital (159). The true nature of lesions caused by foreign bodies is revealed after exploration.

### 2.5.5 Statements and recommendations

| Statements   | LE |
|--|----|
| Iatrogenic renal injuries are procedure-dependent (1.8-15%).       | 3  |
| Significant injury requiring intervention is rare.                 | 3  |
| Most common injuries are vascular.                                 | 3  |
| Renal allografts are more susceptible.                             | 3  |
| Injuries occurring during surgery are rectified immediately.       | 3  |
| Symptoms suggestive of a significant injury require investigation. | 3  |

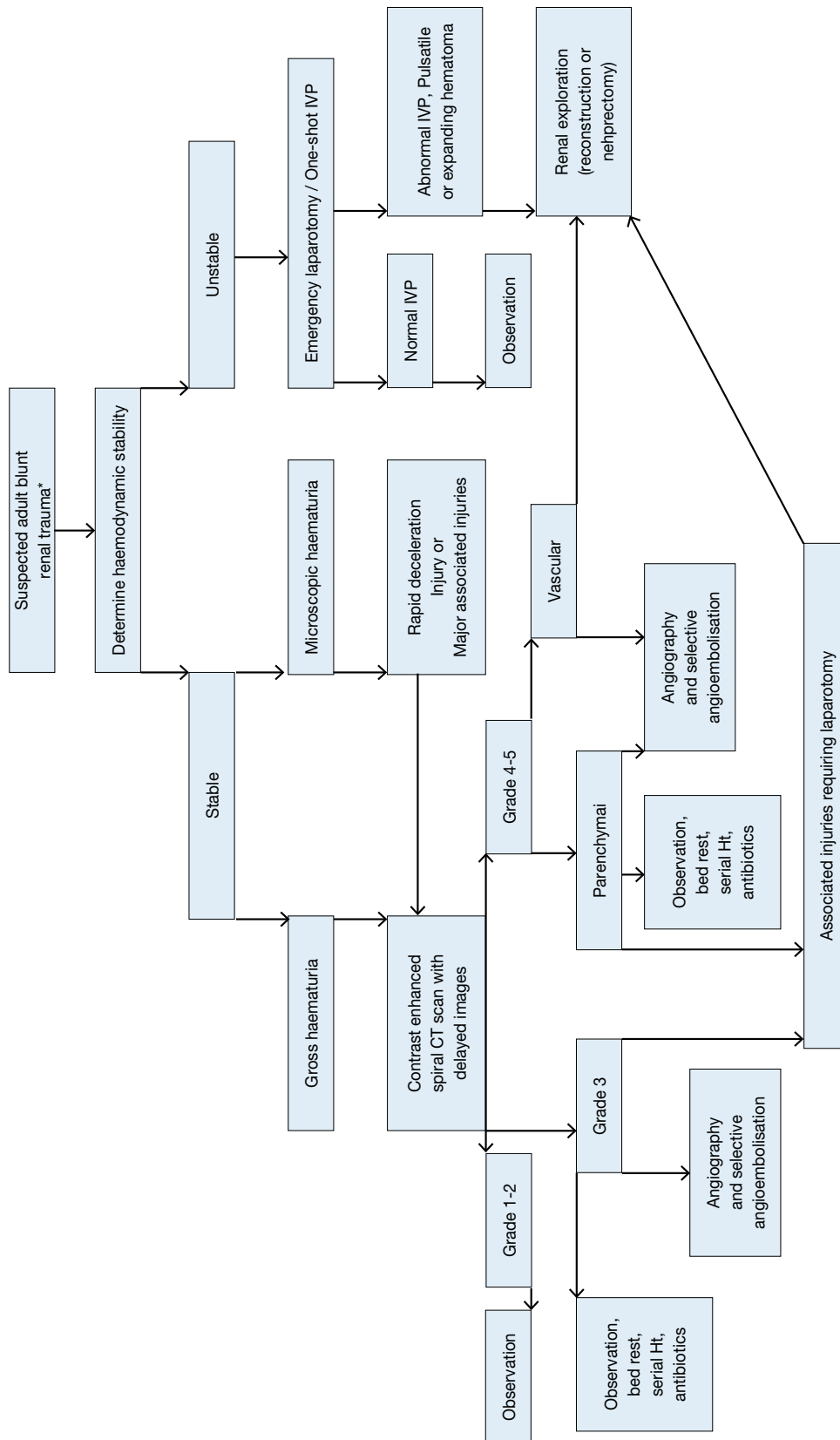
GR = grade; LE = level of evidence

| Recommendations  | GR |
|--|----|
| Patients with minor injuries should be treated conservatively.                     | B  |
| Severe or persistent injuries require intervention with embolisation.              | B  |
| In stable patients, a second embolisation should be considered in case of failure. | C  |

## 2.6 Algorithms

Figures 1 and 2 show the suggested treatment of blunt and penetrating renal injuries in adults.

Figure 1: Evaluation of blunt renal trauma in adults

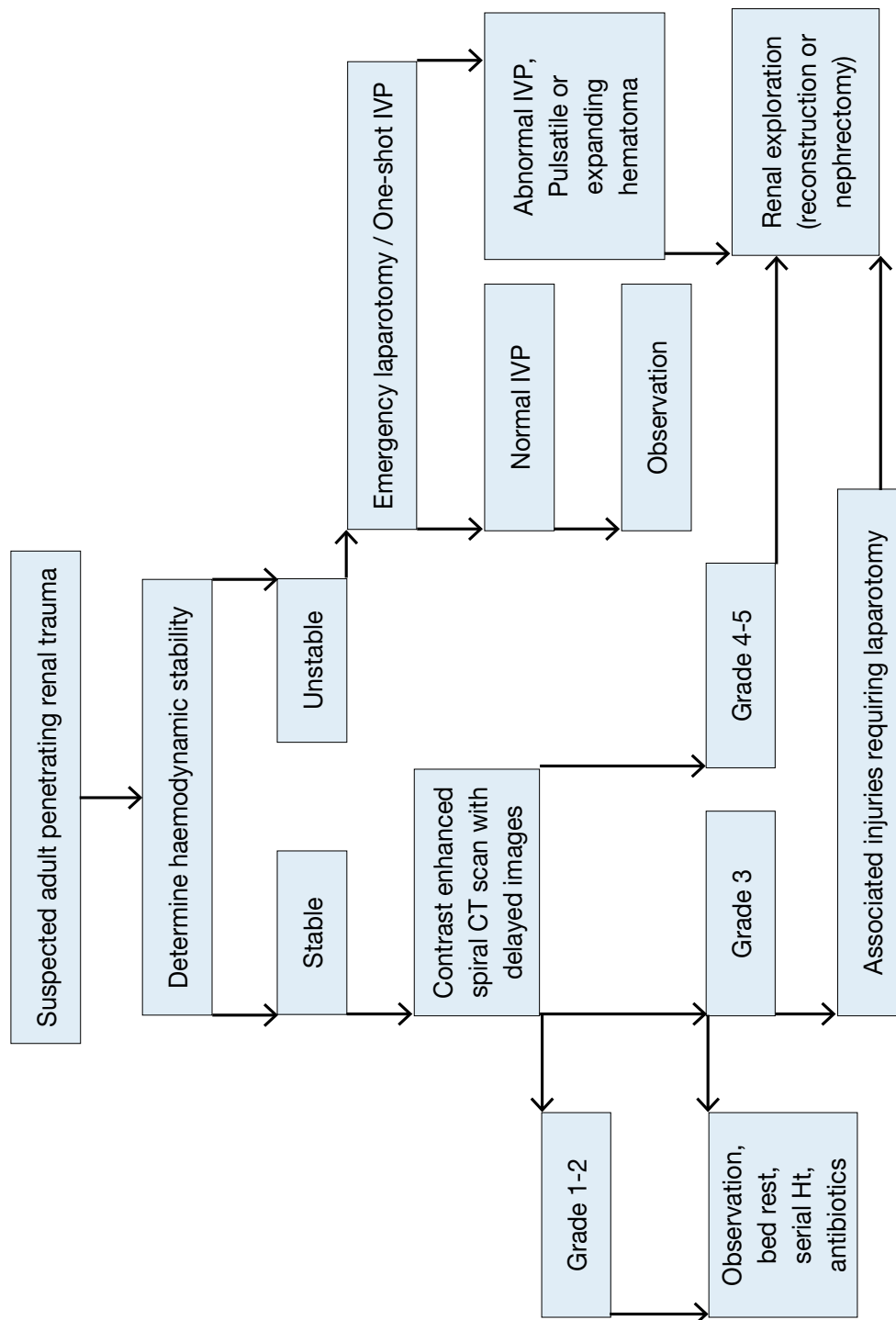


\*Suspected renal trauma results from reported mechanism of injury and physical examination.

† Renal imaging: CT scans are the gold standard for evaluating blunt and penetrating renal injuries in stable patients. In settings where the method is not available, the urologist should rely on other imaging modalities (IVP, angiography, radiographic scintigraphy, MRI).

‡ Renal exploration: Although renal salvage is a primary goal for the urologist, decisions concerning the viability of the organ and the type of reconstruction are made during the operation.

Figure 2: Evaluation of penetrating renal trauma in adults



\*Suspected renal trauma results from reported mechanism of injury and physical examination.

† Renal imaging: CT scans are the gold standard for evaluating blunt and penetrating renal injuries in stable patients. In settings where the method is not available, the urologist should rely on other imaging modalities (IVP, angiography, radiographic scintigraphy, MRI).

‡ Renal exploration: Although renal salvage is a primary goal for the urologist, decisions concerning the viability of the organ and the type of reconstruction are made during the operation.

## 2.7 References

1. McAninch JW. Genitourinary trauma. *World J Urol* 1999 Apr;17(2):65.  
<http://www.ncbi.nlm.nih.gov/pubmed/10367362>
2. Meng MV, Brandes SB, McAninch JW. Renal trauma: indications and techniques for surgical exploration. *World J Urol* 1999 Apr;17(2):71-7.  
<http://www.ncbi.nlm.nih.gov/pubmed/10367364>
3. Paparel P, N'Diaye A, Laumon B, et al. The epidemiology of trauma of the genitourinary system after traffic accidents: analysis of a register of over 43,000 victims. *BJU Int* 2006 Feb;97(2):338-41.  
<http://www.ncbi.nlm.nih.gov/pubmed/16430642>
4. Kristjánsson A, Pedersen J. Management of blunt renal trauma. *Br J Urol* 1993 Nov;72(5Pt2):692-6.  
<http://www.ncbi.nlm.nih.gov/pubmed/8281396>
5. Bjurlin MA, Goble SM, Fantus RJ, et al. Outcomes in geriatric genitourinary trauma. *J Am Coll Surg* 2011 Sep;213(3):415-21.  
<http://www.ncbi.nlm.nih.gov/pubmed/21723152>
6. Danuser H, Wille S, Zöschner G, et al. How to treat blunt kidney ruptures: primary open surgery or conservative treatment with deferred surgery when necessary? *Eur Urol* 2001 Jan;39(1):9-14.  
<http://www.ncbi.nlm.nih.gov/pubmed/11173932>
7. Hurtuk M, Reed RL 2nd, Esposito TJ, et al. Trauma surgeons practice what they preach. The NTDB story on solid organ injury management. *J Trauma* 2006 Aug;61(2):243-54; discussion 254-5.  
<http://www.ncbi.nlm.nih.gov/pubmed/16917435>
8. Santucci RA, Fisher MB. The literature increasingly supports expectant (conservative) management of renal trauma--a systematic review. *J Trauma* 2005 Aug;59(2):493-503.  
<http://www.ncbi.nlm.nih.gov/pubmed/16294101>
9. Santucci RA, McAninch JW. Diagnosis and management of renal trauma: past, present, and future. *J Am Coll Surg* 2000 Oct;191(4):443-51.  
<http://www.ncbi.nlm.nih.gov/pubmed/111030250>
10. Sangthong B, Demetriades D, Martin M, et al. Management and hospital outcomes of blunt renal artery injuries: analysis of 517 patients from the National Trauma Data Bank. *J Am Coll Surg* 2006 Nov;203(5):612-7.  
<http://www.ncbi.nlm.nih.gov/pubmed/17084321>
11. Kansas BT, Eddy MJ, Mydlo JH, et al. Incidence and management of penetrating renal trauma in patients with multiorgan injury: extended experience at an inner city trauma center. *J Urol* 2004 Oct;172(4Pt1):1355-60.  
<http://www.ncbi.nlm.nih.gov/pubmed/15371841>
12. Santucci RA, Wessells H, Bartsch G, et al. Evaluation and management of renal injuries: consensus statement of the renal trauma subcommittee. *BJU Int* 2004 May;93(7):937-54.  
<http://www.ncbi.nlm.nih.gov/pubmed/15142141>
13. Kuan JK, Kaufman R, Wright JL, et al. Renal injury mechanisms of motor vehicle collisions: analysis of the crash injury research and engineering network data set. *J Urol* 2007 Sep;178(3Pt1):935-40; discussion 940.  
<http://www.ncbi.nlm.nih.gov/pubmed/17632156>
14. Smith TG 3rd, Wessells HB, Mack CD, et al. Examination of the impact of airbags on renal injury using a national database. *J Am Coll Surg* 2010 Sep;211(3):355-60.  
<http://www.ncbi.nlm.nih.gov/pubmed/20800192>
15. Brandes SB, McAninch JW. Urban free falls and patterns of renal injury: a 20-year experience with 396 cases. *J Trauma* 1999 Oct;47(4):643-9; discussion 649-50.  
<http://www.ncbi.nlm.nih.gov/pubmed/10528597>
16. Bruce LM, Croce MA, Santaniello JM, et al. Blunt renal artery injury: incidence, diagnosis, and management. *Am Surg* 2001 Jun;67(6):550-4; discussion 555-6.  
<http://www.ncbi.nlm.nih.gov/pubmed/11409803>
17. Najibi S, Tannast M, Latini JM. Civilian gunshot wounds to the genitourinary tract: incidence, anatomic distribution, associated injuries, and outcomes. *Urology* 2010 Oct;76(4):977-81; discussion 981.  
<http://www.ncbi.nlm.nih.gov/pubmed/20605196>
18. Abu-Zidan FM, Al-Tawheed A, Ali YM. Urologic injuries in the Gulf War. *Int Urol Nephrol* 1999;31(5):577-83.  
<http://www.ncbi.nlm.nih.gov/pubmed/10755347>
19. Tucak A, Lukacevic T, Kuvezdic H, et al. Urogenital wounds during the war in Croatia in 1991/1992. *J Urol* 1995 Jan;153(1):121-2.  
<http://www.ncbi.nlm.nih.gov/pubmed/7966742>



20. Paquette EL. Genitourinary trauma at a combat support hospital during Operation Iraqi Freedom: the impact of body armor. *J Urol* 2007 Jun;177(6):2196-9; discussion 2199.  
<http://www.ncbi.nlm.nih.gov/pubmed/17509316>
21. Lent V. What classification is appropriate in renal trauma? *Eur Urol* 1996;30(3):327-34.  
<http://www.ncbi.nlm.nih.gov/pubmed/8931965>
22. Moore EE, Shackford SR, Pachter HL, et al. Organ injury scaling: spleen, liver, and kidney. *J Trauma* 1989 Dec;29(12):1664-6.  
<http://www.ncbi.nlm.nih.gov/pubmed/2593197>
23. Shariat SF, Roehrborn CG, Karakiewicz PI, et al. Evidence-based validation of the predictive value of the American Association for the Surgery of Trauma kidney injury scale. *J Trauma* 2007 Apr;62(4):933-9.  
<http://www.ncbi.nlm.nih.gov/pubmed/17426551>
24. Santucci RA, McAninch JW, Safir M, et al. Validation of the American Association for the Surgery of Trauma organ injury severity scale for the kidney. *J Trauma* 2001 Feb;50(2):195-200.  
<http://www.ncbi.nlm.nih.gov/pubmed/11242281>
25. Kuan JK, Wright JL, Nathens AB, et al; American Association for the Surgery of Trauma. American Association for the Surgery of Trauma Organ Injury Scale for kidney injuries predicts nephrectomy, dialysis, and death in patients with blunt injury and nephrectomy for penetrating injuries. *J Trauma* 2006 Feb;60(2):351-6.  
<http://www.ncbi.nlm.nih.gov/pubmed/16508495>
26. Dugi DD 3rd, Morey AF, Gupta A, et al. American Association for the Surgery of Trauma grade 4 renal injury substratification into grades 4a (low risk) and 4b (high risk). *J Urol* 2010 Feb;183(2):592-7.  
<http://www.ncbi.nlm.nih.gov/pubmed/20018329>
27. Buckley JC, McAninch JW. Revision of current American Association for the Surgery of Trauma Renal Injury grading system. *J Trauma* 2011 Jan;70(1):35-7.  
<http://www.ncbi.nlm.nih.gov/pubmed/21217478>
28. Cachecho R, Millham FH, Wedel SK. Management of the trauma patient with pre-existing renal disease. *Crit Care Clin* 1994 Jul;10(3):523-36.  
<http://www.ncbi.nlm.nih.gov/pubmed/7922736>
29. Cózar JM, Cárcamo P, Hidalgo L, et al. [Management of injury of the solitary kidney]. *Arch Esp Urol* 1990 Jan-Feb;43(1):15-18. [Article in Spanish]  
<http://www.ncbi.nlm.nih.gov/pubmed/2331159>
30. Sebastià MC, Rodríguez-Dobao M, Quiroga S, et al. Renal trauma in occult ureteropelvic junction obstruction: CT findings. *Eur Radiol* 1999;9(4):611-15.  
<http://www.ncbi.nlm.nih.gov/pubmed/10354870>
31. Bahloul A, Krid M, Trifa M, et al. [Contusions to the pathologic kidney. A retrospective study, apropos of 34 cases]. *Ann Urol (Paris)* 1997;31(5):253-8. [Article in French]  
<http://www.ncbi.nlm.nih.gov/pubmed/9480628>
32. Giannopoulos A, Serafetinides E, Alamanis C, et al. [Urogenital lesions diagnosed incidentally during evaluation for blunt renal injuries]. *Prog Urol* 1999 Jun;9(3):464-9. [Article in French]  
<http://www.ncbi.nlm.nih.gov/pubmed/10434318>
33. Buchberger W, Penz T, Wicke K, et al. [Diagnosis and staging of blunt kidney trauma. A comparison of urinalysis, i.v. urography, sonography and computed tomography]. *Rofo* 1993 Jun;158(6):507-12. [Article in German]  
<http://www.ncbi.nlm.nih.gov/pubmed/8507839>
34. Carroll PR, McAninch JW, Klosterman P, et al. Renovascular trauma: risk assessment, surgical management, and outcome. *J Trauma* 1990 May;30(5):547-52; discussion 553-4.  
<http://www.ncbi.nlm.nih.gov/pubmed/2342137>
35. Eastham JA, Wilson TG, Larsen DW, et al. Angiographic embolisation of renal stab wounds. *J Urol* 1992 Aug;148(2Pt1):268-70.  
<http://www.ncbi.nlm.nih.gov/pubmed/1635114>
36. Schmidlin FR, Iselin CE, Naimi A, et al. The higher injury risk of abnormal kidneys in blunt renal trauma. *Scand J Urol Nephrol* 1998 Dec;32(6):388-92.  
<http://www.ncbi.nlm.nih.gov/pubmed/9925001>
37. Chandhoke PS, McAninch JW. Detection and significance of microscopic hematuria in patients with blunt renal trauma. *J Urol* 1988 Jul;140(1):16-18.  
<http://www.ncbi.nlm.nih.gov/pubmed/3379684>
38. Miller KS, McAninch JW. Radiographic assessment of renal trauma: our 15-year experience. *J Urol* 1995 Aug;154(2Pt1):352-5.  
<http://www.ncbi.nlm.nih.gov/pubmed/7609096>

39. Heyns CF. Renal trauma: indications for imaging and surgical exploration. *BJU Int* 2004 May;93(8):1165-70.  
<http://www.ncbi.nlm.nih.gov/pubmed/15142132>
40. Mee SL, McAninch JW. Indications for radiographic assessment in suspected renal trauma. *Urol Clin North Am* 1989 May;16(2):187-92.  
<http://www.ncbi.nlm.nih.gov/pubmed/2652848>
41. Rippey JC, Royse AG. Ultrasound in trauma. *Best Pract Res Clin Anaesthesiol* 2009 Sep;23(3):343-62.  
<http://www.ncbi.nlm.nih.gov/pubmed/19862893>
42. Gaitini D, Razi NB, Ghersin E, et al. Sonographic evaluation of vascular injuries. *J Ultrasound Med* 2008 Jan;27(1):95-107.  
<http://www.ncbi.nlm.nih.gov/pubmed/18096735>
43. Valentino M, Serra C, Zironi G, et al. Blunt abdominal trauma: emergency contrast-enhanced sonography for detection of solid organ injuries. *AJR Am J Roentgenol* 2006 May;186(5):1361-7.  
<http://www.ncbi.nlm.nih.gov/pubmed/16632732>
44. Qin R, Wang P, Qin W, et al. Diagnosis and treatment of renal trauma in 298 patients. *Chin J Traumatol* 2002 Feb;5(1):21-3.  
<http://www.ncbi.nlm.nih.gov/pubmed/11835751>
45. Bent C, Iyngkaran T, Power N, et al. Urological injuries following trauma. *Clin Radiol* 2008 Dec;63(12):1361-71.  
<http://www.ncbi.nlm.nih.gov/pubmed/18996268>
46. Morey AF, McAninch JW, Tiller BK, et al. Single shot intraoperative excretory urography for the immediate evaluation of renal trauma. *J Urol* 1999 Apr;161(4):1088-92.  
<http://www.ncbi.nlm.nih.gov/pubmed/10081844>
47. Patel VG, Walker ML. The role of 'one-shot' intravenous pyelogram in evaluation of penetrating abdominal trauma. *Am Surg* 1997 Apr;63(4):350-3.  
<http://www.ncbi.nlm.nih.gov/pubmed/9124757>
48. Steinberg DL, Jeffrey RB, Federle MP, et al. The computerized tomography appearance of renal pedicle injury. *J Urol* 1984 Dec;132(6):1163-4.  
<http://www.ncbi.nlm.nih.gov/pubmed/6502811>
49. Kawashima A, Sandler CM, Corl FM, et al. Imaging of renal trauma: a comprehensive review. *Radiographics* 2001 May-Jun;21(3):557-74.  
<http://www.ncbi.nlm.nih.gov/pubmed/11353106>
50. Shima H, Nosaka S, Hayakawa M, et al. [Diagnostic imaging of renal pedicle injury]. *Nippon Igaku Hoshasen Gakkai Zasshi* 1997 Jan;57(1):5-11. [Article in Japanese]  
<http://www.ncbi.nlm.nih.gov/pubmed/9038056>
51. Vasile M, Bellin MF, Hélénon O, et al. Imaging evaluation of renal trauma. *Abdom Imaging* 2000 Jul-Aug;25(4):424-30.  
<http://www.ncbi.nlm.nih.gov/pubmed/10926198>
52. Uyeda JW, Anderson SW, Sakai O, et al. CT angiography in trauma. *Radiol Clin North Am*. 2010 Mar;48(2):423-38.  
<http://www.ncbi.nlm.nih.gov/pubmed/20609881>
53. Brown SL, Hoffman DM, Spirnak JP. Limitations of routine spiral computerized tomography in the evaluation of blunt renal trauma. *J Urol* 1998 Dec;160(6Pt1):1979-81.  
<http://www.ncbi.nlm.nih.gov/pubmed/9817304>
54. Ortega SJ, Netto FS, Hamilton P, et al. CT scanning for diagnosing blunt ureteral and ureteropelvic junction injuries. *BMC Urol* 2008 Feb;8:3.  
<http://www.ncbi.nlm.nih.gov/pubmed/18257927>
55. Velmahos GC, Constantinou C, Tillou A, et al. Abdominal computed tomographic scan for patients with gunshot wounds to the abdomen selected for nonoperative management. *J Trauma* 2005 Nov;59(5):1155-60; discussion 1160-1.  
<http://www.ncbi.nlm.nih.gov/pubmed/16385294>
56. Eurin M, Haddad N, Zappa M, et al. Incidence and predictors of missed injuries in trauma patients in the initial hot report of whole-body CT scan. *Injury* 2012 Jan;43(1):73-7.  
<http://www.ncbi.nlm.nih.gov/pubmed/21663908>
57. Ku JH, Jeon YS, Kim ME, et al. Is there a role for magnetic resonance imaging in renal trauma? *Int J Urol* 2001 Jun;8(6):261-7.  
<http://www.ncbi.nlm.nih.gov/pubmed/11389740>
58. Leppäniemi A, Lamminen A, Tervahartiala P, et al. MRI and CT in blunt renal trauma: an update. *Semin Ultrasound CT MR* 1997 Apr;18(2):129-35.  
<http://www.ncbi.nlm.nih.gov/pubmed/9163832>

59. Shariat SF, Trinh QD, Morey AF, et al. Development of a highly accurate nomogram for prediction of the need for exploration in patients with renal trauma. *J Trauma* 2008 Jun;64(6):1451-8.  
<http://www.ncbi.nlm.nih.gov/pubmed/18545108>
60. Husmann DA, Gilling PJ, Perry MO, et al. Major renal lacerations with a devitalized fragment following blunt abdominal trauma: a comparison between nonoperative (expectant) versus surgical management. *J Urol* 1993 Dec;150(6):1774-7.  
<http://www.ncbi.nlm.nih.gov/pubmed/8230501>
61. McAninch JW, Carroll PR, Klosterman PW, et al. Renal reconstruction after injury. *J Urol* 1991 May;145(5):932-7.  
<http://www.ncbi.nlm.nih.gov/pubmed/2016804>
62. Armenakas NA, Duckett CP, McAninch JW. Indications for nonoperative management of renal stab wounds. *J Urol* 1999 Mar;161(3):768-71.  
<http://www.ncbi.nlm.nih.gov/pubmed/10022681>
63. Hotaling JM, Wang J, Sorensen MD, et al. A national study of trauma level designation and renal trauma outcomes. *J Urol* 2012 Feb;187(2):536-41.  
<http://www.ncbi.nlm.nih.gov/pubmed/22177171>
64. Broghammer JA, Fisher MB, Santucci RA. Conservative management of renal trauma: a review. *Urology* 2007 Oct;70(4):623-9.  
<http://www.ncbi.nlm.nih.gov/pubmed/17991526>
65. Sartorelli KH, Frumiento C, Rogers FB, et al. Nonoperative management of hepatic, splenic, and renal injuries in adults with multiple injuries. *J Trauma* 2000 Jul;49(1):56-61; discussion 61-2.  
<http://www.ncbi.nlm.nih.gov/pubmed/10912858>
66. Toutouzas KG, Karaiskakis M, Kaminski A, et al. Nonoperative management of blunt renal trauma: a prospective study. *Am Surg* 2002 Dec;68(12):1097-103.  
<http://www.ncbi.nlm.nih.gov/pubmed/12516817>
67. Yang CS, Chen IC, Wang CY, et al. Predictive indications of operation and mortality following renal trauma. *J Chin Med Assoc* 2012 Jan;75(1):21-4.  
<http://www.ncbi.nlm.nih.gov/pubmed/22240532>
68. Hagiwara A, Sakaki S, Goto H, et al. The role of interventional radiology in the management of blunt renal injury: a practical protocol. *J Trauma* 2001 Sep;51(3):526-31.  
<http://www.ncbi.nlm.nih.gov/pubmed/11535904>
69. Nuss GR, Morey AF, Jenkins AC, et al. Radiographic predictors of need for angiographic embolisation after traumatic renal injury. *J Trauma* 2009 Sep;67(3):578-82; discussion 582.  
<http://www.ncbi.nlm.nih.gov/pubmed/19741403>
70. Huber J, Pahernik S, Hallscheidt P, et al. Selective transarterial embolisation for posttraumatic renal hemorrhage: a second try is worthwhile. *J Urol* 2011 May;185(5):1751-5.  
<http://www.ncbi.nlm.nih.gov/pubmed/21420122>
71. Fu CY, Wang YC, Wu SC, et al. Angioembolisation provides benefits in patients with concomitant unstable pelvic fracture and unstable hemodynamics. *Am J Emerg Med* 2012 Jan;30(1):207-13.  
<http://www.ncbi.nlm.nih.gov/pubmed/21159470>
72. Breyer BN, McAninch JW, Elliott SP, et al. Minimally invasive endovascular techniques to treat acute renal hemorrhage. *J Urol* 2008 Jun;179(6):2248-52; discussion 2253.  
<http://www.ncbi.nlm.nih.gov/pubmed/18423679>
73. Chow SJ, Thompson KJ, Hartman JF, et al. A 10-year review of blunt renal artery injuries at an urban level I trauma centre. *Injury* 2009 Aug;40(8):844-50.  
<http://www.ncbi.nlm.nih.gov/pubmed/19486971>
74. Sofocleous CT, Hinrichs C, Hubbi B, et al. Angiographic findings and embolotherapy in renal arterial trauma. *Cardiovasc Intervent Radiol* 2005 Jan-Feb;28(1):39-47.  
<http://www.ncbi.nlm.nih.gov/pubmed/15602636>
75. Brewer ME Jr, Strnad BT, Daley BJ, et al. Percutaneous embolisation for the management of grade 5 renal trauma in hemodynamically unstable patients: initial experience. *J Urol* 2009 Apr;181(4):1737-41.  
<http://www.ncbi.nlm.nih.gov/pubmed/19233429>
76. Sarani B, Powell E, Taddeo J, et al. Contemporary comparison of surgical and interventional arteriography management of blunt renal injury. *J Vasc Interv Radiol* 2011 May;22(5):723-8.  
<http://www.ncbi.nlm.nih.gov/pubmed/21514526>
77. Hammer CC, Santucci RA. Effect of an institutional policy of nonoperative treatment of grades I to IV renal injuries. *J Urol* 2003 May;169(5):1751-3.  
<http://www.ncbi.nlm.nih.gov/pubmed/12686825>

78. Robert M, Drianno N, Muir G, et al. Management of major blunt renal lacerations: surgical or nonoperative approach? *Eur Urol* 1996;30(3):335-9.  
<http://www.ncbi.nlm.nih.gov/pubmed/8931966>
79. Nash PA, Bruce JE, McAninch JW. Nephrectomy for traumatic renal injuries. *J Urol* 1995 Mar; 153(3 Pt 1):609-11.  
<http://www.ncbi.nlm.nih.gov/pubmed/7861494>
80. Gonzalez RP, Falimirski M, Holevar MR, et al. Surgical management of renal trauma: is vascular control necessary? *J Trauma* 1999 Dec;47(6):1039-42; discussion 1042-4.  
<http://www.ncbi.nlm.nih.gov/pubmed/10608530>
81. Atala A, Miller FB, Richardson JD, et al. Preliminary vascular control for renal trauma. *Surg Gynecol Obstet* 1991 May;172(5):386-90.  
<http://www.ncbi.nlm.nih.gov/pubmed/2028374>
82. Davis KA, Reed RL 2nd, Santaniello J, et al. Predictors of the need for nephrectomy after renal trauma. *J Trauma* 2006 Jan;60(1):164-9; discussion 169-70.  
<http://www.ncbi.nlm.nih.gov/pubmed/16456451>
83. Wright JL, Nathens AB, Rivara FP, et al. Renal and extrarenal predictors of nephrectomy from the national trauma data bank. *J Urol* 2006 Mar;175(3Pt1):970-5; discussion 975.  
<http://www.ncbi.nlm.nih.gov/pubmed/16469594>
84. DiGiacomo JC, Rotondo MF, Kauder DR, et al. The role of nephrectomy in the acutely injured. *Arch Surg* 2001 Sep;136(9):1045-9.  
<http://www.ncbi.nlm.nih.gov/pubmed/11529828>
85. Brandes SB, McAninch JW. Reconstructive surgery for trauma of the upper urinary tract. *Urol Clin North Am* 1999 Feb;26(1):183-99.  
<http://www.ncbi.nlm.nih.gov/pubmed/10086060>
86. McAninch JW, Dixon CM, Carroll PR. [The surgical treatment of renal trauma]. *Vestn Khir Im I I Grek* 1990 Nov;145(11):64-72. [Article in Russian]  
<http://www.ncbi.nlm.nih.gov/pubmed/1966179>
87. Shekarriz B, Stoller ML. The use of fibrin sealant in urology. *J Urol* 2002 Mar;167(3):1218-25.  
<http://www.ncbi.nlm.nih.gov/pubmed/11832701>
88. Knudson MM, Harrison PB, Hoyt DB, et al. Outcome after major renovascular injuries: a Western trauma association multicenter report. *J Trauma* 2000 Dec;49(6):1116-22.  
<http://www.ncbi.nlm.nih.gov/pubmed/11130498>
89. Tillou A, Romero J, Asensio JA, et al. Renal vascular injuries. *Surg Clin North Am* 2001 Dec;81(6):417-30.  
<http://www.ncbi.nlm.nih.gov/pubmed/11766183>
90. Schmidlin FR, Rohner S, Hadaya K, et al. [The conservative treatment of major kidney injuries]. *Ann Urol (Paris)* 1997;31(5):246-52. [Article in French]  
<http://www.ncbi.nlm.nih.gov/pubmed/9480627>
91. Holmes JF, McGahan JP, Wisner DH. Rate of intra-abdominal injury after a normal abdominal computed tomographic scan in adults with blunt trauma. *Am J Emerg Med* 2012 May;30(4):574-9.  
<http://www.ncbi.nlm.nih.gov/pubmed/21641163>
92. el Khader K, Mhidia A, Ziade J, et al. [Conservative treatment of stage III kidney injuries]. *Acta Urol Belg* 1998 Dec;66(4):25-8. [Article in French]  
<http://www.ncbi.nlm.nih.gov/pubmed/10083630>
93. Thall EH, Stone NN, Cheng DL, et al. Conservative management of penetrating and blunt Type III renal injuries. *Br J Urol* 1996 Apr;77(4):512-7.  
<http://www.ncbi.nlm.nih.gov/pubmed/8777609>
94. Cheng DL, Lazan D, Stone N. Conservative treatment of type III renal trauma. *J Trauma* 1994 Apr;36(4):491-4.  
<http://www.ncbi.nlm.nih.gov/pubmed/8158708>
95. Alsikafi NF, McAninch JW, Elliott SP, et al. Nonoperative management outcomes of isolated urinary extravasation following renal lacerations due to external trauma. *J Urol* 2006 Dec;176(6Pt1):2494-7.  
<http://www.ncbi.nlm.nih.gov/pubmed/17085140>
96. Buckley JC, McAninch JW. Selective management of isolated and nonisolated grade IV renal injuries. *J Urol* 2006 Dec;176(6Pt1):2498-502; discussion 2502.  
<http://www.ncbi.nlm.nih.gov/pubmed/17085141>
97. Santucci RA, McAninch JM. Grade IV renal injuries: evaluation, treatment, and outcome. *World J Surg* 2001 Dec;25(12):1565-72.  
<http://www.ncbi.nlm.nih.gov/pubmed/11775193>

98. Altman AL, Haas C, Dinchman KH, et al. Selective nonoperative management of blunt grade 5 renal injury. *J Urol* 2000 Jul;164(1):27-30;discussion 30-1.  
<http://www.ncbi.nlm.nih.gov/pubmed/10840417>
99. Moudouni SM, Hadj Slimen M, Manunta A, et al. Management of major blunt renal lacerations: is a nonoperative approach indicated? *Eur Urol* 2001 Oct;40(4):409-14.  
<http://www.ncbi.nlm.nih.gov/pubmed/11713395>
100. Husmann DA, Morris JS. Attempted nonoperative management of blunt renal lacerations extending through the corticomedullary junction: the short-term and long-term sequelae. *J Urol* 1990 Apr;143(4):682-4.  
<http://www.ncbi.nlm.nih.gov/pubmed/2313792>
101. Elliott SP, Olweny EO, McAninch JW. Renal arterial injuries: a single center analysis of management strategies and outcomes. *J Urol* 2007 Dec;178(6):2451-5.  
<http://www.ncbi.nlm.nih.gov/pubmed/17937955>
102. Jawas A, Abu-Zidan FM. Management algorithm for complete blunt renal artery occlusion in multiple trauma patients: case series. *Int J Surg* 2008 Aug;6(4):317-22.  
<http://www.ncbi.nlm.nih.gov/pubmed/18590988>
103. Shariat SF, Jenkins A, Roehrborn CG, et al. Features and outcomes of patients with grade IV renal injury. *BJU Int* 2008 Sep;102(6):728-33; discussion 733.  
<http://www.ncbi.nlm.nih.gov/pubmed/18435808>
104. Velmahos GC, Demetriades D, Cornwell EE 3rd, et al. Selective management of renal gunshot wounds. *Br J Surg* 1998 Aug;85(8):1121-4.  
<http://www.ncbi.nlm.nih.gov/pubmed/9718011>
105. Baniel J, Schein M. The management of penetrating trauma to the urinary tract. *J Am Coll Surg* 1994 Apr;178(4):417-25.  
<http://www.ncbi.nlm.nih.gov/pubmed/8149045>
106. DuBose J, Inaba K, Teixeira PG, et al. Selective non-operative management of solid organ injury following abdominal gunshot wounds. *Injury* 2007 Sep;38(9):1084-90.  
<http://www.ncbi.nlm.nih.gov/pubmed/17544428>
107. Shefler A, Gremitzky A, Vainrib M, et al. [The role of nonoperative management of penetrating renal trauma]. *Harefuah* 2007 May;146(5):345-8, 406-7. [Article in Hebrew]  
<http://www.ncbi.nlm.nih.gov/pubmed/17674549>
108. Hope WW, Smith ST, Medieros B, et al. Non-operative management in penetrating abdominal trauma: is it feasible at a Level II trauma center? *J Emerg Med* 2012 Jul;43(1):190-5.  
<http://www.ncbi.nlm.nih.gov/pubmed/22051843>
109. Bernath AS, Schutte H, Fernandez RR, et al. Stab wounds of the kidney: conservative management in flank penetration. *J Urol* 1983 Mar;129(3):468-70.  
<http://www.ncbi.nlm.nih.gov/pubmed/6834529>
110. Wessells H, McAninch JW, Meyer A, et al. Criteria for nonoperative treatment of significant penetrating renal lacerations. *J Urol* 1997 Jan;157(1):24-7.  
<http://www.ncbi.nlm.nih.gov/pubmed/8976207>
111. Jansen JO, Inaba K, Rizoli SB, et al. Selective non-operative management of penetrating abdominal injury in Great Britain and Ireland: Survey of practice. *Injury* 2012 Nov;43(11):1799-804.  
<http://www.ncbi.nlm.nih.gov/pubmed/21529801>
112. Blankenship JC, Gavant ML, Cox CE, et al. Importance of delayed imaging for blunt renal trauma. *World J Surg* 2001 Dec;25(12):1561-4.  
<http://www.ncbi.nlm.nih.gov/pubmed/11775192>
113. McGuire J, Bultitude MF, Davis P, et al. Predictors of outcome for blunt high grade renal injury treated with conservative intent. *J Urol* 2011 Jan;185(1):187-91.  
<http://www.ncbi.nlm.nih.gov/pubmed/21074795>
114. Wessells H, Deirmenjian J, McAninch JW. Preservation of renal function after reconstruction for trauma: quantitative assessment with radionuclide scintigraphy. *J Urol* 1997 May;157(5):1583-6.  
<http://www.ncbi.nlm.nih.gov/pubmed/9112481>
115. Tasian GE, Aaronson DS, McAninch JW. Evaluation of renal function after major renal injury: correlation with the American Association for the Surgery of Trauma Injury Scale. *J Urol* 2010 Jan;183(1):196-200.  
<http://www.ncbi.nlm.nih.gov/pubmed/19913819>
116. Fiard G, Rambeaud JJ, Descotes JL, et al. Long-term renal function assessment with dimercapto-succinic acid scintigraphy after conservative treatment of major renal trauma. *J Urol* 2012 Apr;187(4):1306-9.  
<http://www.ncbi.nlm.nih.gov/pubmed/22341289>

117. Dunfee BL, Lucey BC, Soto JA. Development of renal scars on CT after abdominal trauma: does grade of injury matter? *AJR Am J Roentgenol* 2008 May;190(5):1174-9.  
<http://www.ncbi.nlm.nih.gov/pubmed/18430828>
118. Heyns CF, van Vollenhoven P. Increasing role of angiography and segmental artery embolisation in the management of renal stab wounds. *J Urol* 1992 May;147(5):1231-4.  
<http://www.ncbi.nlm.nih.gov/pubmed/1569655>
119. Monstrey SJ, Beerthuizen GI, vander Werken C, et al. Renal trauma and hypertension. *J Trauma* 1989 Jan;29(1):65-70.  
<http://www.ncbi.nlm.nih.gov/pubmed/2911106>
120. Lebech A, Strange-Vognsen HH. [Hypertension following blunt kidney injury]. *Ugeskr Laeger* 1990 Apr;152(14):994-7. [Article in Danish]  
<http://www.ncbi.nlm.nih.gov/pubmed/2183457>
121. Montgomery RC, Richardson JD, Harty JL. Posttraumatic renovascular hypertension after occult renal injury. *J Trauma* 1998 Jul;45(1):106-10.  
<http://www.ncbi.nlm.nih.gov/pubmed/9680021>
122. Haas CA, Reigle MD, Selzman AA, et al. Use of ureteral stents in the management of major renal trauma with urinary extravasation: is there a role? *J Endourol* 1998 Dec;12(6):545-9.  
<http://www.ncbi.nlm.nih.gov/pubmed/9895260>
123. Matthews LA, Smith EM, Spirnak JP. Nonoperative treatment of major blunt renal lacerations with urinary extravasation. *J Urol* 1997 Jun;157(6):2056-8.  
<http://www.ncbi.nlm.nih.gov/pubmed/9146579>
124. Wang KT, Hou CJ, Hsieh JJ, et al. Late development of renal arteriovenous fistula following gunshot trauma – a case report. *Angiology* 1998 May;49(5):415-18.  
<http://www.ncbi.nlm.nih.gov/pubmed/9591535>
125. Salazar GM, Walker TG. Evaluation and management of acute vascular trauma. *Tech Vasc Interv Radiol* 2009 Jun;12(2):102-16.  
<http://www.ncbi.nlm.nih.gov/pubmed/19853228>
126. Franco de Castro A, Gibanel Garanto R, Real MI, et al. [Selective embolisation of post-traumatic renal pseudoaneurysm in monorenal patient]. *Actas Urol Esp* 2001 Jan;25(1):64-6. [Article in Spanish]  
<http://www.ncbi.nlm.nih.gov/pubmed/11284371>
127. Miller DC, Forauer A, Faerber GJ. Successful angioembolisation of renal artery pseudoaneurysms after blunt abdominal trauma. *Urology* 2002 Mar;59(3):444.  
<http://www.ncbi.nlm.nih.gov/pubmed/11880095>
128. Harrington TG, Kandel LB. Renal colic following a gunshot wound to the abdomen: the birdshot calculus. *J Urol* 1997 Apr;157(4):1351-2.  
<http://www.ncbi.nlm.nih.gov/pubmed/9120940>
129. Park JK, Yang SO, Park SC. Duodenal obstruction by retroperitoneal hematoma induced by severe blunt renal trauma. *J Urol* 2001 Jun;165(6Pt1):1993-4.  
<http://www.ncbi.nlm.nih.gov/pubmed/11371904>
130. Rosen MA, McAninch JW. Management of combined renal and pancreatic trauma. *J Urol* 1994 Jul;152(1):22-5.  
<http://www.ncbi.nlm.nih.gov/pubmed/8201670>
131. Wessells H, McAninch JW. Effect of colon injury on the management of simultaneous renal trauma. *J Urol* 1996 Jun;155(6):1852-6.  
<http://www.ncbi.nlm.nih.gov/pubmed/8618272>
132. Heye S, Vanbeckevoort D, Blockmans D, et al. Iatrogenic main renal artery injury: treatment by endovascular stent-graft placement. *Cardiovasc Intervent Radiol* 2005 Jan-Feb;28(1):93-4.  
<http://www.ncbi.nlm.nih.gov/pubmed/15602634>
133. Albani JM, Novick AC. Renal artery pseudoaneurysm after partial nephrectomy: three case reports and a literature review. *Urology* 2003 Aug;62(2):227-31.  
<http://www.ncbi.nlm.nih.gov/pubmed/12893324>
134. Furness PN, Philpott CM, Chorbadian MT, et al. Protocol biopsy of the stable renal transplant: a multicenter study of methods and complication rates. *Transplantation* 2003 Sep 27;76(6):969-73.  
<http://www.ncbi.nlm.nih.gov/pubmed/14508363>
135. Barley FL, Kessel D, Nicholson T, et al. Selective embolisation of large symptomatic iatrogenic renal transplant arteriovenous fistula. *Cardiovasc Intervent Radiol* 2006 Nov-Dec;29(6):1084-7.  
<http://www.ncbi.nlm.nih.gov/pubmed/16794894>

136. Maleux G, Messiaen T, Stockx L, et al. Transcatheter embolisation of biopsy-related vascular injuries in renal allografts. Long-term technical, clinical and biochemical results. *Acta Radiol* 2003 Jan;44(1):13-7.  
<http://www.ncbi.nlm.nih.gov/pubmed/12630992>
137. Takahashi M, Humke U, Girndt M, et al. Early posttransplantation renal allograft perfusion failure due to dissection: diagnosis and interventional treatment. *AJR Am J Roentgenol* 2003 Mar;180(3):759-63.  
<http://www.ncbi.nlm.nih.gov/pubmed/12591692>
138. Bellman GC. Complications of endopyelotomy. *J Endourol* 1996 Apr;10(2):177-81.  
<http://www.ncbi.nlm.nih.gov/pubmed/8728685>
139. Hinshaw JL, Shadid AM, Nakada SY, et al. Comparison of percutaneous and laparoscopic cryoablation for the treatment of solid renal masses. *AJR Am J Roentgenol* 2008 Oct;191(4):1159-68.  
<http://www.ncbi.nlm.nih.gov/pubmed/18806159>
140. Jones CD, McGahan JP. Computed tomographic evaluation and guided correction of malpositioned nephrostomy catheters. *Abdom Imaging* 1999 Jul-Aug;24(4):422-5.  
<http://www.ncbi.nlm.nih.gov/pubmed/10390572>
141. Lewis S, Patel U. Major complications after percutaneous nephrostomy – lessons from a department audit. *Clin Radiol* 2004 Feb;59(2):171-9.  
<http://www.ncbi.nlm.nih.gov/pubmed/14746788>
142. Phadke RV, Sawlani V, Rastogi H, et al. Iatrogenic renal vascular injuries and their radiological management. *Clin Radiol* 1997 Feb;52(2):119-23.  
<http://www.ncbi.nlm.nih.gov/pubmed/9043045>
143. Cohenpour M, Strauss S, Gottlieb P, et al. Pseudoaneurysm of the renal artery following partial nephrectomy: imaging findings and coil embolisation. *Clin Radiol* 2007 Nov;62(11):1104-9.  
<http://www.ncbi.nlm.nih.gov/pubmed/17920871>
144. Loffroy R, Guiu B, Lambert A, et al. Management of post-biopsy renal allograft arteriovenous fistulas with selective arterial embolisation: immediate and long-term outcomes. *Clin Radiol* 2008 Jun;63(6):657-65.  
<http://www.ncbi.nlm.nih.gov/pubmed/18455557>
145. Ben Meir D, Lask D, Koren R, et al. Intrarenal foreign body presenting as a solid tumor. *Urology* 2003 May;61(5):1035.  
<http://www.ncbi.nlm.nih.gov/pubmed/12736036>
146. Nakada SY, Johnson M. Ureteropelvic junction obstruction. Retrograde endopyelotomy. *Urol Clin North Am* 2000 Nov;27(4):677-84.  
<http://www.ncbi.nlm.nih.gov/pubmed/11098766>
147. Silberzweig JE, Tey S, Winston JA, et al. Percutaneous renal biopsy complicated by renal capsular artery pseudoaneurysm. *Am J Kidney Dis* 1998 Mar;31(3):533-5.  
<http://www.ncbi.nlm.nih.gov/pubmed/9506693>
148. Gupta M, Bellman GC, Smith AD. Massive hemorrhage from renal vein injury during percutaneous renal surgery: endourological management. *J Urol* 1997 Mar;157(3):795-7.  
<http://www.ncbi.nlm.nih.gov/pubmed/9072568>
149. El-Nahas AR, Shokeir AA, El-Assmy AM, et al. Post-percutaneous nephrolithotomy extensive hemorrhage: a study of risk factors. *J Urol* 2007 Feb;177(2):576-9.  
<http://www.ncbi.nlm.nih.gov/pubmed/17222636>
150. El-Nahas AR, Shokeir AA, Mohsen T, et al. Functional and morphological effects of postpercutaneous nephrolithotomy superselective renal angiographic embolisation. *Urology* 2008 Mar;71(3):408-12.  
<http://www.ncbi.nlm.nih.gov/pubmed/18342174>
151. Ghai B, Dureja GP, Arvind P. Massive intraabdominal extravasation of fluid: a life threatening complication following percutaneous nephrolithotomy. *Int Urol Nephrol* 2003;35(3):315-18.  
<http://www.ncbi.nlm.nih.gov/pubmed/15160530>
152. Oderich GS, Panneton JM, Hofer J, et al. Iatrogenic operative injuries of abdominal and pelvic veins: a potentially lethal complication. *J Vasc Surg* 2004 May;39(5):931-6.  
<http://www.ncbi.nlm.nih.gov/pubmed/15111840>
153. Taneja M, Tan KT. Renal vascular injuries following nephron-sparing surgery and their endovascular management. *Singapore Med J* 2008 Jan;49(1):63-6.  
<http://www.ncbi.nlm.nih.gov/pubmed/18204772>
154. Inci K, Cil B, Yazici S, Peynircioglu B, et al. Renal artery pseudoaneurysm: complication of minimally invasive kidney surgery. *J Endourol* 2010 Jan;24(1):149-54.  
<http://www.ncbi.nlm.nih.gov/pubmed/19954351>

155. Perini S, Gordon RL, LaBerge JM, et al. Transcatheter embolisation of biopsy-related vascular injury in the transplant kidney: immediate and long-term outcome. *J Vasc Interv Radiol* 1998 Nov-Dec;9(6):1011-9.  
<http://www.ncbi.nlm.nih.gov/pubmed/9840051>
156. Nakatani T, Uchida J, Han YS, et al. Renal allograft arteriovenous fistula and large pseudoaneurysm. *Clin Transplant* 2003 Feb;17(1):9-12.  
<http://www.ncbi.nlm.nih.gov/pubmed/12588315>
157. Dorffner R, Thurnher S, Prokesch R, et al. Embolisation of iatrogenic vascular injuries of renal transplants: immediate and follow-up results. *Cardiovasc Intervent Radiol* 1998 Mar-Apr;21(2):129-34.  
<http://www.ncbi.nlm.nih.gov/pubmed/9502679>
158. Wang MQ, Xie CM, Wang ZP, et al. [Treatment of acquired arteriovenous fistulas with interventional minimally invasive techniques]. [Article in Chinese]. *Zhonghua Wai Ke Za Zhi* 2004 Jun 7;42(11):687-91.  
<http://www.ncbi.nlm.nih.gov/pubmed/15329261>
159. Morris CS, Bonnevie GJ, Najarian KE. Nonsurgical treatment of acute iatrogenic renal artery injuries occurring after renal artery angioplasty and stenting. *AJR Am J Roentgenol* 2001 Dec;177(6):1353-7.  
<http://www.ncbi.nlm.nih.gov/pubmed/11717082>

### 3. URETERAL TRAUMA

Ureteral trauma is relatively rare because the ureters are protected from injury by their small size, mobility, and the adjacent vertebrae, bony pelvis, and muscles. Iatrogenic ureteral trauma gives rise to the commonest cause of ureteral injury. It is seen in open, laparoscopic or endoscopic surgery and is often missed intraoperatively. Any trauma to the ureter may result in severe sequelae.

#### 3.1 Aetiology

Overall, ureteral trauma accounts for 1-2.5% of urinary tract trauma (1-3). This incidence is even higher in modern combat injuries (4). Penetrating external ureteral trauma, mainly caused by gunshot wounds, dominates most of the modern series, both civilian and military (1,2,5). About one-third of cases of external trauma to the ureters are caused by blunt trauma, mostly MVAs (3).

Ureteral injury should be suspected in all cases of penetrating abdominal injury, especially gunshot wounds, because it occurs in 2-3% of cases (1). It should also be suspected in blunt trauma with deceleration mechanism, when the renal pelvis can be torn away from the ureter (1). In external ureteral trauma, the relative frequency of injury site in the ureter varies between series, but it is more common in the upper ureter (2,3).

Gynaecological operations are the commonest cause of iatrogenic trauma to the ureters (Table 5) and usually involve damage to the lower ureter (1,5-7). Ureteral damage may also be caused by colorectal operations, especially abdominoperineal resection and sigmoid colectomy, and urological operations, especially endoscopic surgery. With ureteroscopic procedures, most iatrogenic injuries are minor, though occasionally they can be serious, e.g. complete ureteral avulsion. The incidence of urological iatrogenic trauma has decreased in the last 20 years (5,8) due to improvements in technique, instruments and surgical experience. Iatrogenic ureteral trauma can result from various mechanisms: ligation or kinking with a suture, crushing from a clamp, partial or complete transection, thermal injury, or ischaemia from devascularisation (5,6,9).

Occult ureteral injury occurs more often than reported and not all injuries are diagnosed intraoperatively. In gynaecological surgery, if routine intraoperative cystoscopy is used, the detection rate of ureteral trauma is five times higher than usually reported (10,11). Risk factors for iatrogenic trauma include conditions that alter the normal anatomy, e.g. advanced malignancy, prior surgery or irradiation, diverticulitis, endometriosis, anatomical abnormalities, and major haemorrhage (5,11). Nevertheless, most cases have no identifiable risk factors (5,9,12).



**Table 5 – Incidence of ureteral injury in various procedures**

| Procedure                                      | Percentage % |
|--|--------------|
| Gynaecological (7,13,14)                       |              |
| Vaginal hysterectomy                           | 0.02 – 0.5   |
| Abdominal hysterectomy                         | 0.03 – 2.0   |
| Laparoscopic hysterectomy                      | 0.2 – 6.0    |
| Urogynaecological (anti-incontinence/prolapse) | 1.7 – 3.0    |
| Colorectal (9,15)                              | 0.3 - 10     |
| Ureteroscopy (8)                               |              |
| Mucosal abrasion                               | 0.3 – 4.1    |
| Ureteral perforation                           | 0.2 – 2.0    |
| Intussusception / avulsion                     | 0 – 0.3      |

### 3.2 Diagnosis

The diagnosis of ureteral trauma can be challenging. In penetrating external trauma, it is usually made intraoperatively during laparotomy (16), but it is delayed in most blunt trauma and iatrogenic cases (5,7,17). A high index of suspicion should be maintained.

#### 3.2.1 Clinical diagnosis

External ureteral trauma usually accompanies severe abdominal and pelvic injuries. Penetrating trauma is usually associated with vascular and intestinal injuries, while blunt trauma is associated with damage to the pelvic bones and lumbosacral spine injuries (3). Haematuria is unreliable and a poor indicator of ureteral injury, as it is present in only 50-75% of patients (1,5,18).

Iatrogenic injury may be noticed during the primary procedure, when intravenous dye (e.g. indigo carmine) may be injected to exclude ureteral injury. It may also be noticed later, when it is typically discovered by subsequent evidence of upper tract obstruction, urinary fistulae formation or sepsis.

The following clinical signs are characteristic of delayed diagnosis: flank pain, urinary incontinence, vaginal or drain urinary leakage, haematuria, fever, uraemia or urinoma.

When the diagnosis is missed, the complication rate increases (1,4,17). Early recognition facilitates immediate repair and provides better outcome. Delayed diagnosis predisposes the patient to pain, infection and renal damage (14).

#### 3.2.2 Radiological diagnosis

Extravasation of contrast medium in computerised tomography (CT) or in IVP is the hallmark sign of ureteral trauma. However, it is often only hydronephrosis, ascites, urinoma or mild ureteral dilation that are noticed. In unclear cases, a retrograde or antegrade urography is the gold standard for confirmation (5). Intravenous pyelography, especially one-shot IVP, is unreliable in diagnosis, as it is negative in up to 60% of patients (1,5). With the increasing use of CT scanning in polytrauma patients, the diagnosis of external ureteral trauma is increasingly made radiographically before the clinical signs.

### 3.3 Prevention of iatrogenic trauma

The prevention of iatrogenic trauma to the ureters depends upon the visual identification of the ureters and careful intraoperative dissection in their proximity (5,6,9). The use of prophylactic preoperative ureteral stent insertion assists in visualisation and palpation and is often used in complicated cases. However, it does not decrease the rate of injury (5). Apart from its evident disadvantages (potential complications and cost), a stent may alter the location of the ureter and diminish its flexibility (6,15). Stenting is probably also useful in secondary prevention by making it easier to detect ureteral injury (6). Routine prophylactic stenting is generally not cost-effective (6). In hysterectomy, it was estimated to become cost-effective when the rate of injury exceeded 3.2% (11), and it is therefore advocated only in selected patients with risk factors (15).

Another form of secondary prevention is intraoperative cystoscopy after intravenous dye injection, which can provide confirmation of ureteral patency (7). Routine cystoscopy has minimal risks and markedly increases the rate of ureteral injury detection (10). However, there are significant costs to its universal use. It has been estimated to be cost-saving for benign gynaecological operations with a threshold of injury above the rate of 1.5-2% (7).

### 3.4 Management

Management of a ureteral trauma depends on many factors concerning the nature, severity and location of

the injury. Immediate diagnosis of a ligation injury during an operation can be managed by de-ligation and stent placement. Partial injuries can be repaired immediately with a stent or urine diversion by a nephrostomy tube. Stenting may be helpful because it provides canalisation and may decrease the risk of stricture (5). On the other hand, its insertion has to be weighed against potentially aggravating the ureteral injury. Immediate repair of ureteral injury is usually advisable. However, in cases of unstable trauma patients, a 'damage control' approach is preferred with ligation of the ureter, diversion of the urine (e.g. by a nephrostomy), and a delayed definitive repair.

Injuries that are diagnosed late are usually treated first by a nephrostomy tube with or without a stent (5). Retrograde stenting is often unsuccessful in this setting.

The endourological treatment of small ureteral fistulae and strictures is safe and effective in selected cases (19), but an open surgical repair is often necessary. Laparoscopic and robotic repairs of ureteral injuries are increasingly common in the literature (20). The basic principles for any surgical repair of a ureteral injury are outlined in Table 6, while the various options for surgical reconstruction are given in Table 3. Proximal and mid-ureteral injuries can often be managed by primary uretero-ureterostomy, while a distal injury is often treated with ureteral reimplantation. Wide debridement is highly recommended for gunshot wound injuries due to the 'blast effect' of the injury.

**Table 6 – Principles of surgical repair of ureteral injury**

| Principles of surgical repair of ureteral injury                |
|---|
| Debridement of necrotic tissue                                  |
| Spatulation of ureteral ends                                    |
| Watertight mucosa-to-mucosa anastomosis with absorbable sutures |
| Internal stenting   |
| External drain  |
| Isolation of injury with peritoneum or omentum                  |

**Table 7 – Reconstruction option by site of injury**

| Site of injury | Reconstruction options  |
|----------------|---|
| Upper ureter   | Uretero-ureterostomy<br>Transuretero-ureterostomy<br>Uretero-calycostomy                      |
| Mid ureter     | Uretero-ureterostomy<br>Transuretero-ureterostomy<br>Ureteral reimplantation and a Boari flap |
| Lower ureter   | Ureteral reimplantation<br>Ureteral reimplantation with a psoas hitch                         |
| Complete       | Ileal interposition graft<br>Autotransplantation  |

#### 3.4.1 **Uretero-ureterostomy**

A uretero-ureterostomy is the most common repair performed (1), usually in the upper and mid-ureter.

#### 3.4.2 **Uretero-calycostomy**

In pelvic-ureteral junction or upper ureteral injury, the ureter can be anastomosed to a lower pole calyx of the ipsilateral kidney.

#### 3.4.3 **Transuretero-ureterostomy**

The distal end of the injured ureter is ligated. The proximal end is transposed across the midline through a retroperitoneal window and anastomosed to the contralateral ureter. This is a valid option in extensive ureteral loss or when pelvic injuries preclude ureteral reimplantation.

#### 3.4.4 **Ureteral reimplantation with a psoas hitch**

Distal ureteral injuries are best managed by ureteral reimplantation because the primary trauma usually jeopardises the blood supply to the distal ureter. The question of refluxing vs. non-refluxing ureteral reimplantation remains unresolved in the literature. The risk for clinically significant reflux should be weighed against the risk for ureteral obstruction.

A psoas hitch with non-absorbable sutures between the bladder and the ipsilateral psoas tendon is usually needed to bridge the gap and to protect the anastomosis from tension. It is important to avoid the genitofemoral nerve. The contralateral superior vesical pedicle may be divided to improve bladder mobility.

**3.4.5 Ureteral reimplantation with a Boari flap**

In extensive mid-lower ureteral injury, the large gap can be bridged with a tubularised L-shaped bladder flap. It is a time-consuming operation and not usually suitable in the acute setting.

**3.4.6 Ileal interposition graft**

If it is necessary to replace the entire ureter or a long ureteral segment, the ureter can be replaced using a segment of the intestines, usually the ileum. This should be avoided in patients with impaired renal function or known intestinal disease. The ileal segment is placed in the isoperistaltic orientation between the renal pelvis and the bladder. Follow-up should include serum chemistry to diagnose hyperchloremic metabolic acidosis (21). A review of long-term complications reported complication rates of 3% anastomotic stricture and 6% fistulae (22).

**3.4.7 Autotransplantation**

In cases of extensive ureteral loss or after multiple attempts at ureteral repair, the kidney can be relocated to the pelvis. The renal vessels are anastomosed to the iliac vessels and a ureteral reimplantation is performed (23).

**3.5 Statements and recommendations on ureteral trauma**

| Statements  | LE |
|---|----|
| Iatrogenic ureteral trauma gives rise to the commonest cause of ureteral injury.  | 3  |
| Gunshot wounds account for the majority of penetrating ureteral trauma, while motor vehicle accidents account for most of blunt injuries. | 3  |
| Ureteral trauma usually accompanies severe abdominal and pelvic injuries.   | 3  |
| Hematuria is unreliable and a poor indicator of ureteral injury.  | 3  |
| The diagnosis of ureteral trauma is often delayed.  | 2  |
| Preoperative prophylactic stents do not prevent ureteral injury, but may assist in its detection.   | 2  |
| Endourological treatment of small ureteral fistulae and strictures is safe and effective.   | 3  |
| Major ureteral injury require ureteral reconstruction following temporary urinary diversion.  | 3  |

| Recommendations   | GR |
|---|----|
| Visual identification of the ureters and meticulous dissection in their vicinity are mandatory to prevent ureteral trauma during abdominal and pelvic surgery.                      | A* |
| High level of suspicion for ureteral injury should be maintained in all abdominal penetrating trauma, and in deceleration-type blunt trauma.  | A* |
| Preoperative prophylactic stents do not prevent ureteral injury and therefore it is recommended that it be used in selected cases (based on risk factors and surgeon's experience). | B  |

\*upgraded following panel consensus

**3.6 References**

- Elliott SP, McAninch JW. Ureteral injuries: external and iatrogenic. Urol Clin North Am 2006 Feb;33(1):55-66.  
<http://www.ncbi.nlm.nih.gov/pubmed/16488280>
- Pereira BM, Ogilvie MP, Gomez-Rodriguez JC, et al. A review of ureteral injuries after external trauma. Scand J Trauma Resusc Emerg Med 2010 Feb 3;18:6.  
<http://www.ncbi.nlm.nih.gov/pubmed/20128905>
- Siram SM, Gerald SZ, Greene WR, et al. Ureteral trauma: patterns and mechanisms of injury of an uncommon condition. Am J Surg 2010 Apr;199(4):566-70.  
<http://www.ncbi.nlm.nih.gov/pubmed/20359576>
- Serkin FB, Soderdahl DW, Hernandez J, et al. Combat urologic trauma in US military overseas contingency operations. J Trauma 2010 Jul;69 Suppl 1:S175-8.  
<http://www.ncbi.nlm.nih.gov/pubmed/20622614>
- Brandes S, Coburn M, Armenakas N, et al. Diagnosis and management of ureteric injury: an evidence based analysis. BJU Int 2004 Aug;94(3):277-89.  
<http://www.ncbi.nlm.nih.gov/pubmed/15291852>

6. Chou MT, Wang CJ, Lien RC. Prophylactic ureteral catheterization in gynecologic surgery: a 12-year randomized trial in a community hospital. *Int Urogynecol J Pelvic Floor Dysfunct* 2009 Jun;20(6): 689-93.  
<http://www.ncbi.nlm.nih.gov/pubmed/19165412>
7. Visco AG, Taber KH, Weidner AC, et al. Cost-effectiveness of universal cystoscopy to identify ureteral injury at hysterectomy. *Obstet Gynecol* 2001 May;97(5 Pt 1):685-92.  
<http://www.ncbi.nlm.nih.gov/pubmed/11339916>
8. Johnson DB, Pearle MS. Complications of ureteroscopy. *Urol Clin North Am* 2004 Feb;31(1):157-71.  
<http://www.ncbi.nlm.nih.gov/pubmed/15040412>
9. Delacroix SE Jr, Winters JC. Urinary tract injuries: recognition and management. *Clin Colon Rectal Surg* 2010 Jun;23(2):104-12.  
<http://www.ncbi.nlm.nih.gov/pubmed/21629628>
10. Gilmour DT, Das S, Flowerdew G. Rates of urinary tract injury from gynecologic surgery and the role of intraoperative cystoscopy. *Obstet Gynecol* 2006 Jun;107(6):1366-72.  
<http://www.ncbi.nlm.nih.gov/pubmed/16738165>
11. Schimpf MO, Gottenger EE, Wagner JR. Universal ureteral stent placement at hysterectomy to identify ureteral injury: a decision analysis. *BJOG* 2008 Aug;115(9):1151-8.  
<http://www.ncbi.nlm.nih.gov/pubmed/18518875>
12. Vakili B, Chesson RR, Kyle BL, et al. The incidence of urinary tract injury during hysterectomy: a prospective analysis based on universal cystoscopy. *Am J Obstet Gynecol* 2005 May;192(5): 1599-604.  
<http://www.ncbi.nlm.nih.gov/pubmed/15902164>
13. De Cicco C, Ret Davalos ML, Van Cleynenbreugel B, et al. Iatrogenic ureteral lesions and repair: a review for gynecologists. *J Minim Invasive Gynecol* 2007 Jul-Aug;14(4):428-35.  
<http://www.ncbi.nlm.nih.gov/pubmed/17630159>
14. Wu HH, Yang PY, Yeh GP, et al. The detection of ureteral injuries after hysterectomy. *J Minim Invasive Gynecol* 2006 Sep-Oct;13(5):403-8.  
<http://www.ncbi.nlm.nih.gov/pubmed/16962522>
15. Pokala N, Delaney CP, Kiran RP, et al. A randomized controlled trial comparing simultaneous intra-operative vs sequential prophylactic ureteric catheter insertion in re-operative and complicated colorectal surgery. *Int J Colorectal Dis* 2007 Jun;22(6):683-7.  
<http://www.ncbi.nlm.nih.gov/pubmed/17031654>
16. Kunkle DA, Kansas BT, Pathak A, et al. Delayed diagnosis of traumatic ureteral injuries. *J Urol* 2006 Dec;176(6 Pt 1):2503-7.  
<http://www.ncbi.nlm.nih.gov/pubmed/17085143>
17. Parpala-Sparman T, Paananen I, Santala M, et al. Increasing numbers of ureteric injuries after the introduction of laparoscopic surgery. *Scand J Urol Nephrol* 2008;42(5):422-7.  
<http://www.ncbi.nlm.nih.gov/pubmed/18609278>
18. Medina D, Lavery R, Ross SE, et al. Ureteral trauma: preoperative studies neither predict injury nor prevent missed injuries. *J Am Coll Surg* 1998 Jun;186(6):641-4.  
<http://www.ncbi.nlm.nih.gov/pubmed/9632150>
19. Koukouras D, Petsas T, Liatsikos E, et al. Percutaneous minimally invasive management of iatrogenic ureteral injuries. *J Endourol*. 2010 Dec;24(12):1921-7.  
<http://www.ncbi.nlm.nih.gov/pubmed/20964484>
20. De Cicco C, Ussia A, Koninckx PR. Laparoscopic ureteral repair in gynaecological surgery. *Curr Opin Obstet Gynecol* 2011 Aug;23(4):296-300.  
<http://www.ncbi.nlm.nih.gov/pubmed/21734501>
21. Chung BI, Hamawy KJ, Zinman LN, et al. The use of bowel for ureteral replacement for complex ureteral reconstruction: long-term results. *J Urol* 2006 Jan;175(1):179-83; discussion 183-4.  
<http://www.ncbi.nlm.nih.gov/pubmed/16406903>
22. Armatys SA, Mellon MJ, Beck SD, et al. Use of ileum as ureteral replacement in urological reconstruction. *J Urol* 2009 Jan;181(1):177-81.  
<http://www.ncbi.nlm.nih.gov/pubmed/19013597>
23. Meng MV, Freise CE, Stoller ML. Expanded experience with laparoscopic nephrectomy and autotransplantation for severe ureteral injury. *J Urol* 2003 Apr;169(4):1363-7.  
<http://www.ncbi.nlm.nih.gov/pubmed/12629362>

## 4. BLADDER TRAUMA

### 4.1 Background, incidence and aetiology

#### 4.1.1 External (non-iatrogenic) trauma

Motor vehicle traffic collisions are the most common cause of bladder rupture by blunt trauma (1-6). Falls, industrial trauma/pelvic crush injuries and blows to the lower abdomen are other important causes (1,3,7).

- 60-90% of patients with bladder injuries caused by blunt trauma have associated pelvic fractures (1,3,7), and 44% of patients with bladder injuries have at least 1 other intra-abdominal injury (8).
- According to the U.S. National Trauma Data Bank, pelvic fractures are associated with bladder injuries in only 3.58% of cases (5).
- The majority of ruptures are extraperitoneal, followed by intraperitoneal ruptures and combined intra- and extraperitoneal ruptures (1,3,6-8).
- Combination of bladder and urethral injury is present in about 15% of cases (3,7).

Intraperitoneal ruptures are caused by a sudden rise in intravesical pressure, secondary to a blow to the pelvis or lower abdomen. Because the bladder dome is the weakest and most mobile point of the bladder, ruptures will usually occur at that site with disruption of the peritoneal surface and concomitant urinary extravasation (3,7).

Extraperitoneal ruptures are almost always associated with pelvic fractures (1). The bladder injury is usually caused by distortion of the pelvic ring with shearing of the anterolateral bladder wall near the bladder base (at its fascial attachments) or by a “counter-coup” bursting opposite the fracture site. Occasionally, the bladder is directly perforated by a sharp bony fragment (3,7,9).

#### 4.1.2 Iatrogenic trauma

The bladder is the urologic organ most often subject to iatrogenic injury (10). Iatrogenic bladder trauma (IBT) is defined as full-thickness laceration. Table 8 shows the incidence of bladder perforation during various procedures.

**Table 8: Incidence of bladder perforation during various procedures**

| Procedure                                  | Percentage % |
|--|--------------|
| <i>External</i>                            |              |
| Obstetrics                                 |              |
| Caesarean delivery (11,12)                 | 0.0016–0.94  |
| Gynaecology                                |              |
| Laparoscopic sterilisation (3)             | 0.02         |
| Diagnostic laparoscopy (3)                 | 0.01         |
| laparoscopic hysterectomy (13,14) (benign) | 0.5–2.0      |
| Vaginal hysterectomy (13,14) (benign)      | 0.44–6.3     |
| Abdominal hysterectomy (13,14) (benign)    | 0.73–2.5     |
| General surgery                            |              |
| Inguinal canal surgery (3,15)              | 0.08–0.3     |
| Tunnelling of synthetic bypass grafts (16) | Case reports |
| Urology                                    |              |
| Retropubic male sling (17)                 | 8.0–50       |
| Laparoscopic sacrocolpopexy (18)           | 1.9          |
| Burch colposuspension (19,20)              | 1.0–1.2      |
| Synthetic midurethral slings (all) (19,20) | 6.0–6.6      |
| Transobturator route (19,21)               | 0–2.4        |
| Retropubic route (19,20)                   | 3.2–8.5      |
| Pubovaginal sling (19)                     | 2.8          |
| Transvaginal mesh surgery (22,23)          | 1.5–3.5      |
| Anterior colporrhaphy (22)                 | 0.5          |
| <i>Internal</i>                            |              |
| TURB (24-28)                               | 1.3–58       |
| TURP (3)                                   | 0.01         |
| Cystography (29)                           | Case reports |

*TURB = transurethral resection of the bladder; TURP = transurethral resection of the prostate.*

External IBT mostly occurs during obstetric and gynaecologic procedures, followed by general surgical and urologic interventions (10).

Internal IBT mainly occurs during transurethral resection of the bladder (TURB) for the treatment of tumours. Large perforations requiring intervention are rare (0.16–0.57%) (30). Extraperitoneal perforations are more frequent than intraperitoneal ones.

*Iatrogenic foreign body inside the bladder* can be caused by failure of the resectoscope, ureteric stents, bladder catheters, forgotten pieces of surgical gauze, sutures, or staples used in pelvic procedures (31,32), unrecognised perforation or erosion of mesh for urinary incontinence or pelvic organ prolapse (31).

## 4.2 Risk factors

Individuals who are driving under the influence of alcohol are more likely to have a distended bladder and an MVA. Driving after drinking alcohol is therefore a risk factor for bladder injury (33) (LE: 3). A full bladder is a risk factor for intraperitoneal ruptures (3,4,7).

The highest risk of bladder injury in pelvic fracture was found in disruptions of the pelvic circle with displacement > 1cm, diastasis of the pubic symphysis > 1cm and fractures of the rami pubis (5,6). An Isolated acetabular fracture is not likely to be associated with bladder injury (6).

Risk factors for IBT are shown in table 9.

**Table 9: Risk factors for IBT associated with various procedures**

| Procedure                                  | Risk factors  |
|--|---|
| Caesarean delivery (11,12)                 | Previous caesarean delivery   |
|  | Previous pelvic surgery   |
|  | Presence of labour  |
|  | Station of presenting foetal part $\geq + 1$                                |
|  | Foetal weight > 4 kg  |
| Hysterectomy (14,34)                       | Malignancy  |
|  | Endometriosis   |
|  | Prior pelvic surgery  |
|  | Concomitant anti-incontinence or pelvic organ prolapse surgery              |
| General surgery (10)                       | Malignancy  |
|  | Diverticulitis  |
|  | Inflammatory bowel disease  |
| Midurethral sling operations (19,21,35,36) | Retropubic route  |
|  | Previous caesarean delivery   |
|  | Previous colposuspension  |
|  | BMI < 30 kg/m <sup>2</sup>  |
|  | Rectocele   |
|  | Procedures under local anaesthesia  |
| TURB (37,38,24-26,30)                      | Inexperienced surgeon   |
|  | Tumour size   |
|  | Elderly patients  |
|  | Pretreated bladder (previous TURB, intravesical instillation, radiotherapy) |
|  | Tumour location at the dome or in diverticulum                              |

BMI = body mass index; TURB = transurethral resection of the bladder.

## 4.3 Clinical signs and symptoms

### 4.3.1 External trauma

Clinical presentation of bladder injury might be blurred by associated pelvic fracture, visceral and/or vascular injuries (3).

The cardinal sign of bladder injury is gross haematuria, present in 82-95% of patients (1,4,7,39). The presence of bladder injury is strongly correlated with the combination of pelvic fracture and gross haematuria (40). Thus, the classic combination of pelvic fracture and gross haematuria constitutes an absolute indication for further imaging of the bladder (3,7,39,40) (LE: 3). Approximately 5-15% of patients with bladder rupture only

have microhaematuria (6). Existing data do not support lower urinary tract imaging in all patients with pelvic fracture or microscopic haematuria alone. In case of gross haematuria without pelvic fracture, microhaematuria with pelvic fracture and isolated microhaematuria, the decision for further imaging should be based on the presence of other clinical signs and symptoms and the site of maximal trauma (3,7).

Other signs and symptoms are abdominal tenderness (up to 97%) (1), inability to void, bruises over the suprapubic region, and abdominal distension (in case of urinary ascites) (3,4,7,41).

Extravasation of urine may result in swelling in the perineum, scrotum (through the inguinal canal), and thighs, as well as along the anterior abdominal wall within the potential space between the transversalis fascia and the parietal peritoneum (3,7).

In case of intraperitoneal rupture, reabsorption of urea nitrogen and creatinine through the peritoneal cavity causes uraemia and elevated creatinine levels (3,7).

In penetrating abdominal trauma, location of entrance and exit wounds at the lower abdomen, perineum or buttocks should raise suspicion of bladder injury (3,4).

Severe bladder injuries may be accompanied with soft tissue avulsion of the lower abdominal wall and/or perineum, as well as by bladder tissue loss due to trauma or infection (42).

**CAUTION:** in case of urinary retention and/or bloody urethrorrhagy, a (concomitant) urethral injury must be suspected and a retrograde urethrography must be performed to assess the integrity of the urethra, before further manipulation of the urethra (e.g. urinary catheter for a cystography) (3,43).

#### **4.3.2 Iatrogenic trauma**

##### **4.3.2.1 Perioperative: external iatrogenic bladder trauma**

Direct inspection is the most reliable method of assessing bladder integrity. Suggestive signs are extravasation of urine, visible laceration, clear fluid in the surgical field, appearance of the bladder catheter, and blood and/or gas in the urine bag during laparoscopy (3,11,12). Intravesical instillation of methylene blue may be helpful (3,11,44). If bladder perforation is present, the integrity of the ureteric orifices should be checked (3,44).

##### **4.3.2.2 Perioperative: internal iatrogenic bladder trauma**

Fatty tissue, a dark space between detrusor muscle fibres, or the visualisation of bowel suggests perforation (24). Signs of major perforation are the inability to distend the bladder, a low return of irrigation fluid, and abdominal distension (26,28,45,46).

##### **4.3.2.3 Postoperative: unrecognised bladder injury**

Clinical signs and symptoms include haematuria, lower abdominal pain, abdominal distension, ileus, peritonitis, sepsis, urine leakage from the wound, decreased urinary output, and increased serum creatinine (3,28,44,46-48).

#### **4.3.3 Intravesical foreign body**

Symptoms of an intravesical foreign body include dysuria, recurrent urinary tract infection, frequency, urgency, haematuria, and perineal/pelvic pain (31,32,49-51). Bladder calculi usually develop once the foreign body has been present > 3 mo (32,49,52).

### **4.4 Imaging**

#### **4.4.1 Cystography (conventional or CT)**

Cystography is the preferred diagnostic modality for non-iatrogenic bladder injury and in case of suspicion of a iatrogenic bladder injury in the postoperative setting (3,4,7,9,53,54). Although both conventional and CT cystography have a comparable sensitivity and specificity of respectively 90-95 and 100%(1,55), CT cystography has the advantage of diagnosing other injuries or causes of abdominal pain (1,3,53). CT or conventional cystography must be performed using slow retrograde filling of the bladder with a minimum of 350 mL of dilute contrast material (9). A plain film, a complete filling film and a post-drainage film is the absolute minimum during conventional cystography (9). With CT cystography, 3D reconstruction is helpful in delineating the location of bladder rupture and makes a postdrainage series unnecessary (56).

With intraperitoneal extravasation, free contrast medium is visualised in the abdomen, highlighting bowel loops and/or outlining abdominal viscera such as the liver (3,48). Extraperitoneal bladder injury is associated with flame-shaped areas of contrast extravasation in the perivesical soft tissues (3).

#### **4.4.2 Cystoscopy**

Cystoscopy is the preferred method to detect intra-operative bladder injuries. Routine postoperative cystoscopy after gynaecological procedures remains controversial, but it is recommended for all procedures where bladder injury is suspected (34). Vakili et al. reported that 64.7% of bladder injuries during hysterectomy

were not detected before cystoscopy and therefore, they advise the routine use of cystoscopy after hysterectomy and every major gynaecological procedure (14).

Cystoscopy is recommended after minimally invasive synthetic suburethral sling operations by retropubic route to detect any perforation of the bladder (or urethra) (20,35,57). During cystoscopy, the bladder must be adequately distended and a 70° optic or a flexible cystoscope must be used to inspect areas close to the bladder neck (31,49,58-60). The use of routine cystoscopy for insertion by obturator route is controversial as bladder injuries are rare but not impossible (20,21,36,49,57,61). Cystoscopy after transvaginal mesh procedures is preferable but not mandatory (62).

Cystoscopy with adequate distension of the bladder may directly visualise the laceration and is able to correlate the lesion with the position of the trigone and ureteral orifices (48). Inability of bladder distension during cystoscopy suggests a large perforation. Cystoscopy is the preferred examination method in case of suspicion of a iatrogenic foreign body (32,49,50,63,64).

#### 4.4.3 **Excretory phase of CT or IVP**

Passive bladder filling by clamping the urinary catheter during the excretory phase of CT or IVP is insufficient to rule out bladder injury (1,3,7,9). However, the finding of contrast extravasation during the excretory phase is suggestive of bladder injury.

#### 4.4.4 **Ultrasound**

Intraperitoneal fluid or an extraperitoneal collection suggests intraperitoneal or extraperitoneal perforation, respectively. Ultrasound alone is insufficient in the diagnosis of bladder trauma (3).

### 4.5 **Treatment**

If operative bladder repair is performed, the preferred method is two-layer vesicorrhaphy (mucosa-detrusor) with absorbable sutures (3,7,11,12,34).

#### 4.5.1 **External trauma**

##### 4.5.1.1 *Blunt trauma: extraperitoneal rupture*

Most patients with uncomplicated extraperitoneal rupture can be managed safely by catheter drainage alone, even in the presence of extensive retroperitoneal or scrotal extravasation (3,4,7,8) (LE: 3). However, bladder neck involvement, the presence of bone fragments in the bladder wall, concomitant rectal injury or entrapment of the bladder wall will necessitate surgical intervention (3,4,7,33) (LE: 3).

In orthopaedic surgery, there is an increasing trend to treat pelvic ring fractures with open stabilisation and internal fixation with osteosynthetic material. In order to prevent infection of this osteosynthetic material, there is also an increasing interest to suture an extraperitoneal rupture (1,3,7). In case of surgical exploration for other injuries, an extraperitoneal rupture should be sutured concomitantly in order to reduce infective complications (especially paravesical abscess) (1,3,7,8).

##### 4.5.1.2 *Blunt trauma: intraperitoneal rupture*

Intraperitoneal ruptures occurring after blunt trauma should always be managed by formal surgical repair (1,3,4,7) (LE: 3). The rationale for this is that intraperitoneal extravasation of urine can lead to peritonitis, intra-abdominal sepsis and death (8).

Abdominal organs should be inspected for possible associated injuries and urinoma must be drained, if present. In the absence of other intra-abdominal injuries, laparoscopic suturing of the intraperitoneal rupture is possible (1).

##### 4.5.1.3 *Penetrating injuries*

All bladder perforations resulting from penetrating trauma should undergo emergency exploration, debridement of devitalised bladder muscle and subsequent bladder repair (3,4,7) (LE: 3). A midline exploratory cystotomy is advised to inspect the bladder wall and distal ureters (3,7).

##### 4.5.1.4 *Bladder injuries with avulsion of lower abdominal wall or perineum and/or bladder tissue loss*

In these cases, direct closure of the traumatised bladder will lead to excessive tension, resulting in ischemia and eventual break-down of the repair. Therefore, a bladder wall substitute is needed for the repair of bladder defects as well as a substitute to restore the lower abdominal wall or perineum. Use of a pedicled vastus lateralis myocutaneous flap has been reported for posttraumatic bladder reconstruction and soft-tissue coverage for the lower abdomen or perineum (42).



#### 4.5.2 Iatrogenic injuries

Perforations recognised intraoperatively are primarily closed. For bladder injuries not recognised during surgery or for internal injuries, a distinction must be made between intraperitoneal and extraperitoneal injuries. For intraperitoneal injuries, the standard of care is surgical exploration with repair (3,48). In selected cases (in the absence of peritonitis or ileus), conservative management with continuous bladder drainage and antibiotic prophylaxis may be offered (3,48). In addition to this conservative treatment, placement of an intraperitoneal drain has been advocated, especially when the lesion is larger (26, 46, 65) . If surgical exploration is performed after TURB, meticulous bowel inspection is required to rule out concomitant injury (30).

For extraperitoneal injuries, conservative treatment with bladder drainage and antibiotic prophylaxis is advised (3,7,25,27,28). Large extraperitoneal perforations complicated by symptomatic extravescical collections require drainage, with or without closure of the perforation (28).

If perforation occurs during TURB, immediate intravesical instillation with chemotherapeutic agents should not be performed (66). If bladder perforation is encountered during midurethral sling or transvaginal mesh procedures, sling reinsertion and urethral catheterisation (1–2 d) should be performed (36).

#### 4.5.3 Intravesical foreign body

For perforated or eroded meshes, the intravesical portion must be removed by open cystotomy or endoscopically (49–52, 60,62,63). The choice depends on the surgeon's level of experience and the location of the mesh (49,51). For other types of foreign body, cystoscopic removal is performed or a cystotomy if that fails (32).

#### 4.5.4 Postoperative management

Postoperative continuous bladder drainage is required to allow the bladder to heal and to prevent elevated intravesical pressure and disruption of the suture line (34). For external trauma and external iatrogenic bladder injuries, the bladder catheter is maintained for 7–14 days, depending on the extent of laceration (3,7,11,34). Cystography upon removal of the catheter is advised. In case of contrast extravasation, continuous bladder drainage is maintained for at least one week and until cystography shows no longer extravasation (3,34). For conservatively treated internal iatrogenic bladder injuries, a catheter duration is proposed of 5 and 7 days for respectively extra- and intraperitoneal perforations (25) (LE: 3)

### 4.6 Recommendations

#### 4.6.1 Statements

Extraperitoneal bladder perforations are more frequent than intraperitoneal perforations (LE: 3).

*Risk of bladder perforation during midurethral sling operations for stress urinary incontinence is lower for the obturator route compared to the retropubic route (LE 1a).*

The combination of pelvic fracture and gross haematuria is highly suggestive of bladder injury.

Cystography should be performed with gentle filling of the bladder with at least 350 mL of dilute contrast. Passive bladder filling by clamping the catheter during the excretory phase of CT or IVP is insufficient for diagnosis.

#### 4.6.2 Recommendations

|   | GR |
|---|----|
| Cystography is the preferred diagnostic modality for non-iatrogenic bladder injury and in case of suspicion of a iatrogenic bladder injury in the postoperative setting.  | B  |
| Cystography, conventional or computed tomography, is required in the presence of gross haematuria and pelvic fracture.  | B  |
| Cystoscopy is recommended after suburethral sling operations via the retropubic route and major gynaecologic operations and is optional after any other type of sling procedure or transvaginal mesh procedure. | B  |
| In the absence of bladder neck involvement and/or associated injuries that require surgical. Intervention, extraperitoneal bladder ruptures caused by blunt trauma are managed conservatively.                  | B  |
| Intraperitoneal bladder ruptures by blunt trauma, and any type of bladder injury by penetrating trauma, must be managed by emergency surgical exploration and repair.   | B  |
| Conservative management is an option for small uncomplicated iatrogenic intraperitoneal bladder perforations.   | C  |

#### 4.7 References

1. Wirth GJ, Peter R, Poletti PA, et al. Advances in the management of blunt traumatic bladder rupture: experience with 36 cases. *BJU Int* 2010 Nov;106(9):1344-9.  
<http://www.ncbi.nlm.nih.gov/pubmed/20438556>
2. Bjurlin MA, Goble SM, Fantus RJ, et al. Outcomes in geriatric genitourinary trauma. *J Am Coll Surg* 2011 Sep;213(3):415-21.  
<http://www.ncbi.nlm.nih.gov/pubmed/21723152>
3. Gomez RG, Ceballos L, Coburn M, et al. Consensus statement on bladder injuries. *BJU Int* 2004 Jul;94(1):27-32.  
<http://www.ncbi.nlm.nih.gov/pubmed/15217426>
4. Tonkin JB, Tisdale BE, Jordan GH. Assessment and initial management of urologic trauma. *Med Clin North Am* 2011 Jan;95(1):245-51.  
<http://www.ncbi.nlm.nih.gov/pubmed/21095427>
5. Bjurlin MA, Fantus RJ, Mellett MM, et al. Genitourinary injuries in pelvic fracture morbidity and mortality using the National Trauma Data Bank. *J Trauma* 2009 Nov;67(5):1033-9.  
<http://www.ncbi.nlm.nih.gov/pubmed/19901665>
6. Avey G, Blackmore CC, Wessells H, et al. Radiographic and clinical predictors of bladder rupture in blunt trauma patients with pelvic fracture. *Acad Radiol* 2006 May;13(5):573-9.  
<http://www.ncbi.nlm.nih.gov/pubmed/16627198>
7. Rödder K, Olianias R, Fisch M. [Bladder injury. Diagnostics and treatment]. *Urologe A* 2005 Aug;44(8):878-82. [Article in German].  
<http://www.ncbi.nlm.nih.gov/pubmed/15959610>
8. Deibert CM, Spencer BA. The association between operative repair of bladder injury and improved survival: results from the National Trauma Data Bank. *J Urol* 2011 Jul;186(1):151-5.  
<http://www.ncbi.nlm.nih.gov/pubmed/21575961>
9. Ramchandani P, Buckler PM. Imaging of genitourinary trauma. *AJR Am J Roentgenol* 2009 Jun;192(6):1514-23.  
<http://www.ncbi.nlm.nih.gov/pubmed/19457813>
10. Armenakas NA, Pareek G, Fracchia JA. Iatrogenic bladder perforations: longterm followup of 65 patients. *J Am Coll Surg* 2004 Jan;198(1):78-82.  
<http://www.ncbi.nlm.nih.gov/pubmed/14698314>
11. Gungorduk K, Asicioglu O, Celikkol O, et al. Iatrogenic bladder injuries during caesarean delivery: a case control study. *J Obstet Gynaecol* 2010;30(7):667-70.  
<http://www.ncbi.nlm.nih.gov/pubmed/20925606>
12. Rahman MS, Gasem T, Al Suleiman SA, et al. Bladder injuries during cesarean section in a University Hospital: a 25-year review. *Arch Gynecol Obstet* 2009 Mar;279(3):349-52.  
<http://www.ncbi.nlm.nih.gov/pubmed/18648828>
13. Donnez O, Jadoul P, Squifflet J, et al. A series of 3190 laparoscopic hysterectomies for benign disease from 1990 to 2006: evaluation of complications compared with vaginal and abdominal procedures. *BJOG* 2009 Mar;116(4):492-500.  
<http://www.ncbi.nlm.nih.gov/pubmed/19016683>
14. Vakili B, Chesson RR, Kyle BL, et al. The incidence of urinary tract injury during hysterectomy: a prospective analysis based on universal cystoscopy. *Am J Obstet Gynecol* 2005 May;192(5):1599-604.  
<http://www.ncbi.nlm.nih.gov/pubmed/15902164>
15. Aloï IP, Lais A, Caione P. Bladder injuries following inguinal canal surgery in infants. *Pediatr Surg Int* 2010 Dec;26(12):1207-10.  
<http://www.ncbi.nlm.nih.gov/pubmed/20820790>
16. Nakamura LY, Ferrigni RG, Stone WM, et al. Urinary bladder injuries during vascular surgery. *J Vasc Surg* 2010 Aug;52(2):453-5.  
<http://www.ncbi.nlm.nih.gov/pubmed/20541350>
17. Welk BK, Herschorn S. Are male slings for post-prostatectomy incontinence a valid option? *Curr Opin Urol* 2010 Nov;20(6):465-70.  
<http://www.ncbi.nlm.nih.gov/pubmed/20838219>
18. Maher CF, Feiner B, DeCuyper EM, et al. Laparoscopic sacral colpopexy versus total vaginal mesh for vaginal vault prolapse: a randomized trial. *Am J Obstet Gynecol* 2011 Apr;204(4):360.e1-7.  
<http://www.ncbi.nlm.nih.gov/pubmed/21306698>

19. Novara G, Artibani W, Barber MD, et al. Updated systematic review and meta-analysis of the comparative data on colposuspensions, pubovaginal slings, and midurethral tapes in the surgical treatment of female stress urinary incontinence. *Eur Urol* 2010 Aug;58(2):218-38.  
<http://www.ncbi.nlm.nih.gov/pubmed/20434257>
20. Ogah J, Cody DJ, Rogerson L. Minimally invasive synthetic suburethral sling operations for stress urinary incontinence in women: a short version Cochrane review. *Neurourol Urodyn* 2011 Mar;30(3):284-91.  
<http://www.ncbi.nlm.nih.gov/pubmed/21412819>
21. Long CY, Hsu CS, Wu MP, et al. Comparison of tension-free vaginal tape and transobturator tape procedure for the treatment of stress urinary incontinence. *Curr Opin Obstet Gynecol* 2009 Aug;21(4):342-7.  
<http://www.ncbi.nlm.nih.gov/pubmed/19528799>
22. Altman D, Väyrynen T, Engh ME, et al. Anterior colporrhaphy versus transvaginal mesh for pelvic-organ prolapse. *N Engl J Med* 2011 May 12;364(19):1826-36.  
<http://www.ncbi.nlm.nih.gov/pubmed/21561348>
23. Huang WC, Lin TY, Lau HH, et al. Outcome of transvaginal pelvic reconstructive surgery with Prolift after a median of 2 years' follow-up. *Int Urogynecol J* 2011 Feb;22(2):197-203.  
<http://www.ncbi.nlm.nih.gov/pubmed/20821308>
24. Balbay MD, Cimentepe E, Unsal A, et al. The actual incidence of bladder perforation following transurethral bladder surgery. *J Urol* 2005 Dec;174(6):2260-2, discussion 2262-3.  
<http://www.ncbi.nlm.nih.gov/pubmed/16280794>
25. El Hayek OR, Coelho RF, Dall'oglio MF, et al. Evaluation of the incidence of bladder perforation after transurethral bladder tumor resection in a residency setting. *J Endourol* 2009 Jul;23(7):1183-6.  
<http://www.ncbi.nlm.nih.gov/pubmed/19530900>
26. Collado A, Chechile GE, Salvador J, et al. Early complications of endoscopic treatment for superficial bladder tumors. *J Urol* 2000 Nov;164(5):1529-32.  
<http://www.ncbi.nlm.nih.gov/pubmed/11025697>
27. Nieder AM, Meinbach DS, Kim SS, et al. Transurethral bladder tumor resection: intraoperative and postoperative complications in a residency setting. *J Urol* 2005 Dec;174(6):2307-9.  
<http://www.ncbi.nlm.nih.gov/pubmed/16280830>
28. Traxer O, Pasqui F, Gattegno B, et al. Technique and complications of transurethral surgery for bladder tumours. *BJU Int* 2004 Sep;94(4):492-6.  
<http://www.ncbi.nlm.nih.gov/pubmed/15329099>
29. Khavari R, Bayne AP, Roth DR. A report of an iatrogenic bladder rupture in a normal healthy child during voiding cystourethrography. *Urology* 2010 Mar;75(3):684-6.  
<http://www.ncbi.nlm.nih.gov/pubmed/19716588>
30. Fazlioglu A, Tandogdu Z, Kurtulus FO, et al. Perivesical inflammation and necrosis due to mitomycin C instillation after transurethral resection of bladder tumor: we must be vigilant! *Urol Int* 2009;83(3):362-3.  
<http://www.ncbi.nlm.nih.gov/pubmed/19829042>
31. Tyritzis SI, Stravodimos KG, Mihalakis A, et al. Complications associated with primary and secondary perforation of the bladder following immediate instillations of epirubicin after transurethral resection of superficial urothelial tumours. *Int Urol Nephrol* 2009 Dec;41(4):865-8.  
<http://www.ncbi.nlm.nih.gov/pubmed/19266307>
32. Golan S, Baniel J, Lask D, et al. Transurethral resection of bladder tumour complicated by perforation requiring open surgical repair - clinical characteristics and oncological outcomes. *BJU Int* 2011 Apr;107(7):1065-8.  
<http://www.ncbi.nlm.nih.gov/pubmed/20860654>
33. Frenkl TL, Rackley RR, Vasavada SP, et al. Management of iatrogenic foreign bodies of the bladder and urethra following pelvic floor surgery. *Neurourol Urodyn* 2008;27(6):491-5.  
<http://www.ncbi.nlm.nih.gov/pubmed/18537142>
34. Rafique M. Intravesical foreign bodies: review and current management strategies. *Urol J* 2008 Fall;5(4):223-31.  
<http://www.ncbi.nlm.nih.gov/pubmed/19101894>
35. Dreitlein DA, Suner S, Basler J. Genitourinary trauma. *Emerg Med Clin North Am* 2001 Aug;19(3):569-90.  
<http://www.ncbi.nlm.nih.gov/pubmed/11554276>
36. Wohlrab KJ, Sung VW, Rardin CR. Management of laparoscopic bladder injuries. *J Minim Invasive Gynecol* 2011 Jan-Feb;18(1):4-8.  
<http://www.ncbi.nlm.nih.gov/pubmed/21195952>

37. Kristensen I, Eldoma M, Williamson T, et al. Complications of the tension-free vaginal tape procedure for stress urinary incontinence. *Int Urogynecol J* 2010 Nov;21(11):1353-7.  
<http://www.ncbi.nlm.nih.gov/pubmed/20577714>
38. Stav K, Dwyer PL, Rosamilia A, et al. Risk factors for trocar injury to the bladder during mid urethral sling procedures. *J Urol* 2009 Jul;182(1):174-9.  
<http://www.ncbi.nlm.nih.gov/pubmed/19450824>
39. Xishuang S, Deyong Y, Xiangyu C, et al. Comparing the safety and efficiency of conventional monopolar, plasmakinetic, and holmium laser transurethral resection of primary non-muscle invasive bladder cancer. *J Endourol* 2010 Jan;24(1):69-73.  
<http://www.ncbi.nlm.nih.gov/pubmed/1995435>
40. Gao X, Ren S, Xu C, et al. Thulium laser resection via a flexible cystoscope for recurrent non-muscle-invasive bladder cancer: initial clinical experience. *BJU Int* 2008 Nov;102(9):1115-8.  
<http://www.ncbi.nlm.nih.gov/pubmed/18565172>
41. Carroll PR, McAninch JW. Major bladder trauma: mechanisms of injury and a unified method of diagnosis and repair. *J Urol* 1984 Aug;132(2):254-7.  
<http://www.ncbi.nlm.nih.gov/pubmed/6737572>
42. Morey AF, Iverson AJ, Swan A, et al. Bladder rupture after blunt trauma: guidelines for diagnostic imaging. *J Trauma* 2001 Oct;51(4):683-6.  
<http://www.ncbi.nlm.nih.gov/pubmed/11586159>
43. Parker H, Hoonpongsimanont W, Vaca F, et al. Spontaneous bladder rupture in association with alcoholic binge: a case report and review of the literature. *J Emerg Med* 2009 Nov;37(4):386-9.  
<http://www.ncbi.nlm.nih.gov/pubmed/17976802>
44. Wu CW, Lin CH, Lin CH. One-stage posttraumatic bladder reconstruction and soft-tissue coverage of the lower abdomen or perineum. *Ann Plast Surg* 2010 Jan;64(1):65-8.  
<http://www.ncbi.nlm.nih.gov/pubmed/20023456>
45. Gallentine ML, Morey AF. Imaging of the male urethra for stricture disease. *Urol Clin North Am* 2002 May;29(2):361-72.  
<http://www.ncbi.nlm.nih.gov/pubmed/12371227>
46. Wohlrab KJ, Sung VW, Rardin CR. Management of laparoscopic bladder injuries. *J Minim Invasive Gynecol* 2011 Jan-Feb;18(1):4-8.  
<http://www.ncbi.nlm.nih.gov/pubmed/21195952>
47. Dorotta I, Basali A, Ritchey M, et al. Transurethral resection syndrome after bladder perforation. *Anesth Analg* 2003 Nov;97(5):1536-8.  
<http://www.ncbi.nlm.nih.gov/pubmed/14570683>
48. Manikandan R, Lynch N, Grills RJ. Percutaneous peritoneal drainage for intraperitoneal bladder perforations during transurethral resection of bladder tumors. *J Endourol* 2003 Dec;17(10):945-7.  
<http://www.ncbi.nlm.nih.gov/pubmed/14744369>
49. Golan S, Baniel J, Lask D, et al. Transurethral resection of bladder tumour complicated by perforation requiring open surgical repair - clinical characteristics and oncological outcomes. *BJU Int* 2011 Apr;107(7):1065-8.  
<http://www.ncbi.nlm.nih.gov/pubmed/20860654>
50. Alperin M, Mantia-Smaldone G, Sagan ER. Conservative management of postoperatively diagnosed cystotomy. *Urology* 2009 May;73(5):1163.e17-9.  
<http://www.ncbi.nlm.nih.gov/pubmed/18514295>
51. Foley C, Patki P, Boustead G. Unrecognized bladder perforation with mid-urethral slings. *BJU Int* 2010 Nov;106(10):1514-8.  
<http://www.ncbi.nlm.nih.gov/pubmed/20518762>
52. Shrotri KN, Shervington JP, Shrotri NC. Laser excision of encrusted intra-vesical tension-free vaginal tape (TVT). *Int Urogynecol J* 2010 Mar;21(3):375-7.  
<http://www.ncbi.nlm.nih.gov/pubmed/19603126>
53. Araco F, Gravante G, Piccione E. Bladder erosion after 2 years from cystocele repair with type I polypropylene mesh. *Int Urogynecol J Pelvic Floor Dysfunct* 2009 Jun;20(6):731-3.  
<http://www.ncbi.nlm.nih.gov/pubmed/18815720>
54. Arrabal-Polo MA, Arrabal-Martin M, Tinaut-Ranera J, et al. Bladder lithiasis on tension-free polypropylene tape after TVT technique. *Urol Res* 2010 Dec;38(6):519-21.  
<http://www.ncbi.nlm.nih.gov/pubmed/20221826>
55. Shenfeld OZ, Gnessin E. Management of urogenital trauma: state of the art. *Curr Opin Urol* 2011 Nov;21(6):449-54.  
<http://www.ncbi.nlm.nih.gov/pubmed/21897259>

56. Srinivasa RN, Akbar SA, Jafri SZ, et al. Genitourinary trauma: a pictorial essay. *Emerg Radiol* 2009 Jan;16(1):21-33.  
<http://www.ncbi.nlm.nih.gov/pubmed/18548297>
57. Quagliano PV, Delair SM, Malhotra AK. Diagnosis of blunt bladder injury: A prospective comparative study of computed tomography cystography and conventional retrograde cystography. *J Trauma* 2006 Aug;61(2):410-21; discussion 421-2.  
<http://www.ncbi.nlm.nih.gov/pubmed/16917459>
58. Chan DP, Abujudeh HH, Cushing GL Jr, et al. CT cystography with multiplanar reformation for suspected bladder rupture: experience in 234 cases. *AJR Am J Roentgenol* 2006 Nov;187(5):1296-302.  
<http://www.ncbi.nlm.nih.gov/pubmed/17056919>
59. Daneshgari F, Kong W, Swartz M. Complications of mid urethral slings: important outcomes for future clinical trials. *J Urol.* 2008 Nov;180(5):1890-7.  
<http://www.ncbi.nlm.nih.gov/pubmed/18801499>
60. Chang PL, Sokol ER. Alternative method of suprapubic assistance in operative cystoscopy. *Int Urogynecol J* 2010 Feb;21(2):247-9.  
<http://www.ncbi.nlm.nih.gov/pubmed/19543675>
61. George S, Begum R, Thomas-Philip A, et al. Two-year comparison of tension-free vaginal tape and transobturator tape for female urinary stress incontinence. *J Obstet Gynaecol* 2010 Apr;30(3):281-4.  
<http://www.ncbi.nlm.nih.gov/pubmed/20373932>
62. Bekker MD, Bevers RF, Elzevier HW. Transurethral and suprapubic mesh resection after Prolift bladder perforation: a case report. *Int Urogynecol J* 2010 Oct;21(10):1301-3.  
<http://www.ncbi.nlm.nih.gov/pubmed/20204325>
63. Maher C, Feiner B. Laparoscopic removal of intravesical mesh following pelvic organ prolapse mesh surgery. *Int Urogynecol J* 2011 Dec;22(12):1593-5.  
<http://www.ncbi.nlm.nih.gov/pubmed/21656318>
64. Chung E, Tse V, Chan L. Mid-urethral synthetic slings in the treatment of urodynamic female stress urinary incontinence without concomitant pelvic prolapse repair: 4-year health-related quality of life outcomes. *BJU Int* 2010 Feb;105(4):514-7.  
<http://www.ncbi.nlm.nih.gov/pubmed/19747354>
65. Pansadoro A, Franco G, Laurenti C, et al. Conservative treatment of intraperitoneal bladder perforation during transurethral resection of bladder tumor. *Urology* 2002 Oct;60(4):682-4.  
<http://www.ncbi.nlm.nih.gov/pubmed/12385934>
66. Babjuk M, Oosterlinck W, Sylvester R, et al. EAU guidelines on non-muscle-invasive urothelial carcinoma of the bladder, the 2011 update. *Eur Urol* 2011 Jun;59(6):997-1008.  
<http://www.ncbi.nlm.nih.gov/pubmed/21458150>

## 5 URETHRAL TRAUMA

### 5.1 Anterior urethral injuries

Anterior urethral injuries result from blunt trauma more frequently than from penetrating trauma (Table 10). Blunt trauma accounts for more than 90% of urethral injuries (1). In blunt trauma, the relatively immobile bulbar urethra is trapped and compressed by a direct force upon it, which then presses it against the inferior surface of the symphysis pubis. One of the mechanisms responsible for such an injury is 'fall-astride' or 'straddle' injury of the bulbar urethra (2-4).

A less common cause of blunt anterior urethral trauma is penile fracture. This type of rupture of the corpus cavernosum usually occurs during intercourse. In these injuries, the urethra is involved in 20% of the cases (5). Intraluminal stimulation of the urethra with foreign objects has also been reported to cause anterior urethral trauma.

Individuals with paraplegia, who use a constriction device for urinary incontinence and then forget to release the band because of the lack of sensation, can cause severe ischaemic injuries to themselves involving the penis and urethra.

Penetrating injuries to the anterior urethra usually result from gunshot wounds and involve the pendulous and bulbar urethral segments equally. These injuries are associated with penile and testicular injury. These injuries

can also involve the rectum, which may result in pelvic abscesses and the formation of fistulae (6,7). Other less frequent causes of external anterior urethral injuries include stab wounds, penile amputation, and impalement. Iatrogenic urethral injuries caused by instruments are by far the most common cause of urethral trauma

**Table 10: Examples of urethral injury**

| Cause               | Example  |
|---------------------|--|
| Blunt trauma        | Vehicular accidents<br>Fall astride (straddle – bicycle, fences, inspection covers)<br>Kicks in the perineum |
| Sexual intercourse  | Penile fractures<br>Urethral intraluminal stimulation  |
| Penetrating trauma  | Gunshot wounds<br>Stab wounds<br>Dog bites<br>External impalement<br>Penile amputations                      |
| Constriction bands  | Paraplegia   |
| Iatrogenic injuries | Endoscopic instruments<br>Urethral catheters/dilators  |

## 5.2 Posterior urethral injuries

In industrialised societies, pelvic-fracture-related urethral injuries of the posterior urethra are the commonest non-iatrogenic injuries and are usually due to MVAs.

The male posterior urethra is injured in 4-19% of pelvic fractures. The female urethra is rarely injured (0-6%), and mostly by contusion or bone fragments.

During crush or deceleration impact injury, the severe shearing forces needed to fracture the pelvis are transmitted to the prostatomembranous junction. This results in disruption of the prostate from its connection to the anterior urethra at the prostatic apex.

Typical injuries of the bladder neck and prostate in adults show several characteristic features. They occur in the midline of both the bladder neck and prostatic urethra, in association with either a lateral compression fracture of the pelvis or an open-book injury (8).

Urethral ruptures can be divided into partial and complete ones. Complete urethral ruptures can occur as distraction defects when associated with pelvic fractures. In urethral distraction defects, there is a gap between the disrupted end of the urethra. The dismembered ends of the urethra retract and fibrous tissue fills the space between them. There is no urethral wall in the scarred space, and any lumen represents merely a fistulous tract between the urethral stumps (8,9).

Injury to the posterior urethra is most likely to occur with unstable pelvic fractures (10-16), bilateral ischiopubic rami fractures ('straddle fracture'), and symphysis pubis diastasis. In particular, the combination of straddle fractures with diastasis of the sacroiliac joint has the highest risk of urethral injury; the odds ratio is about seven times higher than for either straddle injuries or sacroiliac ('Malgaigne') fractures (Table 11) (4).

**Table 11: Odds ratio of suffering urethral injury with different types of pelvic fracture**

| Type of fracture             | Odds ratio |
|------------------------------|------------|
| Single ramus                 | 0.6        |
| Ipsilateral rami             | 0.8        |
| Malgaigne's (vertical shear) | 3.4        |
| Straddle                     | 3.9        |
| Straddle plus sacroiliac     | 24.0       |

Odds ratio: describes the strength of association or non-independence between urethral injury and types of pelvic fracture.

By themselves, urethral injuries are never life-threatening, except as a consequence of their close association

with pelvic fractures and multiple organ injuries, which occur in about 27% of cases (17).

However, they can result in very significant delayed morbidity. Strictures, incontinence and erectile dysfunction are well-recognised associated problems that interfere with the quality of life. It is important to diagnose and treat such urethral injuries efficiently to reduce the severity and duration of such complications.

Erectile dysfunction occurs in 20-60% of patients after traumatic posterior urethral rupture (9,18-20). The severity of the initial injury is the most important determining factor for impotence. The incidence of erectile dysfunction caused by the open surgical repair itself is 5% or less (9,22). King reported an incidence of 42% in cases of pelvic fracture and urethral injury, but only 5% when the urethra was not injured (19). Barbagli et al. reported an incidence of 60% in patients with posterior urethral injury compared with 14% in patients with bulbar injury (23).

Bilateral pubic rami fractures are the most frequent cause of impotence. Impotence is most commonly neurogenic, due to bilateral damage of the cavernous nerves at the prostatomembranous urethra behind the symphysis pubis (24,25). Associated vasculogenic erectile failure may occur in up to 80% of cases (26). Spontaneous return of potency may occur up to 2 years after injury (27).

### 5.3 Urethral injuries in women

These are rare events since the female urethra is short and mobile, without any significant attachments to the pubic bone. They are often accompanied by severe pelvic fractures, in which bony fragments of the fractured pelvis can lacerate the urethra. Urethral injuries in females often extend into the bladder neck or vagina and disrupt the normal continence mechanism (28,29). Injury to the female urethra is usually a partial tear of the anterior wall and is rarely a complete disruption of the proximal or distal urethra (30).

### 5.4 Penetrating injuries to the perineum

These can occur after external violence, e.g. gunshot or stab wounds, or as iatrogenic injuries caused by endoscopic instruments or during surgery for vaginal repair. In developing countries, urethral and bladder neck damage are quite often caused by ischaemic injury during obstructed labour.

### 5.5 Diagnosis: initial emergency assessment

#### 5.5.1 Clinical assessment

Firstly, and most importantly, urethral bleeding and voiding difficulty should raise the suspicion of urethral trauma, although their absence does not rule out urethral injury. The presentation of clinical symptoms or signs may be delayed (2).

Table 12 lists the clinical indicators of acute urethral trauma that warrant a complete urethral evaluation.

**Table 12: Clinical signs of urethral injuries**

|                                    |
|------------------------------------|
| Blood at the meatus                |
| Blood at the vaginal introitus     |
| Haematuria                         |
| Pain on urination - Dysuria        |
| Inability to void                  |
| Haematoma                          |
| Swelling                           |
| 'High-riding' or "absent" prostate |

Blood at the meatus is present in 37-93% of patients with posterior urethral injury, and in at least 75% of patients with anterior urethral trauma (31,32). When urethral trauma is suspected an attempt of urethral catheterisation should be carried out by experienced hands and the balloon of the Foley catheter should only be inflated if clear urine flows out. It is extremely unlikely that gentle passage of a urethral catheter will do any additional damage (33,34). Although it has been suggested that passing a catheter may convert a partial tear into one that is complete (35), there are no convincing data indicating that there is a higher rate of infection or urethral stricture after a single attempt at catheterisation (1). However, the most prudent approach is to carry out urethrography prior to an attempted catheterisation. In an unstable patient, an attempt to pass a urethral catheter should be performed, but if there is any difficulty, a suprapubic catheter should be placed using

ultrasound guidance and a retrograde urethrogram must be performed once the patient has been stabilised.

Blood at the vaginal introitus is present in more than 80% of female patients with pelvic fractures and co-existing urethral injuries (28).

Although non-specific, haematuria on a first-voided specimen may indicate urethral injury. The amount of urethral bleeding correlates poorly with the severity of the injury. A mucosal contusion or small partial tear may be accompanied by copious bleeding, while total transection of the urethra may result in little bleeding (36).

Urethral disruption should be suspected in patients with urethral injuries who report having trouble with voiding or an inability to void.

Urethral bleeding or urinary extravasation can cause penile/scrotal swelling, or even more extensive haematoma. An assessment for concomitant genital injuries is therefore mandatory in every case of external urethral trauma.

Rectal examination may reveal a 'high-riding' prostate, which is a relatively unreliable finding in the acute phase of urethral injury. This is because the pelvic haematoma associated with pelvic fractures often precludes the adequate palpation of a small prostate, particularly in younger men (1). Blood on the examination finger is suggestive of a rectal injury associated with pelvic fractures.

#### 5.5.2 Radiographic examination (Table 13)

Retrograde urethrography is the gold standard for evaluating urethral injury (30,37). A scout film should be performed first to assess the radiographic technique and to detect pelvic fractures and foreign bodies, such as bullets.

A scout film is performed by injecting 20-30 mL of contrast material while occluding the meatus. Films are taken in a 30°-oblique position, unless this is not possible because of the severity of the pelvic fractures and associated patient discomfort. The urethrogram allows for identification of the site and assessment of the extent of any injury. The image of extravasation but still bladder filling is typical for incomplete rupture, however massive extravasation without bladder filling suggests a complete rupture.

Ultrasonography is not a routine investigation in the initial assessment of urethral injuries, but it can be very useful in determining the position of pelvic haematomas or the exact location of the bladder when a suprapubic catheter is indicated. Furthermore, penile ultrasound can help to rule out tunica albuginea ruptures in cases of blunt traumas to the penis. Although extratunical and cavernosal hematomas can be treated conservatively, tunical ruptures need immediate surgical repair.

Computed tomography and MRI have no place in the initial assessment of urethral injuries. However, they are useful in defining distorted pelvic anatomy after severe injury and assessing associated injuries of the penile crura, bladder, kidneys, and intra-abdominal organs (38,39).

Urethroscopy does not have any role in the initial diagnosis of urethral trauma in males. In females, however, where the short urethra precludes adequate retrograde urethrography, urethroscopy is an important adjunct to the physical examination for the identification and staging of urethral injuries (40).

**Table 13: Diagnostic tools for urethral injuries**

|                            |  |
|----------------------------|--|
| Retrograde urethrography   | Gold standard  |
| Ultrasonography            | Helps to evaluate concomitant injuries                     |
| Computed tomography        | Not part of initial assessment                             |
| Magnetic resonance imaging | Not part of initial assessment                             |
| Urethroscopy               | Alternative to retrograde urethrography in female patients |

## 5.6 Management

The management of urethral injuries remains controversial because of the variety of injury patterns, associated injuries and treatment options available.

As already mentioned, the gold standard diagnostic procedure for suspected urethral injuries is retrograde



urethrography. Treatment decisions are made according to the radiological results of the urethrography.

The American Association for Surgery of Trauma has proposed a classification for urethral injury. However, it is rarely used in practical everyday use. This is because the only useful information for clinicians is whether the urethra is partially or completely disrupted and the anatomical site of the injury as well as the concomitant local tissue damage.

#### **5.6.1 Anterior urethral injuries**

Retrograde urethrography is used to identify any extravasation. The next key information for the treatment decision is whether the cause of the urethral injury is based on a blunt or penetrating trauma. According to this information, treatment decisions are being made.

##### **5.6.1.1 Blunt anterior urethral injuries**

###### **5.6.1.1.1 Acute management**

Blunt anterior urethral injuries are associated with spongiosal contusion, which makes it more difficult to evaluate the limits of urethral debridement in the acute phase. Acute or early urethroplasty is therefore not indicated, and the best management is simply suprapubic diversion. Satisfactory urethral luminal recanalisation occurs in approximately 50% of partial anterior urethral disruptions (41,42).

Partial tears can be managed with a suprapubic catheter or with urethral catheterisation (30,33,41). Urinary diversion is maintained until healing is demonstrated by urethrography (antegrade or peri-catheter). Extravasated blood or urine from the urethral tear produces an inflammatory reaction that can progress to abscess formation. Prompt urinary diversion, together with the appropriate administration of antibiotics, decreases the incidence of potential complications as urethrocutaneous fistulae, periurethral diverticulae and rarely necrotising fasciitis (43).

###### **5.6.1.1.2 Delayed management**

After the patient has adequately recovered from any associated injuries, and the urethral injury has stabilised, the urethra can be thoroughly re-evaluated radiographically. When necessary, the appropriate reconstructive procedure is planned.

Short and flimsy strictures are managed with optical urethrotomy or urethral dilatation. Denser strictures require formal urethral reconstruction. Anastomotic urethroplasty is indicated in strictures of less than 1 cm in length. Longer strictures of the anterior urethra should not be repaired by an end-to-end anastomosis in order to avoid chordee. In these cases, flap/graft urethroplasty is indicated. Almost all complete ruptures of the anterior urethra require anastomotic or patch urethroplasty at 3-6 months.

##### **5.6.1.2 Penetrating anterior urethral injuries**

###### **5.6.1.2.1 Acute management**

Stab wounds, gunshot wounds and dog bites to the urethra often involve the penis and testes and often require immediate exploration. During surgery, the urethral injury can be evaluated and repaired as needed. Urethral strictures form in fewer than 15% of these patients (44).

In complete disruptions, the corpus spongiosum is mobilised at the level of the injury and the urethral ends dissected distally and proximally. Urethral ends are spatulated and end-to-end anastomosis is fashioned over a catheter. Small lacerations are being sutured with fine absorbable material. Careful overclosure of the corpus spongiosum and skin prevents the subsequent formation of fistulae (17). Urethral debridement should be kept to a minimum since the spongiosum is well vascularised and so usually heals well. Peri-operative antimicrobial therapy is mandatory.

Most female urethral disruptions can be sutured primarily. These injuries often occur together with bladder ruptures. Often, the bladder injury is repaired primarily. The urethral disruption may be repaired at the same time. For proximal urethral injuries, urethral exposure is best obtained transvesically. Distal urethral injuries can be approached vaginally (30). The early repair of post-traumatic urethral fistulae can also be accomplished transvaginally (28,29).

###### **5.6.1.2.2 Delayed management**

If the urethra is so extensively disrupted that primary anastomosis is not feasible, then primary repair should be aborted. This occurs with defects of more than 1-1.5 cm in length. Instead, the urethra should be marsupialised preparatory to a two-stage urethral repair, and a suprapubic urinary diversion should be considered. A

delayed elective procedure should be performed a minimum of 3 months after injury. There is no role for acute placement of a graft or flap in the initial management of any urethral injury, since this type of repair can be compromised by contamination or a decreased blood supply (45).

## 5.6.2 **Posterior urethral injuries**

### 5.6.2.1 *Blunt posterior urethral injuries*

In cases of prostatomembranous disruption, the degree of rupture has to be assessed. It is important to distinguish between complete and partial rupture in order to proceed with treatment. Complete rupture warrants further assessment of bladder neck injury, concomitant organ injuries, etc. Partial ruptures can be treated with the insertion of a suprapubic catheter.

#### 5.6.2.1.1 Acute management

##### 5.6.2.1.1.1 Partial posterior urethral rupture

Partial tears of the posterior urethra can be managed with a suprapubic or urethral catheter. Urethrography should be performed at 2-weekly intervals until healing has occurred (30,33). Injuries may heal without significant scarring or obstruction if managed by diversion alone (46,47). Residual or subsequent stricture should be managed with urethral dilatation or optical urethrotomy if short and flimsy, and with anastomotic urethroplasty if dense or long (17,33).

##### 5.6.2.1.1.2 Complete posterior urethral rupture

For complete prostatomembranous disruption caused by blunt trauma a suprapubic catheter is the primary treatment. Further treatment depends on the patients comorbidity and co-existing injuries. (48,49).

Acute treatment options after position of the suprapubic catheter include:

- primary (endoscopic) realignment;
- immediate open urethroplasty, which should be considered experimental and rarely or never used in patients without associated rectal or bladder neck injury.

#### *Primary realignment*

In the absence of indications for immediate exploration, posterior urethral disruption can be managed in a delayed primary fashion. Primary realignment requires placement of a suprapubic tube at the time of initial injury, with repair undertaken when the patient is stable, usually within 7 days. At this time, patients are stable, and most pelvic bleeding has resolved. The aim of internal realignment is to correct severe distraction injuries rather than to prevent a stricture occurring, although realignment will also ensure that a stricture is easily treated if it does occur (50).

Open realignment has been described (51), but it should be performed only in patients who undergo open abdominal or pelvic surgery for associated injuries or internal bone fixation. Haematomas that prevent adequate pelvic descent can be evacuated at this time in these cases.

Concomitant bladder neck or rectal injuries should usually be repaired immediately, and open or endoscopic urethral realignment over a catheter at the same time might be advisable. The reasons for immediate repair of bladder neck and rectal injury are:

- Unrepaired bladder neck injury risks incontinence and infection of the pelvic fractures.
- Unrepaired rectal injury carries the obvious risk of sepsis and fistulae. Early exploration is indicated to evacuate contaminated haematomas and to perform colostomy if necessary. Urethral realignment over a stenting catheter is appropriate in such cases (30,36,52-54).
- The overall condition of the patient and the extent of the associated injuries greatly affect the decision to proceed with primary realignment.

The proposed benefits of primary alignment are:

- A lower stricture rate than with suprapubic catheter placement alone (69% vs. 10%) (55), which avoids a second operation for urethral reconstruction in about one-third of patients (1).
- If scarring occurs, restoration of urethral continuity is simplified and may be accomplished by endoscopic procedures or dilatation.
- If urethroplasty is required later, it is technically easier when the prostate and urethra are well aligned. However, there is the disadvantage of a higher incidence of erectile dysfunction and incontinence when compared with delayed reconstruction (55,56).

The great variation of techniques used for primary realignment procedures confuses any comparison with

delayed repair procedures (57,60). Primary realignment techniques include:

- simple passage of a catheter across the defect (59);
- catheter realignment using flexible/rigid endoscopes and biplanar fluoroscopy (61,62);
- use of interlocking sounds ('railroading') or magnetic catheters to place the catheter (60,63);
- pelvic haematoma evacuation and dissection of the prostatic apex (with or without suture anastomosis) over a catheter;
- catheter traction or perineal traction sutures to pull the prostate back to its normal location (64).

Realignment may be insufficient to join the margins of the severed urethra completely. Defects of 1.5-4.0 cm have been observed, even after catheter realignment (65). Traction on the catheter might not improve the healing of the urethra and could in fact harm continence. Sustained traction on the Foley balloon catheter can damage the remaining sphincter mechanism at the bladder neck as a result of pressure necrosis (1,52). Series that use immediate urethral realignment with minimal traction without suture repair bolsters report the most favourable results. Endoscopic primary realignment fulfils these criteria and should be used when a primary procedure is contemplated. However it has to be kept in mind, that success rates might be low.

A recent retrospective study showed that early endoscopic realignment is only successful in up to 21% (4 of 19 patients) (66). Current literature shows that erectile dysfunction, urinary incontinence and the re-stricture rate following primary realignment are reported to be approximately 35%, 5% and 60% respectively (67-82).

#### *Immediate open urethroplasty*

Immediate open urethroplasty of posterior injuries is not indicated because of poor visualisation and the inability to assess accurately the degree of urethral disruption during the acute phase, characterised by extensive swelling and ecchymosis. The difficulty in identifying structures and planes makes it harder to achieve adequate mobilisation and subsequent surgical apposition (17). Incontinence and impotence rates are higher than with the other techniques described in these guidelines (impotence 56%, incontinence 21%, restricture 49%) (30,46,50,53,55,83,84).

However, in posterior urethral injuries associated with concomitant bladder neck or rectal injuries, immediate open exploration, repair and urethral realignment over a catheter is advisable (30,36,52-54).

#### 5.6.2.1.2 Delayed management of posterior urethral injuries

Delayed treatment options include:

- delayed primary urethroplasty (which implies primary repair within 2 weeks after injury and for which there is a lack of supporting evidence in male patients);
- delayed formal urethroplasty at 3 months after injury (the most standard approach);
- delayed endoscopic incision of the scar tissue between the urethral ends (so-called 'cut-to-the-light' or similar procedures).

#### *Delayed primary urethroplasty*

Delayed primary urethroplasty is mainly indicated in female urethral disruption, although no large series exists. It requires placement of a suprapubic tube at the time of initial injury, with repair undertaken when the patient is stable, usually within 14 days. Fewer than 50 cases have been reported, and most of these are individual case reports only (29).

Delayed primary repair tries to preserve as much urethral length as possible, and to avoid the urethra becoming embedded in dense scar tissue with consequent incontinence. Surgical exploration should be attempted via the retropubic route for proximal injuries, and the vaginal route for distal injuries (30).

#### *Delayed formal urethroplasty*

Delayed formal urethroplasty is the procedure of choice and the gold standard for the treatment of posterior urethral distraction defects. Most posterior urethral distraction defects are short, and can generally be resolved by a perineal approach anastomotic repair, provided that they are not associated with extensive haematoma-fibrosis and the bladder neck mechanism is occlusive and competent. After division of the bulbar urethra at the distal point of obliteration, mobilisation of a normal bulbar urethra to the base of the penis generally achieves 4-5 cm of elastic lengthening. This is usually sufficient to achieve a tension-free 2-cm spatulated overlap anastomosis, after bridging a gap of 2.0-2.5 cm without rerouting (17).

This technique has the advantage that associated injuries, damaged skin and tissues and pelvic haematoma have resolved by the time it is performed.

When the prostatobulbar gap is longer than 2-3 cm as a result of a high dislocation of the prostate, or when the

available elongation of the mobilised urethra has been foreshortened by damage caused by a previous surgical procedure, additional procedures may be required. The following manoeuvres are carried out sequentially to gain sufficient anterior urethral mobility to bridge up to 8 cm of separation, and are referred to as the 'progressive perineal approach' (85):

- midline separation of the proximal corporal bodies;
- inferior pubectomy;
- supracorporal urethral rerouting.

In addition to its use as an initial therapy for posterior urethral distraction injuries, the progressive perineal approach can also be applied successfully to salvage procedures following failed repair. There are a number of circumstances that might preclude successful perineal anastomotic repair as either initial or salvage therapy. These circumstances probably represent fewer than 5% of cases and are shown in Table 14 (86,87).

**Table 14: Circumstances that might preclude successful perineal anastomotic repair as either initial or salvage therapy (86,87)**

| Circumstance                            | Alternative procedure  |
|---|--|
| Distraction defects longer than 7-8 cm  | A tubed interposition flap of penile or perineal skin can be used for reconstruction. This is seldom required and most patients that require the use of flap urethroplasties have previous failed repairs of posterior urethral rupture  |
| Fistulae                                | These might require a combined abdominoperineal approach to secure adequate closure  |
| Synchronous anterior urethral stricture | The presence of anterior urethral stricture may compromise the blood supply to the bulbar urethra following division of the bulbar arteries, and these patients should be treated cautiously   |
| Urinary incontinence                    | The distal urethral sphincter mechanism could be defunctionalised by urethral distraction, so urinary continence may be maintained primarily by the proximal bladder neck sphincter. Concomitant bladder neck injury might increase incontinence and could require an abdominoperineal procedure to allow simultaneous bladder neck and urethral reconstruction. (49,88) |

The results of various techniques are reviewed by Koraitim (54) in a personal series of 100 patients combined with a review of 771 patients from published reports. Immediate and early realignment (n = 326) was associated with rates of 53% for stricture, 5% for incontinence and 36% for impotence. Of the patients successfully managed with immediate realignment, 42% needed subsequent instrumentation to attempt stabilisation of the stricture. Urethroplasty was required eventually in 33%.

Primary suturing (n = 37) was associated with rates of 49% for stricture, 21% for incontinence, and 56% for impotence. In comparison, inserting a suprapubic catheter before delayed repair (n = 508) was associated with rates of 97% for stricture, 4% for incontinence, and 19% for impotence. The restricture rate after delayed anastomotic urethroplasty was less than 10% (9,21,34,48,89-93), while the risk of impotence caused by delayed urethroplasty was about 5% (9,21,22,33,53,94-96). The gold standard therapy is still a delayed urethral repair at a minimum of 3 months after trauma, using a one-stage perineal approach.

#### *Delayed endoscopic optical incision*

The principles of the procedure were described by Sachse in 1974 (97). A curved metal sound is passed through the suprapubic cystostomy into the blind-ended proximal urethra. The direct vision urethrotome is inserted into the urethra, and cuts are made towards the sound. Blandy described a modification of this procedure, involving suprapubic passage of a cystoscope for transillumination of the thin perineal membrane and transurethral 'cutting-to-the-light' with an electrode (98).

Today, the cut-to-the-light technique is sometimes carried out using C-arm fluoroscopy for stereotactic guidance. The urethral catheter is left in place for between 1 and 3 weeks and suprapubic drainage for an additional 2 weeks to confirm consistent voiding (99). The results of several small series suggest that almost 95% of patients following optical urethrotomy for traumatically obliterated pelvic urethra require repeat urethrotomies (72,100-111). Thus, the procedure is only indicated if the urethral defect is short, the bladder neck is competent and there is minimal displacement of the prostate and proximal bulbous urethra (104).

Although immediate restoration of urethral continuity is commonly possible, failure is common. About 80% of patients will require urethral dilatation, optical urethrotomy and transurethral resection of stricture. Most repeat urethrotomies are performed in the first year of follow-up. It should be noted that after failure of the initial urethrotomy, alternative treatments should be considered, as repeat urethrotomy achieves only temporary improvement (112). Urethral false passage and rectal perforation have been reported (100,104,107). Stents are not currently recommended for patients with strictures following pelvic trauma, as fibrotic tissue tends to grow through into the lumen of the stent (48,113-115).

#### *5.6.2.2 Penetrating posterior urethral injuries*

In cases of penetrating trauma associated with prostatomembranous disruption primary, open repair should be performed, regardless of the degree of the urethral disruption. If the patient is unstable, or acute intervention is required for associated non-uological injuries, open repair can be postponed and the urethral injury can be managed with the placement of a suprapubic cystostomy.

#### *5.6.2.3 Management of failed repair of posterior urethral rupture*

Re-stenosis after delayed urethral repair mostly occurs within 6 months. If the anastomosis has a normal caliber at 6 months, then it is extremely unlikely that the patient will develop further stricturing (34). The principles of salvage repair are similar to those of the initial procedure. Salvage repair should be performed in referral centres to minimise potential side effects. Progressive perineal anastomotic repair alone can be successful in 85% of salvage urethroplasties (8). If an anastomotic repair cannot be performed, a one-stage substitution urethroplasty using a pedicle island of penile skin might be possible. Alternatively two-stage inlay procedures, usually with buccal mucosa or mesh split-thickness skin graft, should be performed (51,116,117). Optical urethrotomy is an alternative, particularly for a short and narrow stricture.

## **5.7 Treatment algorithms**

The following algorithms are suggested for the treatment of anterior and posterior urethral injuries in men (Figures 3 and 4)

Figure 3: Management of anterior urethral injuries in men

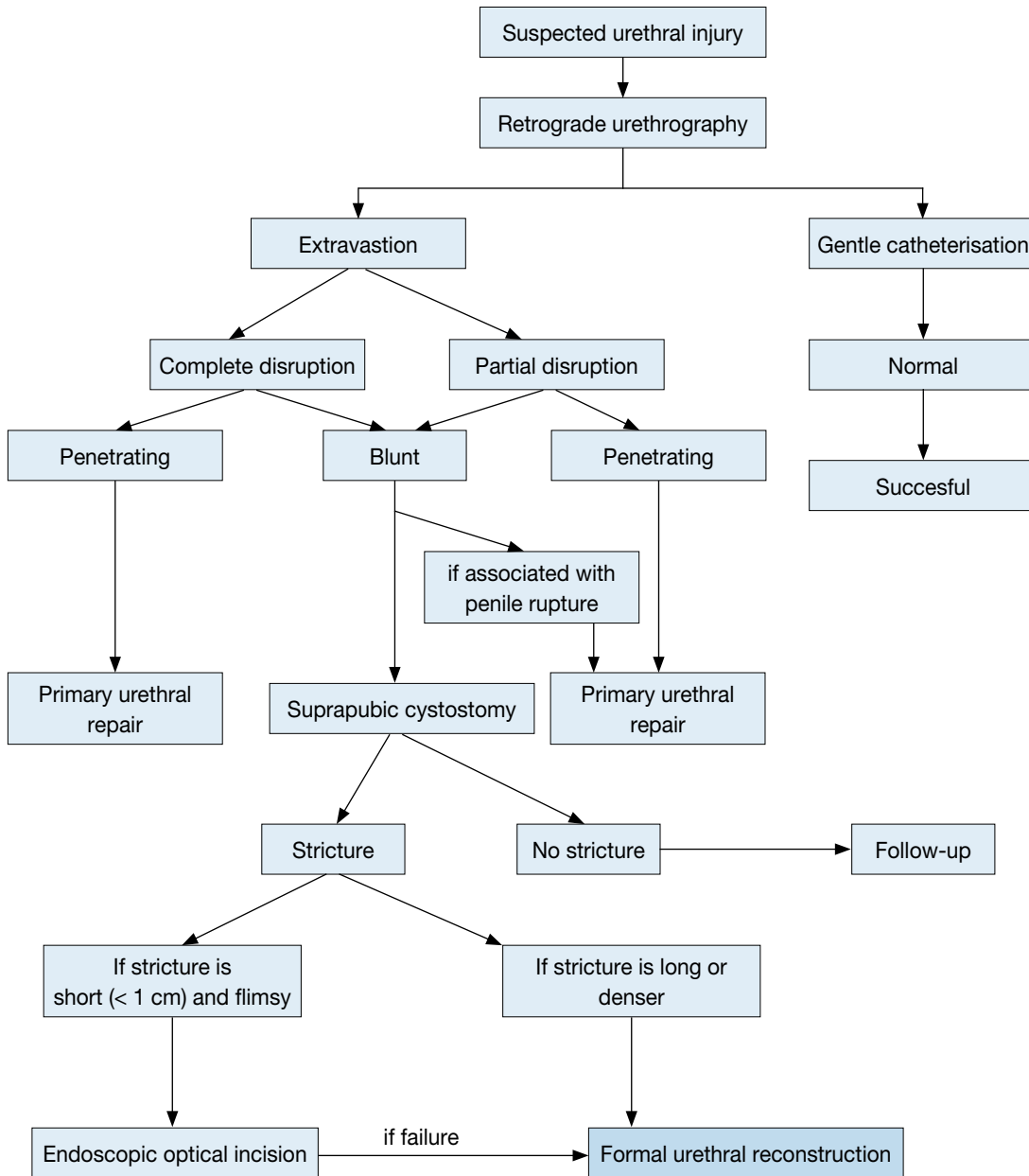
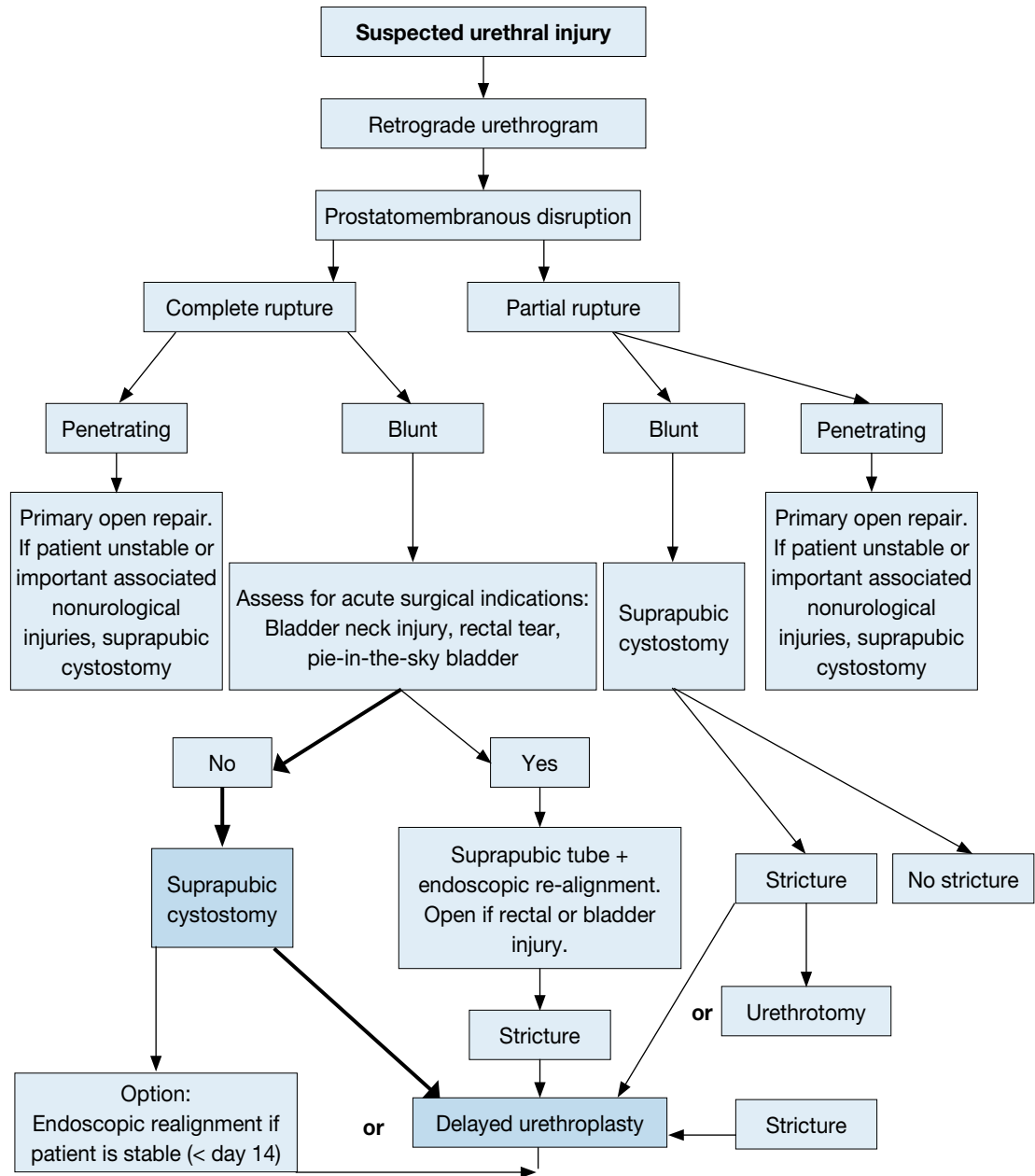


Figure 4: Management of posterior urethral injuries in men



## 5.8 Statements and recommendation on trauma of the urethra

| Statements  | LE |
|---|----|
| Blunt trauma accounts for more than 90% of urethral injuries.   | 3  |
| In penile fracture the urethra is involved in 20% of cases.   | 4  |
| The male posterior urethra is injured in 4-19% in cases of pelvic fractures. In industrialized societies pelvic fracture related injuries of the posterior urethra are the most common non iatrogenic injuries. | 3  |
| Erectile dysfunction occurs in 20-60% of patients after traumatic urethral rupture.   | 3  |

| <b>Recommendations</b>  | <b>GR</b> |
|---|-----------|
| Retrograde urethrography is the gold standard for evaluating urethral injuries.   | B         |
| Delayed formal urethroplasty is the procedure of choice for the treatment of posterior urethral distraction defects.  | B         |
| Partial posterior urethral ruptures have to be treated by suprapubic or urethral catheter.  | C         |
| In the absence of indications for immediate exploration, posterior urethral disruption can be managed in a delayed primary fashion, meaning primary endoscopic realignment. | C         |

## **5.9 Iatrogenic urethral trauma (IUhT)**

### **5.9.1 Introduction**

The most common type of urethral trauma seen in modern urological practice is iatrogenic, due to catheterisation, instrumentation, or surgery (2,118). New treatment methods and applied energy sources can also injure the urethra. In most cases, iatrogenic urethral lesions require surgery due to strictures, which vary in their location and degree and require different management strategies (119).

### **5.9.2 Causes of iatrogenic urethral trauma**

#### **5.9.2.1 Transurethral catheterisation**

Iatrogenic urethral trauma (IUhT) usually results from improper or prolonged catheterisation and accounts for 32% of strictures. Most of these strictures affect the bulbar urethra (119).

In incorrectly placed transurethral catheters, the pressure needed to fill the balloon and the force associated with manual extraction are much greater than when the catheter is placed correctly. This leads to a greater probability of urethral lesions (120). Improper urethral catheter insertion is a preventable source of urethral trauma in male patients (121). The risk of this type of urethral injury occurring during a hospital stay has been estimated at 3.2 per 1000 cases (119).

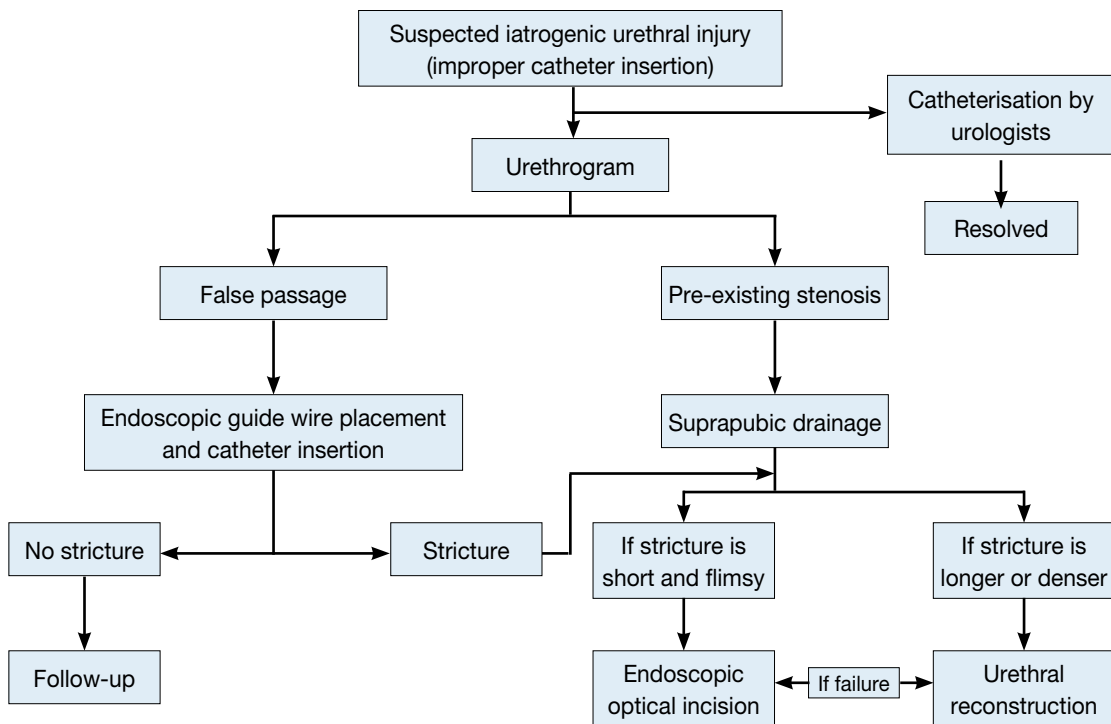
Stricture formation due to indwelling catheters is a common problem (118) that primarily affects the anterior urethra. The bladder neck is rarely affected in such cases (122).

It is possible to prevent or reduce the frequency of a wide range of iatrogenic urethral injuries. Implementing training programmes may significantly decrease the incidence, increasing patient safety and reducing the negative long-term effects (118,123) (LE: 2b).

Male patients undergoing cardiac surgery, such as bypass and other major operations associated with a need for catheterisation, are at risk for urethral trauma and stricture formation. Women undergoing abdominal surgery are also at risk during catheterisation. The size and type of catheter used have an important impact on urethral stricture formation. Current data indicate that silicone catheters and small-calibre Foley catheters are associated with less urethral morbidity (124).



**Figure 5: Flow diagram of treatment for iatrogenic urethral injury caused by improper insertion of a catheter**



#### 5.9.2.2 Transurethral surgery

Transurethral procedures are a common cause of iatrogenic urethral trauma (IUHT). Factors that may influence the development of iatrogenic endoscopic urethral strictures include electrical dispersion generated by unipolar current and the diameter of the instruments used (125) (LE: 1b).

Predisposing factors most strongly associated with stricture formation in patients undergoing TURP are increasing prostate volume, prostate cancer and the surgeon's experience (126).

Meatal strictures occur as a result of a mismatch between the size of the instrument and the diameter of the urethral meatus. Bulbar strictures occur due to insufficient insulation by the lubricant, causing the monopolar current to leak. To prevent strictures, lubricant gel should be applied carefully in the urethra. The lubricant must be reapplied when the resection time is prolonged (127). Internal urethrotomy must be performed before TURP if there are pre-existing meatal or urethral strictures (127).

There appears to be no relationship with the duration of procedures or the method used (holmium laser or traditional TURP) on the rate of stricture formation (128).

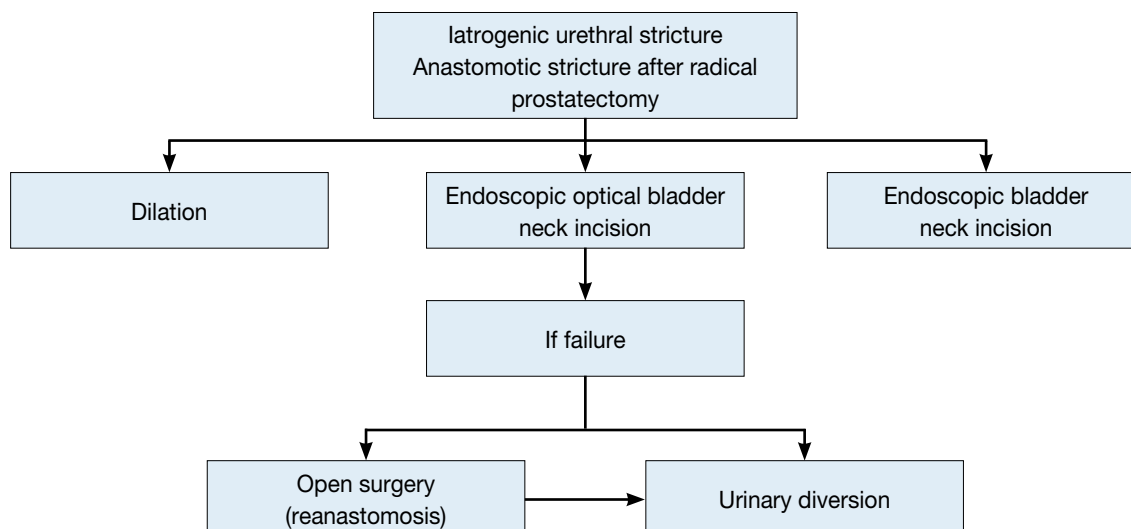
#### 5.9.2.3 Surgical treatment for prostate cancer

Urethral stricture following prostate cancer treatment can occur anywhere from the bladder neck to the urethral meatus. The rate of bladder neck constriction after radical prostatectomy varies with the definition of the stricture used and individual practice (129,130) (LE: 2a). The Cancer of the Prostate Strategic Urologic Research Endeavour (CaPSURE) database shows an incidence of urethral stricture after various forms of prostate cancer therapy of 1.1-8.4%. The risk is greatest after radical prostatectomy if combined with external-beam radiation therapy. In a multivariate analysis, primary treatment type, age, and obesity were found to be significant predictors for stricture development (129) (LE: 2b).

Robot-assisted prostatectomy also affects urinary function and the risk of iatrogenic trauma. Iatrogenic complications involving the bladder neck account for 2.2%, similar to the stricture rate found with conventional treatment for localised prostate cancer (131) (LE: 2b).

Anastomotic stricture is also a complication in conventional laparoscopic prostatectomy. If prospective studies only are taken into account, there is no significant difference in the anastomotic stricture rate between laparoscopic and robot-assisted radical prostatectomy (132) (LE: 3b).

**Figure 6: Flow diagram of treatment for stricture after radical prostatectomy**



#### 5.9.2.4 Radiotherapy for prostate cancer

The development of urinary fistulae has been reported after brachytherapy and radical prostatectomy, with incidences of 0.3-3.0% and 0-0.6%, respectively. Most fistulae involve the rectum (133,134) (LE: 3). Brachytherapy is a recognised cause of strictures in patients with localised prostate cancer, as the CaPSURE study has shown (135). Previous TURP increases the risk of stricture formation (136,137).

#### 5.9.2.5 Major abdominal surgery and cystectomy

Iatrogenic injuries to the urethra are not a rare complication of abdominal and pelvic procedures. Bladder and urethral catheterisation must therefore be carried out preoperatively to prevent these complications (138) (LE: 2). Radical cystectomy and subsequent urinary diversion may also cause urethral trauma (139). Table 15 lists the most common causes of urethral trauma.

**Table 15: Most common causes of urethral trauma**

| Procedure   | Percentage  |
|---|---|
| Catheterisation   | 32% of iatrogenic urethral strictures (52% bulbar urethra)  |
| Urethral instrumentation for therapy and/or diagnosis   |   |
| Treatment for prostatic disease   | 1.1-8.4% urethral stricture rate  |
| Transurethral surgery (e.g. TURB/TURP)  | 2.2-9.8% urethral stricture rate  |
| Radical prostatectomy   | 0.5-32% bladder neck constriction; no difference between LRP and RALP (relative risk: 1.42; 95% confidence interval for relative risk, 0.40-5.06; p = 0.59) |
| Radiotherapy (percutaneous or brachytherapy)  | 6% urethral stricture rate, 0.3-3.0% urinary fistula rate   |
| Greatest risk for urethral stricture is found for the combination of radical prostatectomy and EBRT |   |
| Cryotherapy   |   |
| HIFU  |   |
| Treatment for bladder disease   |   |
| TURB  |   |
| Cystectomy  | 3.1% subneovesical obstruction, 1.2% neovesicourethral anastomotic strictures, 0.9% urethral strictures   |
| Injury during major abdominal and pelvic operations   |   |

TURB = transurethral resection of the bladder; TURP = transurethral resection of the bladder; LRP = radical prostatectomy; RALP = robot-assisted laparoscopic prostatectomy; EBRT = external-beam radiation therapy; HIFU = high-intensity focused ultrasound.

### 5.9.3 Symptoms of iatrogenic urethral injury

Symptoms of urethral lesions caused by improper catheterisation or instrumentation are penile and/or perineal pain (100%) and urethral bleeding (86%) (122) (LE: 2b). Failure to diagnose accurately and treat urethral injuries may lead to significant long-term sequelae, in most cases presenting as strictures (140,141).

### 5.9.4 Diagnosis

Uroflowmetry, urethrography, and/or urethroscopy are the key investigations in diagnosis, and the algorithm is the same for acute and delayed symptoms. In the acute phase, the symptoms are bleeding and difficulty during catheterisation. Delayed symptoms include worsening of flow and other symptoms of obstruction.

### 5.9.5 Treatment

The value of temporary stenting in minor urethral injuries is unproven. Temporary stenting with an indwelling catheter is the conventional treatment option for an acute false passage (142). In difficult cases, it may be assisted by cystoscopy and guidewire placement (143) (LE: 3). Suprapubic catheterisation is an alternative.

Endoscopic management, either with incision or resection, can successfully treat iatrogenic prostatic urethral strictures. Indwelling catheter placement or an open procedure, associated with increased morbidity, are alternatives (144) (LE: 2b).

Urethral lesions following radiotherapy are often more difficult to treat and may require complex reconstructive surgery (133,134). Table 16 lists the statements and recommendations regarding the iatrogenic causes of IUHT.

**Table 16: Statements and recommendations regarding iatrogenic urethral trauma**

| Statements   | LE |
|--|----|
| Iatrogenic causes are the most common type of urethral injury in Europe and therefore the most common cause of urethral stricture formation. | 2a |
| Implementing training programmes on urinary catheter insertion significantly improves the rate of catheter-related complications.            | 2b |
| New technologies represent an additional source of urethral injury.  | 3  |

| Recommendations  | GR |
|--|----|
| Proper training should be provided to reduce the risk of traumatic catheterisation.            | A  |
| Urethral instrumentation should only be carried out when there are valid clinical indications. | A  |
| When catheterisation is necessary, its duration should be kept to a minimum.                   | B  |

LE= level of evidence; GR = grade of recommendation.

### 5.9.6 References

1. Dixon CM. Diagnosis and acute management of posterior urethral disruptions, In: McAninch JW (ed). Traumatic and reconstructive urology. Philadelphia: WB Saunders, 1996, pp. 347-355.
2. Mundy A, Andrich D. Urethral trauma. Part I: introduction, history, anatomy, pathology, assessment and emergency management. BJUI 2011 Aug;108(3):310-27  
<http://www.ncbi.nlm.nih.gov/pubmed/21771241>
3. Sevitt S. Fatal road accidents. Injuries, complications, and causes of death in 250 subjects. Br J Surg 1968 Jul;55(7):481-505.  
<http://www.ncbi.nlm.nih.gov/pubmed/5663432>
4. Koraitim MM, Marzouk ME, Atta MA, et al. Risk factors and mechanism of urethral injury in pelvic fractures. Br J Urol 1996 Jun;77(6):876-80.  
<http://www.ncbi.nlm.nih.gov/pubmed/8705225>
5. Nicolaisen GS, Melamud A, Williams RD, et al. Rupture of the corpus cavernosum: surgical management. J Urol 1983 Nov;130(5):917-9.  
<http://www.ncbi.nlm.nih.gov/pubmed/6632099>
6. Gomez RG, Castanheira AC, McAninch JW. Gunshot wounds to the male external genitalia. J Urol 1993 Oct;150(4):1147-9.  
<http://www.ncbi.nlm.nih.gov/pubmed/8371375>
7. Pontes JE, Pierce JM Jr. Anterior urethral injuries: four years of experience at the Detroit General Hospital. J Urol 1978 Nov;120(5):563-4.  
<http://www.ncbi.nlm.nih.gov/pubmed/568672>

8. Mundy A, Andrich D. Pelvic fracture-related injuries of the bladder neck and prostate: their nature, cause and management. *BJU Int* 2010 May;105(9):1302-8.  
<http://www.ncbi.nlm.nih.gov/pubmed/19874306>
9. Martínez-Piñero JA, Cárcamo P, García Matres MJ, et al. Excision and anastomotic repair for urethral stricture disease: experience with 150 cases. *Eur Urol* 1997;32(4):433-41.  
<http://www.ncbi.nlm.nih.gov/pubmed/9412802>
10. Palmer JK, Benson GS, Corriere JN Jr. Diagnosis and initial management of urological injuries associated with 200 consecutive pelvic fractures. *J Urol* 1983 Oct;130(4):712-4.  
<http://www.ncbi.nlm.nih.gov/pubmed/6887403>
11. Pokorny M, Pontes JE, Pierce JM Jr. Urological injuries associated with pelvic trauma. *J Urol* 1979 Apr;121(4):455-7.  
<http://www.ncbi.nlm.nih.gov/pubmed/439217>
12. Basta AM, Blackmore CC, Wessells H. Predicting urethral injury from pelvic fracture patterns in male patients with blunt trauma. *J Urol* 2007 Feb;177(2): 571-5.  
<http://www.ncbi.nlm.nih.gov/pubmed/17222635>
13. Pennal GF, Tile M, Waddell JP, et al. Pelvic disruption: assessment and classification. *Clin Orthop Relat Res*.1980 Sep;(151):12-21.  
<http://www.ncbi.nlm.nih.gov/pubmed/7418295>
14. Conolly WB, Hedberg EA. Observations on fractures of the pelvis. *J Trauma* 1969 Feb;9(2):104-111.  
<http://www.ncbi.nlm.nih.gov/pubmed/5763326>
15. Flaherty JJ, Kelley R, Burnett B, et al. Relationship of pelvic bone fracture patterns to injuries of urethra and bladder. *J Urol* 1968 Mar;99(3):297-300.  
<http://www.ncbi.nlm.nih.gov/pubmed/5689611>
16. Devine PC, Devine CJ Jr. Posterior urethral injuries associated with pelvic fractures. *Urology* 1982 Nov;20(5):467-70.  
<http://www.ncbi.nlm.nih.gov/pubmed/7147524>
17. Chapple CR, Png D. Contemporary management of urethral trauma and the post-traumatic stricture. *Curr Opin Urol* 1999 May;9(3):253-60.  
<http://www.ncbi.nlm.nih.gov/pubmed/10726100>
18. Gibson GR. Impotence following fractured pelvis and ruptured urethra. *Br J Urol* 1970 Feb;42(1):86-8.  
<http://www.ncbi.nlm.nih.gov/pubmed/5435706>
19. King J. Impotence after fractures of the pelvis. *J Bone Joint Surg Am* 1975 Dec;57(8):1107-9.  
<http://www.ncbi.nlm.nih.gov/pubmed/1201996>
20. Dhabuwala CB, Hamid S, Katsikas DM, et al. Impotence following delayed repair of prostatomembranous urethral disruption. *J Urol* 1990 Sep;144(3):677-8.  
<http://www.ncbi.nlm.nih.gov/pubmed/2388326>
21. Corriere JN. 1-Stage delayed bulboprostatic anastomotic repair of posterior urethral rupture: 60 patients with 1-year followup. *J Urol* 2001 Feb;165(2):404-7.  
<http://www.ncbi.nlm.nih.gov/pubmed/11176383>
22. Webster GD. Impotence following delayed repair of prostatomembranous urethral disruption (editorial comment). *J Urol* 1990;144(3):678.
23. Barbagli G, Selli C, Stomaci N, et al. Urethral trauma: radiological aspects and treatment options. *J Trauma* 1987 Mar;27(3):256-61.  
<http://www.ncbi.nlm.nih.gov/pubmed/3560267>
24. Mark SD, Keane TE, Vandemark RM, et al. Impotence following pelvic fracture urethral injury: incidence, aetiology and management. *Br J Urol* 1995 Jan;75(1):62-4.  
<http://www.ncbi.nlm.nih.gov/pubmed/7850299>
25. Shenfeld OZ, Kiselgorf D, Gofrit ON, et al. The incidence and causes of erectile dysfunction after pelvic fractures associated with posterior urethral disruption. *J Urol* 2003 Jun;169(6):2173-6.  
<http://www.ncbi.nlm.nih.gov/pubmed/12771742>
26. Armenakas NA, McAninch JW, Lue TF, et al. Posttraumatic impotence: magnetic resonance imaging and duplex ultrasound in diagnosis and management. *J Urol* 1993 May;149(5 Pt 2):1272-5.  
<http://www.ncbi.nlm.nih.gov/pubmed/8479013>
27. Koraitim MM, Reda IS. Role of magnetic resonance imaging in assessment of posterior urethral distraction defects. *Urology* 2007 Sep;70:403-6.  
<http://www.ncbi.nlm.nih.gov/pubmed/17905082>
28. Perry MO, Husmann DA. Urethral injuries in female subjects following pelvic fractures. *J Urol* 1992 Jan;147(1):139-43.  
<http://www.ncbi.nlm.nih.gov/pubmed/1729508>

29. Hemal AK, Dorairajan LN, Gupta NP. Posttraumatic complete and partial loss of urethra with pelvic fracture in girls: an appraisal of management. *J Urol* 2000 Jan;163(1):282-7.  
<http://www.ncbi.nlm.nih.gov/pubmed/10604377>
30. Koraitim MM. Pelvic fracture urethral injuries: the unresolved controversy. *J Urol* 1999 May;161(5):1433-41.  
<http://www.ncbi.nlm.nih.gov/pubmed/10210368>
31. Lim PH, Chng HC. Initial management of acute urethral injuries. *Br J Urol* 1989 Aug;64(2):165-8.  
<http://www.ncbi.nlm.nih.gov/pubmed/2765784>
32. McAninch JW. Traumatic injuries to the urethra. *J Trauma* 1981 Apr;21(4):291-7.  
<http://www.ncbi.nlm.nih.gov/pubmed/7218395>
33. Venn SN, Mundy AR. Immediate management of major trauma to the urinary tract. *Eur Urol* 1998;33 (Curric Urol 3.1):1-8.
34. Mundy AR. Urethroplasty for posterior urethral strictures. *Br J Urol* 1996 Aug;78(2):243-7.  
<http://www.ncbi.nlm.nih.gov/pubmed/8813921>
35. Corriere JN Jr, Harris JD. The management of urological injuries in blunt pelvic trauma. *Radiol Clin North Am* 1981 Mar;19(1):187-93.  
<http://www.ncbi.nlm.nih.gov/pubmed/7194489>
36. Antoci JP, Schiff M Jr. Bladder and urethral injuries in patients with pelvic fractures. *J Urol* 1982 Jul;128(1):25-6.  
<http://www.ncbi.nlm.nih.gov/pubmed/7109063>
37. Colapinto V. Trauma to the pelvis: urethral injury. *Clin Ortho Rel Res* 1980;Sep(151):46-55.  
<http://www.ncbi.nlm.nih.gov/pubmed/7418323>
38. Dixon CM, Hricak H, McAninch JW. Magnetic resonance imaging of traumatic posterior urethral defects and pelvic crush injuries. *J Urol* 1992 Oct;148(4):1162-5.  
<http://www.ncbi.nlm.nih.gov/pubmed/1404629>
39. Kane NM, Francis IR, Ellis JH. The value of CT in the detection of bladder and posterior urethral injuries. *Am J Roentgenol* 1989 Dec;153(6):1243-6.  
<http://www.ncbi.nlm.nih.gov/pubmed/2816642>
40. McAninch JW. Urethral injuries in female subjects following pelvic fractures (editorial comment). *J Urol* 1992;147(1):143.
41. Jackson DH, Williams JL. Urethral injury: a retrospective study. *Br J Urol* 1974 Dec;46(6):665-76.  
<http://www.ncbi.nlm.nih.gov/pubmed/4451833>
42. Cass AS, Godec CJ. Urethral injury due to external trauma. *Urology* 1978 Jun;11(6):607-11.  
<http://www.ncbi.nlm.nih.gov/pubmed/675928>
43. Grabe M, Bjerklund-Johansen T-E, Botto H. et al. EAU Guidelines on Urological Infections. Edition presented at the EAU Annual Congress 2012. EAU Guidelines Office, Arnhem, The Netherlands.  
<http://www.uroweb.org/guidelines/online-guidelines/>
44. Husmann DA, Boone TB, Wilson WT. Management of low velocity gunshot wounds to the anterior urethra: the role of primary repair versus urinary diversion alone. *J Urol* 1993 Jul;150(1):70-2.  
<http://www.ncbi.nlm.nih.gov/pubmed/8510278>
45. Armenakas NA, McAninch JW. Acute anterior urethral injuries: diagnosis and initial management. In: McAninch JW (ed). *Traumatic and reconstructive urology*. Philadelphia, PA:WB Saunders, 1996, pp. 543-550.
46. Glassberg KI, Tolete-Velcek F, Ashley R, et al. Partial tears of prostatomembranous urethra in children. *Urology* 1979 May;13(5):500-4.  
<http://www.ncbi.nlm.nih.gov/pubmed/442372>
47. Turner-Warwick R. Prevention of complications resulting from pelvic fracture urethral injuries – and from their surgical management. *Urol Clin North Am* 1989 May;16(2):335-58.  
<http://www.ncbi.nlm.nih.gov/pubmed/2652859>
48. Jordan GH. Management of membranous urethral distraction injuries via the perineal approach. In: McAninch JW (ed). *Traumatic and reconstructive urology*. Philadelphia, PA: WB Saunders, 1996, pp. 393-409.
49. Iselin CE, Webster GD. The significance of the open bladder neck associated with pelvic fracture urethral distraction defects. *J Urol* 1999 Aug;162(2):347-51.  
<http://www.ncbi.nlm.nih.gov/pubmed/10411036>
50. Mundy AR. The role of delayed primary repair in the acute management of pelvic fracture injuries of the urethra. *Br J Urol* 1991 Sep;68(3):273-6.  
<http://www.ncbi.nlm.nih.gov/pubmed/1913069>

51. Onen A, Oztürk H, Kaya M, et al. Long-term outcome of posterior urethral rupture in boys: a comparison of different surgical modalities. *Urology* 2005 Jun;65(6):1202-7.  
<http://www.ncbi.nlm.nih.gov/pubmed/15922424>
52. Berman AT, Tom L. Traumatic separation of the pubic symphysis with associated fatal rectal tear: a case report and analysis of mechanism of injury. *J Trauma* 1974 Dec;14(12):1060-7.  
<http://www.ncbi.nlm.nih.gov/pubmed/4431071>
53. Muhlbauer S, Bard RH. Early definitive urologic management of patient with crush pelvic trauma and deep perineal laceration. *Urology* 1980 Jan;15(1):56-9.  
<http://www.ncbi.nlm.nih.gov/pubmed/7352346>
54. Koraitim MM. Pelvic fracture urethral injuries: evaluation of various methods of management. *J Urol* 1996 Oct;156(4):1288-91.  
<http://www.ncbi.nlm.nih.gov/pubmed/8808856>
55. Webster GD, Mathes GL, Selli C. Prostatomembranous urethral injuries: a review of the literature and a rational approach to their management. *J Urol* 1983 Nov;130(5):898-902.  
<http://www.ncbi.nlm.nih.gov/pubmed/6355512>
56. Coffield KS, Weems WL. Experience with management of posterior urethral injury associated with pelvic fracture. *J Urol* 1977 Jun;117(6):722-4.  
<http://www.ncbi.nlm.nih.gov/pubmed/559782>
57. Follis HW, Koch MO, McDougal WS. Immediate management of prostatomembranous urethral disruptions. *J Urol* 1992 May;147(5):1259-62.  
<http://www.ncbi.nlm.nih.gov/pubmed/1569663>
58. Herschorn S, Thijssen A, Radomski SB. The value of immediate or early catheterization of the traumatized posterior urethra. *J Urol* 1992 Nov;148(5):1428-31.  
<http://www.ncbi.nlm.nih.gov/pubmed/1433542>
59. Porter JR, Takayama TK, Defalco AJ. Traumatic posterior urethral injury and early realignment using magnetic urethral catheters. *J Urol* 1997 Aug;158(2):425-30.  
<http://www.ncbi.nlm.nih.gov/pubmed/9224316>
60. Guille F, Cipolla B, Leveque JM, et al. Early endoscopic realignment of complete traumatic rupture of the posterior urethra. *Br J Urol* 1991 Aug;68(2):178-80.  
<http://www.ncbi.nlm.nih.gov/pubmed/1884146>
61. Gelbard MK, Heyman AM, Weintraub P. A technique for immediate realignment and catheterization of the disrupted prostatomembranous urethra. *J Urol* 1989 Jul;142(1):52-5.  
<http://www.ncbi.nlm.nih.gov/pubmed/2733109>
62. Turner-Warwick R. Complex traumatic posterior urethral strictures. *J Urol* 1977 Oct;118(4):564-74.  
<http://www.ncbi.nlm.nih.gov/pubmed/916051>
63. Mouraviev VB, Coburn M, Santucci RA. The treatment of posterior urethral disruption associated with pelvic fractures: comparative experience of early realignment versus delayed urethroplasty. *J Urol* 2005 Mar;173(3):873-6.  
<http://www.ncbi.nlm.nih.gov/pubmed/15711301>
64. Ragde H, McInnes GF. Transpubic repair of the severed prostatomembranous urethra. *J Urol* 1969 Mar;101(3):335-7.  
<http://www.ncbi.nlm.nih.gov/pubmed/5765881>
65. McRoberts JW, Ragde H. The severed canine posterior urethra: a study of two distinct methods of repair. *J Urol* 1970 Nov;104(5):724-9.  
<http://www.ncbi.nlm.nih.gov/pubmed/4922399>
66. Leddy LS, Vanni AJ, Wessells H, et al. Outcomes of endoscopic realignment of pelvic fracture associated urethral injuries at a level 1 trauma center. *J Urol* 2012 Jul;188(1):174-8.  
<http://www.ncbi.nlm.nih.gov/pubmed/22591965>
67. Gibson GR. Urological management and complications of fractured pelvis and ruptured urethra. *J Urol* 1974 Mar;111(3):353-5.  
<http://www.ncbi.nlm.nih.gov/pubmed/4813576>
68. Crassweller PO, Farrow GA, Robson CJ, et al. Traumatic rupture of the supramembranous urethra. *J Urol* 1977 Nov;118(5):770-1.  
<http://www.ncbi.nlm.nih.gov/pubmed/562426>
69. Malek RS, O'Dea MJ, Kelalis PP. Management of ruptured posterior urethra in childhood. *J Urol* 1977 Jan;117(1):105-9.  
<http://www.ncbi.nlm.nih.gov/pubmed/830957>
70. Cohen JK, Berg G, Carl GH, et al. Primary endoscopic realignment following posterior urethral disruption. *J Urol* 1991 Dec;146(6):1548-50.  
<http://www.ncbi.nlm.nih.gov/pubmed/1942338>

71. Melekos MD, Pantazakos A, Daouaher H, et al. Primary endourologic re-establishment of urethral continuity after disruption of prostatomembranous urethra. *Urology* 1992 Feb;39(2):135-8.  
<http://www.ncbi.nlm.nih.gov/pubmed/1736505>
72. el-Abd SA. Endoscopic treatment of posttraumatic urethral obliteration: experience in 396 patients. *J Urol* 1995 Jan;153(1):67-71.  
<http://www.ncbi.nlm.nih.gov/pubmed/7966794>
73. Gheiler EL, Frontera JR. Immediate primary realignment of prostatomembranous urethral disruptions using endourologic techniques. *Urology* 1997 Apr;49(4):596-9.  
<http://www.ncbi.nlm.nih.gov/pubmed/9111631>
74. Londergan TA, Gundersen LH, van Every MJ. Early fluoroscopic realignment for traumatic urethral injuries. *Urology* 1997 Jan;49(1):101-3.  
<http://www.ncbi.nlm.nih.gov/pubmed/9000194>
75. Elliott DS, Barrett DM. Long-term followup and evaluation of primary realignment of posterior urethral disruptions. *J Urol* 1997 Mar;157(3):814-6.  
<http://www.ncbi.nlm.nih.gov/pubmed/9072573>
76. Rehman J, Samadi D, Ricciardi R Jr, et al. Early endoscopic realignment as primary therapy for complete posterior urethral disruptions. *J Endourol* 1998 Jun;12(3):283-9.  
<http://www.ncbi.nlm.nih.gov/pubmed/9658304>
77. Sahin H, Bircan MK, Akay AF, et al. Endoscopic treatment of complete posterior urethral obliteration. *Acta Urol Belg* 1998 Dec;66(4):21-4.  
<http://www.ncbi.nlm.nih.gov/pubmed/10083629>
78. Tahan H, Randrianantenaina A, Michel F. [Treatment of complete rupture of the posterior urethra by endoscopic realignment] *Prog Urol* 1999 Jun;9(3):489-5. [Article in French]  
<http://www.ncbi.nlm.nih.gov/pubmed/10434323>
79. Jepson BR, Boullier JA, Moore RG, et al. Traumatic posterior urethral injury and early primary endoscopic realignment: evaluation of long-term follow-up. *Urology* 1999 Jun;53(6):1205-10.  
<http://www.ncbi.nlm.nih.gov/pubmed/10434323>
80. Asci R, Sarikaya S, Büyükalpelli R, et al. Voiding and sexual dysfunctions after pelvic fracture urethral injuries treated with either initial cystostomy and delayed urethroplasty or immediate primary urethral realignment. *Scand J Urol Nephrol* 1999 Aug;33(4):228-33.  
<http://www.ncbi.nlm.nih.gov/pubmed/10515084>
81. Ying-Hao S, Chuan-Liang X, Xu G, et al. Urethroscopic realignment of ruptured bulbar urethra. *J Urol* 2000 Nov;164(5):1543-5.  
<http://www.ncbi.nlm.nih.gov/pubmed/11025700>
82. Moudouni SM, Patard JJ, Manunta A, et al. Early endoscopic realignment of post-traumatic posterior urethral disruption. *Urology* 2001 Apr;57(4):628-32.  
<http://www.ncbi.nlm.nih.gov/pubmed/11306365>
83. Weems WL. Management of genitourinary injuries in patients with pelvic fractures. *Ann Surg* 1979 Jun;189(6):717-23.  
<http://www.ncbi.nlm.nih.gov/pubmed/453943>
84. Mark SD, Webster GD. Reconstruction of the failed repair of posterior urethral rupture, in McAninch JW (ed.). *Traumatic and reconstructive urology*. Philadelphia: WB Saunders, 1996, pp. 439-451.
85. Webster GD, Ramon J. Repair of pelvic fracture posterior urethral defects using an elaborated perineal approach: experience with 74 cases. *J Urol* 1991 Apr;145(4):744-8.  
<http://www.ncbi.nlm.nih.gov/pubmed/2005693>
86. Webster GD, Ramon J, Kreder KJ. Salvage posterior urethroplasty after failed initial repair of pelvic fracture membranous urethral defects. *J Urol* 1990 Dec;144(6):1370-2.  
<http://www.ncbi.nlm.nih.gov/pubmed/2231930>
87. MacDiarmid S, Rosario D, Chapple CR. The importance of accurate assessment and conservative management of the open bladder neck in patients with post-pelvic fracture membranous urethral distraction defects. *Br J Urol* 1995 Jan;75(1):65-7.  
<http://www.ncbi.nlm.nih.gov/pubmed/7850300>
88. Mundy AR. Results and complications of urethroplasty and its future. *Br J Urol* 1993 Mar;71(3):322-5.  
<http://www.ncbi.nlm.nih.gov/pubmed/8477319>
89. Koraitim MM. Posttraumatic posterior urethral strictures in children: a 20-year experience. *J Urol* 1997 Feb;157(2):641-5.  
<http://www.ncbi.nlm.nih.gov/pubmed/8996388>
90. Santucci RA, Mario LA, McAninch JW. Anastomotic urethroplasty for bulbar urethral stricture: analysis of 168 patients. *J Urol* 2002 Apr;167(4):1715-9.  
<http://www.ncbi.nlm.nih.gov/pubmed/11912394>

91. Zinman LM. The management of traumatic posterior urethral distraction defects. *J Urol* 1997 Feb; 157(2):511-2.  
<http://www.ncbi.nlm.nih.gov/pubmed/8996344>
92. Corriere JN Jr, Rudy DC, Benson GS. Voiding and erectile function after delayed one-stage repair of posterior urethral disruption in 50 men with fractured pelvis. *J Trauma* 1994 Oct;37(4):587-9.  
<http://www.ncbi.nlm.nih.gov/pubmed/7932889>
93. Flynn BJ, Delvecchio FC, Webster GD. Perineal repair of pelvic fracture urethral distraction defects: experience in 120 patients during the last 10 years. *J Urol* 2003 Nov;170(5):1877-80.  
<http://www.ncbi.nlm.nih.gov/pubmed/14532797>
94. Fiala R, Zátura F, Vrtal R. [Personal experience with treatment of posttraumatic urethral distraction defects.] *Acta Chir Orthop Traumatol Cech* 2001;68(2):99-104. [Article in Czech]  
<http://www.ncbi.nlm.nih.gov/pubmed/11706724>
95. Koraitim MM. The lessons of 145 posttraumatic posterior urethral strictures treated in 17 years. *J Urol* 1995 Jan;153(1):63-6.  
<http://www.ncbi.nlm.nih.gov/pubmed/7966793>
96. Podestá ML. Use of the perineal and perineal-abdominal (transpubic) approach for delayed management of pelvic fracture urethral obliterative strictures in children: long-term outcome. *J Urol* 1998 Jul;160(1):160-4.  
<http://www.ncbi.nlm.nih.gov/pubmed/9628640>
97. Sachse H. [Treatment of urethral stricture: transurethral slit in view using sharp section]. *Fortschr Med* 1974 Jan 10;92(1):12-5. [Article in German]  
<http://www.ncbi.nlm.nih.gov/pubmed/4820622>
98. Blandy JP. Urethral stricture. *Postgrad Med J* 1980 Jun;56(656):383-418.  
<http://www.ncbi.nlm.nih.gov/pubmed/6997851>
99. Lieberman SF, Barry JM. Retreat from transpubic urethroplasty for obliterated membranous urethral strictures. *J Urol* 1982 Aug;128(2):379-81.  
<http://www.ncbi.nlm.nih.gov/pubmed/7109114>
100. Gupta NP, Gill IS. Core-through optical internal urethrotomy in management of impassable traumatic posterior urethral strictures. *J Urol* 1986 Nov;136(5):1018-21.  
<http://www.ncbi.nlm.nih.gov/pubmed/3773060>
101. Chiou RK, Gonzalez R, Ortlip S, et al. Endoscopic treatment of posterior urethral obliteration: longterm followup and comparison with transpubic urethroplasty. *J Urol* 1988 Sep;140(3):508-11.  
<http://www.ncbi.nlm.nih.gov/pubmed/3411662>
102. Marshall FF. Endoscopic reconstruction of traumatic urethral transections. *Urol Clin North Am* 1989 May;16(2):313-8.  
<http://www.ncbi.nlm.nih.gov/pubmed/2711549>
103. Barry JM. Visual urethrotomy in the management of the obliterated membranous urethra. *Urol Clin North Am* 1989 May;16(2):319-24.  
<http://www.ncbi.nlm.nih.gov/pubmed/2711550>
104. de Vries CR, Anderson RU. Endoscopic urethroplasty: an improved technique. *J Urol* 1990 Jun;143(6): 1225-6.  
<http://www.ncbi.nlm.nih.gov/pubmed/2342187>
105. Leonard MP, Emtage J, Perez R, et al. Endoscopic management of urethral stricture: 'cut to the light' procedure. *Urology* 1990 Feb;35(2):117-20.  
<http://www.ncbi.nlm.nih.gov/pubmed/2305533>
106. Kernohan RM, Anwar KK, Johnston SR. Complete urethral stricture of the membranous urethra: a different perspective. *Br J Urol* 1990 Jan;65(1):51-4.  
<http://www.ncbi.nlm.nih.gov/pubmed/2310932>
107. Yasuda T, Yamanishi T, Isaka S, et al. Endoscopic re-establishment of membranous urethral disruption. *J Urol* 1991 May;145(5):977-9.  
<http://www.ncbi.nlm.nih.gov/pubmed/2016813>
108. Quint HJ, Stanisic TH. Above and below delayed endoscopic treatment of traumatic posterior urethral disruptions. *J Urol* 1993 Mar;149(3):484-7.  
<http://www.ncbi.nlm.nih.gov/pubmed/8437251>
109. Goel MC, Kumar M, Kapoor R. Endoscopic management of traumatic posterior urethral stricture: early results and followup. *J Urol* 1997 Jan;157(1):95-7.  
<http://www.ncbi.nlm.nih.gov/pubmed/8976224>
110. Levine J, Wessells H. Comparison of open and endoscopic treatment of posttraumatic posterior urethral strictures. *World J Surg* 2001 Dec;25(12):1597-601.  
<http://www.ncbi.nlm.nih.gov/pubmed/11775198>



111. Dogra PN, Nabi G. Core-through urethrotomy using the neodymium: YAG laser for obliterative urethral strictures after traumatic urethral disruption and/or distraction defects: long-term outcome. *J Urol* 2002 Feb;167(2Pt1):543-6.  
<http://www.ncbi.nlm.nih.gov/pubmed/11792915>
112. Pansadoro V, Emiliozzi P. Internal urethrotomy in the management of anterior urethral strictures: Long-term followup. *J Urol* 1996 Jul;156(1):73-5.  
<http://www.ncbi.nlm.nih.gov/pubmed/8648841>
113. Williams G. Stents in the lower urinary tract. *Am Urol Assoc Update Ser* 1993;12:26.
114. Milroy EJ, Chapple C, Eldin A, et al. A new treatment for urethral strictures: a permanently implanted urethral stent. *J Urol* 1989 May;141(5):1120-2.  
<http://www.ncbi.nlm.nih.gov/pubmed/2709498>
115. Baert L, Verhamme L, Van Poppel H, et al. Long-term consequences of urethral stents. *J Urol* 1993 Sep;150(3):853-5.  
<http://www.ncbi.nlm.nih.gov/pubmed/8345599>
116. Wadhwa SN, Chahal R, Hemal AK, et al. Management of obliterative posttraumatic posterior urethral strictures after failed initial urethroplasty. *J Urol* 1998 Jun;159(6):1898-902.  
<http://www.ncbi.nlm.nih.gov/pubmed/9598483>
117. Cooperberg MR, McAninch JW, Alsikafi NF, et al. Urethral reconstruction for traumatic posterior urethral disruption: outcomes of a 25-year experience. *J Urol* 2007 Nov;178(5):2006-10.  
<http://www.ncbi.nlm.nih.gov/pubmed/17869302>
118. Kashefi C, Messer K, Barden R, et al. Incidence and prevention of iatrogenic urethral injuries: *J Urol* 2008 Jun;179(6):2254-7.  
<http://www.ncbi.nlm.nih.gov/pubmed/18423712>
119. Fenton AS, Morey AF, Aviles R, et al. Anterior urethral stricture: etiology and characteristics. *Urology* 2005 Jun;65(6):1055-8.  
<http://www.ncbi.nlm.nih.gov/pubmed/15913734>
120. Wu AK, Blaschko SD, Garcia M, et al. Safer urethral catheters: how study of catheter balloon pressure and force can guide design. *BJU Int* 2012 Apr;109(7):1110-4.  
<http://www.ncbi.nlm.nih.gov/pubmed/21871052>
121. Buddha S. Complication of urethral catheterisation. *Lancet* 2005 Mar;365(9462):909.  
<http://www.ncbi.nlm.nih.gov/pubmed/15752537>
122. Hammarsten J, Lindqvist K. Suprapubic catheter following transurethral resection of the prostate: a way to decrease the number of urethral strictures and improve the outcome of operations. *J Urol* 1992 Mar;147(3):648-51.  
<http://www.ncbi.nlm.nih.gov/pubmed/1538447>
123. Thomas AZ, Giri SK, Meagher D, et al. Avoidable iatrogenic complications of urethral catheterization and inadequate intern training in a tertiary-care teaching hospital. *BJU Int* 2009 Oct;104(8):1109-12.  
<http://www.ncbi.nlm.nih.gov/pubmed/19338562>
124. Katz G, Milgalter E, Landau Y, et al. Prevention of urethral strictures following coronary artery bypass graft surgery. *Urology* 1992 May;39(5):433-5.  
<http://www.ncbi.nlm.nih.gov/pubmed/1580032>
125. Vicente J, Rosales A, Montlleó M, et al. Value of electrical dispersion as a cause of urethral stenosis after endoscopic surgery. *Eur Urol* 1992;21(4):280-3.  
<http://www.ncbi.nlm.nih.gov/pubmed/1459149>
126. Hammarsten J, Lindqvist K, Sunzel H. Urethral strictures following transurethral resection of the prostate. The role of the catheter. *Br J Urol* 1989 Apr;63(4):397-400.  
<http://www.ncbi.nlm.nih.gov/pubmed/2713622>
127. Rassweiler J, Teber D, Kuntz R, et al. Complications of transurethral resection of the prostate (TURP)--incidence, management, and prevention. *Eur Urol* 2006 Nov;50(5):969-79; discussion 980.  
<http://www.ncbi.nlm.nih.gov/pubmed/16469429>
128. Eltabey MA, Sherif H, Hussein AA. Holmium laser enucleation versus transurethral resection of the prostate. *Can J Urol* 2010 Dec;17(6):5447-52.  
<http://www.ncbi.nlm.nih.gov/pubmed/21172109>
129. Elliott SP, Meng MV, Elkin EP, et al; CaPSURE investigators. Incidence of urethral stricture after primary treatment for prostate cancer: data from CaPSURE. *J Urol* 2007 Aug;178(2):529-34.  
<http://www.ncbi.nlm.nih.gov/pubmed/17570425>
130. Park R, Martin S, Goldberg JD, et al. Anastomotic strictures following radical prostatectomy: insights into incidence, effectiveness of intervention, effect on continence, and factors predisposing to occurrence. *Urology* 2001 Apr;57(4):742-6.  
<http://www.ncbi.nlm.nih.gov/pubmed/11306394>

131. Msezane LP, Reynolds WS, Gofrit ON, et al. Bladder neck contracture after robot-assisted laparoscopic radical prostatectomy: evaluation of incidence and risk factors and impact on urinary function. *J Endourol* 2008 Jan;22(1):97-104.  
<http://www.ncbi.nlm.nih.gov/pubmed/18326071>
132. Ficarra V, Novara G, Artibani W, et al. Retropubic, laparoscopic, and robot-assisted radical prostatectomy: a systematic review and cumulative analysis of comparative studies. *Eur Urol* 2009 May;55(5):1037-63.  
<http://www.ncbi.nlm.nih.gov/pubmed/19185977>
133. Chrouser KL, Leibovich BC, Sweat SD, et al. Urinary fistulas following external radiation or permanent brachytherapy for the treatment of prostate cancer. *J Urol* 2005 Jun;173(6):1953-7.  
<http://www.ncbi.nlm.nih.gov/pubmed/15879789>
134. Marguet C, Raj GV, Brashears JH, et al. Rectourethral fistula after combination radiotherapy for prostate cancer. *Urology* 2007 May;69(5):898-901.  
<http://www.ncbi.nlm.nih.gov/pubmed/17482930>
135. Gómez-Iturriaga Piña A, Crook J, Borg J, et al. Median 5 year follow-up of 125iodine brachytherapy as monotherapy in men aged <or=55 years with favorable prostate cancer. *Urology* 2010 Jun;75(6):1412-6.  
<http://www.ncbi.nlm.nih.gov/pubmed/20035986>
136. Fonteyne V, Villeirs G, Lumen N, et al. Urinary toxicity after high dose intensity modulated radiotherapy as primary therapy for prostate cancer. *Radiother Oncol* 2009 Jul;92(1):42-7.  
<http://www.ncbi.nlm.nih.gov/pubmed/19356817>
137. Shelley M, Wilt TJ, Coles B, et al. Cryotherapy for localised prostate cancer. *Cochrane Database Syst Rev* 2007 Jul 18;(3):CD005010.  
<http://www.ncbi.nlm.nih.gov/pubmed/17636783>
138. Polat O, Gül O, Aksoy Y, et al. Iatrogenic injuries to ureter, bladder and urethra during abdominal and pelvic operations. *Int Urol Nephrol* 1997;29(1):13-8.  
<http://www.ncbi.nlm.nih.gov/pubmed/9203032>
139. Hautmann RE, de Petriconi RC, Volkmer BG. 25 years of experience with 1,000 neobladders: long-term complications. *J Urol* 2011 Jun;185(6):2207-12.  
<http://www.ncbi.nlm.nih.gov/pubmed/21497841>
140. Hadjizacharia P, Inaba K, Teixeira PG, et al. Evaluation of immediate endoscopic realignment as a treatment modality for traumatic urethral injuries. *J Trauma* 2008 Jun;64(6):1443-9.  
<http://www.ncbi.nlm.nih.gov/pubmed/18545107>
141. Rieder J, Brusky J, Tran V, et al. Review of intentionally self-inflicted, accidental and iatrogenic foreign objects in the genitourinary tract. *Urol Int.* 2010;84(4):471-5.  
<http://www.ncbi.nlm.nih.gov/pubmed/20224259>
142. Gökalp A, Yildirim I, Aydur E, et al. How to manage acute urethral false passage due to intermittent catheterization in spinal cord injured patients who refused insertion of an indwelling catheter. *J Urol* 2003 Jan;169(1):203-6.  
<http://www.ncbi.nlm.nih.gov/pubmed/12478136>
143. Maheshwari PN, Shah HN. Immediate endoscopic management of complete iatrogenic anterior urethral injuries: a case series with long-term results. *BMC Urol* 2005 Nov;5:13.  
<http://www.ncbi.nlm.nih.gov/pubmed/16281970>
144. Pansadoro V, Emiliozzi P. Iatrogenic prostatic urethral strictures: classification and endoscopic treatment. *Urology* 1999 Apr;53(4):784-9.  
<http://www.ncbi.nlm.nih.gov/pubmed/10197857>

## 6. GENITAL TRAUMA

### 6.1 Introduction and background

Genitourinary trauma is seen in both sexes and in all age groups. Of all genito-urinary injuries, 1/3rd to 2/3rds involve the external genitalia (1). Genital trauma is much more common in males (especially between the ages of 15 and 40) than in females. This is due to anatomical differences, increased frequency of road traffic accidents and more frequent participation in physical sports, violent crime, and war-fighting.

Genital trauma is commonly caused by blunt injuries (80%). The risk of associated injuries to neighbouring organs (bladder, urethra, vagina, rectum and bowel) after blunt trauma is higher in females than in males. In

males, blunt genital trauma frequently occurs unilaterally. Only 1% present as bilateral scrotal or testicular injuries (2).

Any kind of contact sport, without the use of necessary protective aids, may be associated with genital trauma. Off-road bicycling and motorbike riding, especially on bikes with a dominant petrol tank, rugby football and hockey are all activities which have been associated with blunt testicular trauma (3-6).

Penetrating injuries account for 20% of genito-urinary trauma and 40-60% of all penetrating genitourinary lesions involve the external genitalia (1,7,8). 35% of all genito-urinary gunshot wounds involve the genitalia (2). In a recent series of wartime genito-urinary injuries 71.5% of 361 operations involved the external genitalia and the majority of trauma was due to Improvised Explosive Devices (IEDs) and other explosive ordinance with a smaller number of gunshot injuries (9). An increase in domestic violence has led to an increase in gunshot and stab wounds over the last several years (10-13). In both males and females, penetrating genital injuries occur with other associated injuries in 70% of patients. In males, penetrating scrotal injuries affect both testes in 30% of cases (2,14) cf. blunt scrotal injuries.

Self-mutilation of the external genitalia has also been reported in psychotic patients and transsexuals (15). Genital burns are rare in isolation, usually due to industrial flame or chemicals in adults and all but the full thickness type are treated conservatively (16). Both male and female genital piercing may also cause unexpected genital trauma (17). This was significantly higher than the risk in the normal population. Although there is an increased risk of Hep B and C risk in genital injured patients, there is no higher incidence of STIs found in the population with controlled, self-directed trauma in the form of genital piercing (17).

## **6.2 General Principles and pathophysiology**

In genital trauma, a urinalysis should be performed. The presence of macro- and or microhaematuria requires a retrograde urethrogram in males. In females, flexible or rigid cystoscopy has been recommended to exclude urethral and bladder injury (18,19). In women with genital injuries and blood at the vaginal introitus, further gynaecologic investigation is needed to exclude vaginal injuries (19). The potential for significant injury should never be discounted in those patients who also may have blood in the vaginal vault from menstruation. Complete vaginal inspection with specula is mandatory. Depending on the nature of the injury, this may require sedation or general anaesthesia to be completed comfortably.

### **6.2.1 Gunshot wounds**

In patients with gunshot wounds to the genitals several pieces of additional information will be useful – in particular the range, calibre and type of weapon. As high-velocity missiles transmit large amounts of energy to the tissues and can produce trauma to structures outwith the wound track by creating an expansive cavity of sub-atmospheric pressure which then collapses and in so doing, creates shear forces and induction of other foreign bodies and (usually) infected material (1).

### **6.2.2 Bites**

#### *Animal*

Although animal bites are common, bites injuring the external genital are rare. Wounds are usually minor, but have a risk of wound infection. The most common bacterial infection by a dog bite is *Pasturella Multicida*, which accounts for up to 50% of infections (20). Other commonly involved organisms are *Escherichia coli*, *Streptococcus viridans*, *Staphylococcus aureus*, *Eikenella corrodens*, *Capnocytophaga canimorsus* *Veillonella parvula*, *Bacteroides* and *Fusobacterium spp.* (15,20,21).

The first choice of antibiotics is penicillin-amoxiclavulanic acid followed by doxycycline, cephalosporine or erythromycine for 10-14 days (22-24). After any animal bite, one has to consider the possibility of rabies infection. In cases where rabies is locally present, vaccination must be given to prevent life-threatening infection (25). Besides vaccination, local wound management is an essential part of post-exposure rabies prophylaxis. If rabies infection is suspected, vaccination should be considered in relation to the animal involved, specific nature of the wound and attack (provoked/unprovoked) and the appearance of the animal (aggressive, foam at the mouth). In high risk patients, vaccination with human rabies immunoglobulin and human diploid cell vaccine is recommended (25,26).

#### *Human*

Human bites are much less common but should be considered especially in risk groups. Since transmission of viral diseases may occur, risk assessment should be made and, if appropriate, hepatitis B vaccine/ immunoglobulin and/or HIV post-exposure prophylaxis offered. For further details see Guidelines for the Management of Human Bite Injuries (27).

### 6.2.3 **Sexual Assault.**

Genital injury is seen frequently (42%) after sexual abuse, and must be considered when such injuries present at any age (28). In these cases, the extraordinary emotional situation of the patient must be considered and the privacy of the patient respected. In suspicious cases, gynaecological and forensic support and advice is necessary. Swabs or vaginal smears should be taken for detection of spermatozoa (29) and local legal protocols followed closely. A thorough history and examination (in some cases under anaesthesia), photo documentation, and identification of forensic material may be important. In a recent report, only 38% of the forensic samples tested positive for an ejaculate and/or sperm. This may be due to delayed presentation or lack of vaginal/anal ejaculation (30,31).

## **Organ specific genital trauma**

### **6.3 Penile Trauma**

#### 6.3.1 **Blunt penile trauma**

Blunt trauma to the flaccid penis does not usually cause tearing of the tunica. In these cases, only subcutaneous haematoma with intact tunica albuginea may be seen.

##### 6.3.1.1 *Penile Fracture*

The most important and common presentation of blunt penile trauma is in penile fracture. This results from trauma to the erect penis during sexual intercourse, masturbation, rolling over in bed (rarely) and as a result of self-inflicted bending to produce detumescence in some Middle Eastern Cultures – a practice known as taqaandan (which, when translated, means “to click”) (32).

The most common mechanism of injury is when the penis slips out of the vagina and strikes against the symphysis pubis or perineum. This most frequently (60%) occurs during consensual intercourse (33), and more prevalent when the partner is on top. Penile fracture is caused by rupture of the cavernosal tunica albuginea, and may be associated with subcutaneous haematoma, and lesions of the corpus spongiosum or urethra in 10-22% (34,35).

The thickness of the tunica albuginea in the flaccid state (approximately 2 mm) decreases in erection to 0.25-0.5mm, and is therefore more vulnerable to traumatic injury (36,37).

Penile fracture is associated with a sudden cracking or popping sound, pain and immediate detumescence. Local swelling of the penile shaft develops quickly, due to enlarging haematoma. Bleeding may spread along the fascial layers of the penile shaft and extend to the lower abdominal wall if Buck's fascia is also ruptured. The rupture of the tunica may be palpable.

A thorough history and examination usually confirm the diagnosis, but in some cases imaging may be useful. Cavernosography, USS (ultrasound scanning) or MRI (38-40) can identify lacerations of the tunica albuginea in unclear cases (41), or provide reassurance that the tunica is intact. If there is suspicion of a concomitant urethral injury, a RUG (retrograde urethrogram) may be performed but flexible cystoscopy under anaesthesia during exploration/repair is more usually employed.

Subcutaneous haematoma, without associated rupture of the cavernosal tunica albuginea does not require surgical intervention. In these cases, nonsteroidal analgesics and ice-packs are recommended (8). Less severe penile injuries can be distinguished from penile fracture, as penile fracture is classically associated with rapid post-traumatic detumescence.

In penile fracture, early surgical intervention with closure of the tunica albuginea is recommended. The approach is usually by a circumferential incision proximal to the coronal sulcus to deglove the penis entirely. Increasingly local longitudinal incisions centred on the area of fracture are employed and further localisation may be gained with a flexible cystoscopy prior to incision if urethral trauma is suspected and proven. Closure can be obtained by using absorbable sutures, with good long-term outcome and protection of potency. Post-operative complications were reported in 9%, including superficial wound infection and impotence in 1.3% (33,42). Conservative management of penile fracture is not recommended. It increases complications such as penile abscess, missed urethral disruption, penile curvature, and persistent haematoma requiring delayed surgical intervention (42). Late complications after conservative management were fibrosis and angulations in 35% and impotence in up to 62% (33,42).

#### 6.3.2 **Penetrating penile trauma**

Penetrating penile trauma is rarely seen in isolation. Most cases are associated with multiple injuries. The

causes of penetrating penile trauma are gunshot/knife injury, animal or human bites, assault and industrial or self-inflicted mutilation/avulsion/amputation.

Non-operative management is recommended in small superficial injuries with intact Buck's fascia (8). In more significant penetrating penile injuries surgical exploration and conservative debridement of necrotic tissue is recommended in most severe injuries. Even in extended injuries of the penis, primary alignment of the disrupted tissues may allow for acceptable healing because of the robust penile blood supply (15).

Because of the elasticity of genital skin, loss of only a moderate amount of penile skin is usually manageable, although in extensive injuries when significant skin loss is encountered the management is more difficult. The tissue chosen for reconstruction following trauma needs to provide good coverage, and be suitable for reconstruction. Split-thickness skin grafting provides good coverage and dependable take that is reproducible and durable, but these grafts contract more than full-thickness skin grafts and their use on the shaft should be kept to a minimum. McAninch et al. recommended the use of a skin graft thickness of at least 0.015 inch (0.4 mm) in order to reduce the risk of contraction (15). Full thickness skin grafting onto the penile shaft gives less contracture, a better cosmetic appearance and more resistance to trauma from intercourse, when eventually re-established (43) The donor site may be taken from the abdomen, buttock, thigh or axilla - chosen according to surgeon preference and injury pattern.

The principles of care are debridement of devitalised tissue with the preservation of as much viable tissue as possible, haemostasis, diversion of urine in selected cases and the removal of foreign bodies. Tissues of questionable viability may be left for subsequent definitive surgery. Subsequent immediate or delayed repair is needed depending on the injury and extent of tissue damage, and usually takes place 4–6 weeks after trauma occurrence.

If there has been extensive destruction of deeper tissues, or if later prosthetic placement is being considered, skin flaps, with their secure vascular supply can be employed. The surgical approach will be dependent upon the site and extent of the injury, but a sub coronal incision with penile degloving usually gives good exposure. A defect in the tunica albuginea can be closed primarily, after copious irrigation. If there is too much tissue loss, the defect can be repaired with a patch (either from autologous saphenous vein or xenograft), either initially or delayed. If a concomitant urethral injury is suspected, a pre- or perioperative urethrogram or cystoscopy is useful in the diagnosis and localisation of any urethral involvement.

### **6.3.3 Penile avulsion injuries and amputation**

Most of these injuries are self-inflicted, but some are a result of industrial accidents or assault. The acute management involves the resuscitation of the patient (who might be compromised from blood loss) and preparation for the surgical re-implantation of the penis if it has been recovered and not too badly damaged. Surgical re-implantation should be considered for all patients, and should be performed within 24 h of amputation. If the injury occurred during a psychotic episode, early psychiatric advice and support should be sought.

The severed penis should be washed with sterile saline, wrapped in saline-soaked gauze, placed in a sterile bag and immersed in iced water. The penis must not come into direct contact with the ice. A pressure dressing or a tourniquet should be placed around the penile stump to prevent excessive blood loss. Reattachment can be achieved in a non-microsurgical way, but this technique gives a higher postoperative urethral stricture rate and more problems with loss of sensation. The best results are seen with microsurgical re-implantation. Firstly the corpora cavernosa and urethra are aligned and repaired, and then the dorsal penile arteries, the dorsal vein and the dorsal nerves are repaired with the use of an operating microscope. The cavernosal arteries are generally too small to anastomose. The fascia and skin are closed in layers, and both a urethral and a suprapubic catheter placed. If the severed penis cannot be found, or is unsuitable for reattachment, then the end should be closed as if for a partial penectomy. Later reconstruction may be employed to lengthen the penis (e.g suspensory ligament division and v-y plasty, pseudo-glans formation with split-thickness skin grafting etc.)

A delayed major reconstructive procedure – phalloplasty (either radial artery or pubic) is sometimes required for injuries which leave very little or no functioning penile stump.

## **6.4 Scrotal Trauma**

### **6.4.1 Blunt scrotal trauma**

Blunt trauma to the scrotum can cause testicular dislocation, testicular haematocoele, testicular rupture and/or scrotal haematoma.

#### 6.4.1.1 Testicular dislocation

Traumatic dislocation of the testicle occurs rarely. It is most common in victims of MVAs or auto-pedestrian accidents (44-47). Bilateral dislocation of the testes has been reported in up to 25% of cases (47). It can be either a subcutaneous dislocation with epifascial displacement of the testis or an internal dislocation. In the latter the testis is positioned in the superficial external inguinal ring, inguinal canal or abdominal cavity. Traumatic dislocation of the testis is treated by manual replacement and secondary orchidopexy. If primary manual reposition cannot be performed, immediate orchidopexy is indicated.

#### 6.4.1.2 Haematocoele

Conservative management is recommended in haematocoeles smaller than three times the size of the contralateral testis (10). In large haematocoeles, non-operative management often fails, and often requires delayed surgery (> 3 days). These patients suffer from a higher rate of orchiectomy than acutely-operated patients, even in non-ruptured testis (2,15,48-50). Early surgical intervention resulted in > 90% preservation of the testis whereas delayed surgery necessitates orchiectomy in 45-55% (48). Additionally, non-operative management is associated with prolonged hospital stays. Large haematocoeles should be treated surgically, irrespective of testicle contusion or rupture. At the very least, the blood-clot should be evacuated from the tunica vaginalis sac to relieve disability and hasten recovery. Patients initially treated non-operatively may need delayed surgery if they develop infection or undue pain.

#### 6.4.1.3 Testicular Rupture

Testicular rupture is found in approximately 50% of cases of direct blunt scrotal trauma (48). It may occur under intense, traumatic compression of the testis against the inferior pubic ramus or symphysis, resulting in a rupture of the tunica albuginea of the testis. Wasko and Goldstein estimated that a force of approximately 50kg is necessary to cause testicular rupture (51). Testicular rupture is associated with immediate pain, nausea, vomiting, and sometimes fainting. The hemiscrotum is tender, swollen, and ecchymotic. The testis itself may be difficult to palpate. High-resolution, real-time ultrasonography with a high resolution probe (minimum 7.5MHz or higher) should be performed to determine intra- and/or extratesticular haematoma, testicular contusion, or rupture (52-60). The literature is contradictory as to the real usefulness of US over exam alone. Some studies report convincing results with a specificity of up to 98.6% (15,52,57,58,61). Others reported poor specificity (78%) and sensitivity (28%) for differentiation of testicular rupture or haematocoele, and accuracy as low as 56% (55). Colour Doppler-duplex ultrasonography may provide useful information when used to evaluate testicular perfusion. In case of inconclusive scrotal sonography, testicular CT or MRI may be helpful (62). However, these techniques did not specifically increase the detection of testicular rupture. It may be most prudent to surgically explore these equivocal patients. If imaging studies cannot definitively exclude testicular rupture, surgical exploration is indicated. This involves exploration with evacuation of clot and haematoma, excision of any necrotic testicular tubules and closure of the tunica albuginea usually with running absorbable sutures (such as 3/0 vicryl). This results in a high rate of testicular preservation and normal endocrine function.

#### 6.4.2 Penetrating scrotal trauma

Penetrating injuries to the scrotum require surgical exploration with conservative debridement of non-viable tissue. Depending on the extent of the injury, primary reconstruction of testis and scrotum can be performed in most cases. In complete disruption of the spermatic cord, realignment without vaso-vasostomy may be considered if surgically feasible (63). Staged secondary microsurgical vaso-vasostomy can be performed after rehabilitation, although there are only a few cases reported (63). If there is extensive destruction of the tunica albuginea, mobilisation of a free tunica vaginalis flap can be performed for testicular closure. If the patient is unstable or reconstruction cannot be achieved, orchiectomy is indicated.

Prophylactic antibiotics are recommended by experts after scrotal penetrating trauma, although data to support this approach is lacking. Tetanus prophylaxis is mandatory. Postoperative complications were reported in 8% of patients who underwent testicular repair after penetrating trauma (8).

Extended laceration of scrotal skin requires surgical intervention for skin closure. Due to the elasticity of the scrotum, most defects can be primarily closed, even if the lacerated skin is only minimally attached to the scrotum (15). Local wound management with extensive initial wound debridement and washout is important for scrotal convalescence.

In IED blast injury, the extensive loss of genital tissue often requires complex and staged reconstructive surgical procedures (9).

## 6.5 Genital Trauma in Females

In females with blunt trauma to the external genitalia, imaging studies of the pelvis with US, CT, or MRI should be performed since additional injuries and extensive intrapelvic haematoma are frequently found (19,29).

### 6.5.1 Blunt Vulvar Injuries

Blunt trauma to the vulva is rarely reported and commonly present as a large haematoma. The incidence of traumatic vulvar haematomas after vaginal deliveries has been reported as 1 in 310 deliveries (64). The frequency in non-obstetric vulvar haematomas is even lower, with only individual cases reported (65). Although blunt trauma to the female external genitals is rarely reported, the presence of vulvar haematoma is closely related to an increased risk of associated vaginal, pelvic or abdominal injuries. Goldman et al. reported that blunt injuries of the vulva and vagina were associated with pelvic trauma in 30%, after consensual intercourse in 25%, sexual assault in 20%, and other blunt trauma in 15% (18).

However, in contrast to men, blunt vulvar or perineal trauma may be associated with voiding problems. Bladder catheterisation will usually be required. Vulvar haematomas usually do not require surgical intervention, although they can cause significant blood loss, even requiring red blood cell transfusions. Data are scarce (18,19,29,65), but in haemodynamically stable women, non-steroidal anti-inflammatory medication and cold packs are used. In massive vulvar haematoma or haemodynamically unstable patients, surgical intervention, lavage and drainage is indicated (66).

Antibiotics are recommended by experts after major vulvar trauma, but data supporting this approach are lacking. It is important to emphasise that vulvar haematoma and/or blood at the vaginal introitus are an indication for vaginal exploration under sedation or general anaesthesia in order to identify possible associated vaginal and/or rectal injuries (19). Flexible or rigid cystoscopy has been recommended to exclude urethral and bladder injury (18,19). In case of vulvar laceration, suturing after conservative debridement is indicated. If there are associated injuries to the vagina, these can be repaired immediately by primary suturing. Additional injuries to the bladder, rectum or bowel may require laparotomy for closure. The rectal injuries may also require colostomy.

## 6.6 References

1. Brandes SB, Buckman RF, Chelsky MJ, et al. External genitalia gunshot wounds: a ten-year experience with fifty-six cases. *J Trauma* 1995 Aug;39(2):266-71.  
<http://www.ncbi.nlm.nih.gov/pubmed/7674395>
2. Monga M, Hellstrom WJ. Testicular Trauma. *Adolesc Med* 1996 Feb;7(1):141-148.  
<http://www.ncbi.nlm.nih.gov/pubmed/10359963>
3. Frauscher F, Klauser A, Stenzl A, et al. US findings in the scrotum of extreme mountain bikers. *Radiology* 2001 May;219(2):427-31.  
<http://www.ncbi.nlm.nih.gov/pubmed/11323467>
4. de Peretti F, Cambas PM, Veneau B, et al. [Fuel tanks of motorcycles. Role in severe trauma of the pelvis.] *Presse Med* 1993 Jan;22(2):61-3. [Article in French]  
<http://www.ncbi.nlm.nih.gov/pubmed/8493205>
5. Herrmann B, Crawford J. Genital injuries in prepubertal girls from inline skating accidents. *Pediatrics* 2002 Aug;110(2 Pt 1):e16.  
<http://www.ncbi.nlm.nih.gov/pubmed/12165615>
6. Lawson JS, Rotem T, Wilson SF. Catastrophic injuries to the eyes and testicles in footballers. *Med J Aust* 1995 Sep;163(5):242-4.  
<http://www.ncbi.nlm.nih.gov/pubmed/7565208>
7. Selikowitz SM. Penetrating high-velocity genitourinary injuries. Part I. Statistics mechanism and renal wounds. *Urology* 1977 Apr;9(4):371-6.  
<http://www.ncbi.nlm.nih.gov/pubmed/855062>
8. Phonsombat S, Master VA, McAninch JW. Penetrating external genitalia trauma: a 30-year single institution experience. *J Urology* 2008 Jul;180(1):192-5.  
<http://www.ncbi.nlm.nih.gov/pubmed/18499189>
9. Hudak SJ, Hakim S. Operative management of wartime genitourinary injuries at Balad Air Force Theater Hospital, 2005 to 2008. *J Urol* 2009 Jul;182(1):180-3.  
<http://www.ncbi.nlm.nih.gov/pubmed/19450817>
10. Tiguert R, Harb JF, Hurley PM, et al. Management of shotgun injuries to the pelvis and lower genitourinary system. *Urology* 2000 Feb;55(2):193-7.  
<http://www.ncbi.nlm.nih.gov/pubmed/10688077>

11. Cline KJ, Mata JA, Venable DD, et al. Penetrating trauma to the male external genitalia. *J Trauma* 1998 May;44(3):492-4 .  
<http://www.ncbi.nlm.nih.gov/pubmed/9529176>
12. Jolly BB, Sharma SK, Vaidyanathan S, et al. Gunshot wounds of the male external genitalia. *Urol Int* 1994;53(2):92-6.  
<http://www.ncbi.nlm.nih.gov/pubmed/7801424>
13. Bertini JE Jr, Corriere JN Jr. The etiology and management of genital injuries. *J Trauma* 1988 Aug;28(8):1278-81.  
<http://www.ncbi.nlm.nih.gov/pubmed/3411650>
14. Cass AS, Ferrara L, Wolpert J, et al. Bilateral testicular injury from external trauma. *J Urol* 1988 Dec;140(6):1435-6.  
<http://www.ncbi.nlm.nih.gov/pubmed/3193512>
- 15.. McAninch JW, Kahn RI, Jeffrey RB, et al. Major traumatic and septic genital injuries. *J Trauma* 1984 Apr;24(4):291-8.  
<http://www.ncbi.nlm.nih.gov/pubmed/6368854>
16. Michielsen D, Van Hee R, Neetens C, et al. Burns to the genitalia and the perineum. *J Urol* 1998 Feb;159(2):418-9.  
<http://www.ncbi.nlm.nih.gov/pubmed/9649253>
17. Nelius T, Armstrong ML, Rinard K, et al. Genital piercings: diagnostic and therapeutic implications for urologists. *Urology* 2011 Nov;78(5):998-1007.  
<http://www.ncbi.nlm.nih.gov/pubmed/22054364>
18. Goldman HB, Idom CB Jr, Dmochowski RR. Traumatic injuries of the female external genitalia and their association with urological injuries. *J Urol* 1998 Mar;159(3):956-9.  
<http://www.ncbi.nlm.nih.gov/pubmed/9474191>
19. Husmann DA. Editorial Comment. *J Urol* 1998;159:959
20. Donovan JF, Kaplan WE. The therapy of genital trauma by dog bite. *J Urol* 1989 May;141(5):1163-5.  
<http://www.ncbi.nlm.nih.gov/pubmed/2651716>
21. Presutti RJ. Prevention and treatment of dog bites. *Am Fam Physician* 2001 Apr; 63(8):1567-72.  
<http://www.ncbi.nlm.nih.gov/pubmed/11327433>
22. Lewis KT, Stiles M. Management of cat and dog bites. *Am Fam Physician* 1995 Aug;52(2):479-85,489-90.  
<http://www.ncbi.nlm.nih.gov/pubmed/7625323>
23. Presutti RJ. Bite wounds. Early treatment and prophylaxis against infectious complications. *Postgrad Med* 1997 Apr;101(4):243-4, 246-52, 254.  
<http://www.ncbi.nlm.nih.gov/pubmed/9126216>
24. Talan DA, Citron DM, Abrahamian FM, et al. Bacteriologic analysis of infected dog and cat bites. Emergency Medicine Animal Bite Infection Study Group. *N Engl J Med* 1999 Jan;340(2):85-92.  
<http://www.ncbi.nlm.nih.gov/pubmed/9887159>
25. Dreesen DW, Hanlon CA. Current recommendations for the prophylaxis and treatment of rabies. *Drugs* 1998 Nov;56(5):801-9.  
<http://www.ncbi.nlm.nih.gov/pubmed/9829154>
26. Anderson CR. Animal bites. Guidelines to current management. *Postgrad Med* 1992 Jul;92(1):134-6,139-46,149.  
<http://www.ncbi.nlm.nih.gov/pubmed/1614928>
27. Guidelines for the Management of Human Bite Injuries. Health Protection Agency North West 2007.  
[http://www.hpa.org.uk/web/HPAwebFile/HPAweb\\_C/1194947350692](http://www.hpa.org.uk/web/HPAwebFile/HPAweb_C/1194947350692)
28. McGregor MJ, Du Mont J, Myhr TL. Sexual assault forensic medical examination: is evidence related to successful prosecution? *Ann Emerg Med* 2002 Jun;39(6):639-47.  
<http://www.ncbi.nlm.nih.gov/pubmed/12023707>
29. Okur H, Küçükaydin M, Kazez A, et al. Genitourinary tract injuries in girls. *Br J Urol* 1996 Sep;78(3): 446-9.  
<http://www.ncbi.nlm.nih.gov/pubmed/8881959>
30. Dardamissis E, Gee A, Kaczmariski E, et al on behalf of the North West Policy Group. Guidance for healthcare professionals on dealing with injuries where teeth break the skin. Health Care Protection Agency, October 2007.  
[http://www.hpa.org.uk/web/HPAwebFile/HPAweb\\_C/1194947350692](http://www.hpa.org.uk/web/HPAwebFile/HPAweb_C/1194947350692)
31. A national protocol for sexual assault medical forensic examinations adults/adolescents. U.S. Dept of Justice. Office on Violence Against Women, September 2004.  
<http://www.ncjrs.gov/pdffiles1/ovw/206554.pdf>



32. Zargooshi J. Penile fracture in Kermanshah, Iran: report of 172 cases. *J Urol* 2000 Aug;164(2):364-6.  
<http://www.ncbi.nlm.nih.gov/pubmed/10893586>
33. Haas CA, Brown SL, Spirnak JP. Penile fracture and testicular rupture. *World J Urol* 1999 Apr;17(2):101-6.  
<http://www.ncbi.nlm.nih.gov/pubmed/10367369>
34. Nicolaisen GS, Melamud A, Williams RD, et al. Rupture of the corpus cavernosum: surgical management. *J Urol* 1983 Nov;130(5):917-9.  
<http://www.ncbi.nlm.nih.gov/pubmed/6632099>
35. Tsang T, Demby AM. Penile fracture with urethral injury. *J Urol* 1992 Feb;147(2):466-8.  
<http://www.ncbi.nlm.nih.gov/pubmed/1732623>
36. Mydlo JH, Hayyeri M, Macchia RJ. Urethrography and cavernosography imaging in a small series of penile fractures: a comparison with surgical findings. *Urology* 1998 Apr;51(4):616-9.  
<http://www.ncbi.nlm.nih.gov/pubmed/9586616>
37. Lee SH, Bak CW, Choi MH, et al. Trauma to male genital organs: a 10-year review of 156 patients, including 118 treated by surgery. *BJU Int* 2008 Jan;101(2):211-5.  
<http://www.ncbi.nlm.nih.gov/pubmed/17922859>
38. Karadeniz T, Topsakal M, Ariman A, et al. Penile fracture: differential diagnosis, management and outcome. *Br J Urol* 1996 Feb;77(2):279-81.  
<http://www.ncbi.nlm.nih.gov/pubmed/8800899>
39. Pretorius ES, Siegelman ES, Ramchandani P, et al. MR imaging of the penis. *Radiographics* 2001 Oct;21 Spec No:S283-98, discussion S298-9.  
<http://www.ncbi.nlm.nih.gov/pubmed/11598264>
40. Fedel M, Venz S, Andreessen R, et al. The value of magnetic resonance imaging in the diagnosis of suspected penile fracture with atypical clinical findings. *J Urol* 1996 Jun;155(6):1924-7.  
<http://www.ncbi.nlm.nih.gov/pubmed/8618289>
41. Uder M, Gohl D, Takahashi M, et al. MRI of penile fracture: diagnosis and therapeutic follow-up. *Eur Radiol* 2002 Jan;12(1):113-20.  
<http://www.ncbi.nlm.nih.gov/pubmed/11868085>
42. Orvis BR, McAninch JW. Penile rupture. *Urol Clin North Am* 1989 May;16(2):369-75.  
<http://www.ncbi.nlm.nih.gov/pubmed/2652861>
43. Summerton DJ, Campbell A, Minhas S, et al. Reconstructive surgery in penile trauma and cancer. *Nat Clin Pract Urol* 2005 Aug;2(8):391-7.  
<http://www.ncbi.nlm.nih.gov/pubmed/16474736>
44. Lee JY, Cass AS, Streitz JM. Traumatic dislocation of testes and bladder rupture. *Urology* 1992 Dec;40(6):506-8.  
<http://www.ncbi.nlm.nih.gov/pubmed/1466102>
45. Shefi S, Mor Y, Dotan ZA, et al. Traumatic testicular dislocation: a case report and review of published reports. *Urology* 1999 Oct;54(4):744.  
<http://www.ncbi.nlm.nih.gov/pubmed/10754145>
46. Pollen JJ, Funckes C. Traumatic dislocation of the testes. *J Trauma* 1982 Mar;22(3):247-9.  
<http://www.ncbi.nlm.nih.gov/pubmed/7069812>
47. Nagarajan VP, Pranikoff K, Imahori SC, et al. Traumatic dislocation of testis. *Urology* 1983 Nov;22(5):521-4.  
<http://www.ncbi.nlm.nih.gov/pubmed/6649208>
48. Cass AS, Luxenberg M. Testicular injuries. *Urology* 1991 Jun;37(6):528-30.  
<http://www.ncbi.nlm.nih.gov/pubmed/2038785>
49. Altarac S. Management of 53 cases of testicular trauma. *Eur Urol* 1994;25(2):119-23.  
<http://www.ncbi.nlm.nih.gov/pubmed/8137851>
50. Cass AS, Luxenberg M. Value of early operation in blunt testicular contusion with hematocele. *J Urol* 1988 Apr;139(4):746-7.  
<http://www.ncbi.nlm.nih.gov/pubmed/3352037>
51. Wasko R, Goldstein AG. Traumatic rupture of the testicle. *J Urol* 1966 May;95(5):721-3.  
<http://www.ncbi.nlm.nih.gov/pubmed/5935538>
52. Pavlica P, Barozzi L. Imaging of the acute scrotum. *Eur Radiol* 2001;11(2):220-8.  
<http://www.ncbi.nlm.nih.gov/pubmed/11218018>
53. Micallef M, Ahmad I, Ramesh N, et al. Ultrasound features of blunt testicular injury. *Injury* 2001 Jan;32(1):23-6.  
<http://www.ncbi.nlm.nih.gov/pubmed/11164397>

54. Patil MG, Onuora VC. The value of ultrasound in the evaluation of patients with blunt scrotal trauma. *Injury* 1994 Apr;25(3):177-8.  
<http://www.ncbi.nlm.nih.gov/pubmed/8168890>
55. Corrales JG, Corbel L, Cipolla B, et al. Accuracy of ultrasound diagnosis after blunt testicular trauma. *J Urol* 1993 Dec;150(6):1834-6.  
<http://www.ncbi.nlm.nih.gov/pubmed/8080482>
56. Mulhall JP, Gabram SG, Jacobs LM. Emergency management of blunt testicular trauma. *Acad Emerg Med* 1995 Jul;2(7):639-43.  
<http://www.ncbi.nlm.nih.gov/pubmed/8521212>
57. Martinez-Piñero L Jr, Cerezo E, Cozar JM, et al. Value of testicular ultrasound in the evaluation of blunt scrotal trauma without haematocele. *Br J Urol* 1992 Mar;69(3):286-90.  
<http://www.ncbi.nlm.nih.gov/pubmed/1568102>
58. Fournier GR Jr, Laing FC, McAninch JW. Scrotal ultrasonography and the management of testicular trauma. *Urol Clin North Am* 1989 May;16(2):377-85.  
<http://www.ncbi.nlm.nih.gov/pubmed/2652862>
59. Kratzik C, Hainz A, Kuber W, et al. Has ultrasound influenced the therapy concept of blunt scrotal trauma? *J Urol* 1989 Nov;142(5):1243-6.  
<http://www.ncbi.nlm.nih.gov/pubmed/2681835>
60. Andipa E, Liberopoulos K, Asvestis C. Magnetic resonance imaging and ultrasound evaluation of penile and testicular masses. *World J Urol* 2004 Nov;22(5):382-91.  
<http://www.ncbi.nlm.nih.gov/pubmed/15300391>
61. Lee SH, Bak CW, Choi MH, et al. Trauma to male genital organs: a 10-year review of 156 patients, including 118 treated by surgery. *BJU Int* 2008 Jan;101(2):211-5.  
<http://www.ncbi.nlm.nih.gov/pubmed/17922859>
62. Muglia V, Tucci S Jr, Elias J Jr, et al. Magnetic resonance imaging of scrotal diseases: when it makes the difference. *Urology* 2002 Mar;59(3):419-23.  
<http://www.ncbi.nlm.nih.gov/pubmed/11880084>
63. Altarac S. A case of testicle replantation. *J Urol* 1993 Nov;150(5 Pt 1):1507-8.  
<http://www.ncbi.nlm.nih.gov/pubmed/8411440>
64. Sotto LS, Collins RJ. Perigenital Hematomas; analysis of forty-seven consecutive cases. *Obstet Gynecol* 1958 Sep;13:259-63.  
<http://www.ncbi.nlm.nih.gov/pubmed/13578292>
65. Propst AM, Thorp JM Jr. Traumatic vulvar hematomas: conservative versus surgical management. *South Med J* 1998 Feb;91(2):144-6.  
<http://www.ncbi.nlm.nih.gov/pubmed/9496865>
66. Virgili A, Bianchi A, Mollica G, et al. Serious hematoma of the vulva from a bicycle accident. A case report. *J Reprod Med* 2000 Aug;45(8):662-4.  
<http://www.ncbi.nlm.nih.gov/pubmed/10986686>

## 7. MASS CASUALTY EVENTS, TRIAGE AND DAMAGE CONTROL

### 7.1 Definition

A mass casualty event is one in which the number of injured people is significantly higher than the number of healthcare providers available (1). A mass casualty disaster does not therefore necessarily involve a large number of victims, but is related to the disproportion between the number of victims and the size of the medical team available (2,3). There is little published data on how best to handle these events.

### 7.2 Causes of mass casualty events

Potential mass casualty events include:

- the collapse of buildings or bridges;
- earthquakes;
- floods;
- tsunamis;
- train collisions;
- aircraft catastrophes;

- civilian terrorism.

Most mass injury caused by civilian terrorism is caused by explosions. The combined effects of blast, shrapnel, bomb projectiles, and burns result in multiple penetrating injuries involving several body systems and unpredictable degrees of damage.

### 7.3 Mechanisms of explosive injury

The mechanism of injury in explosions is divided into three phases:

- Primary blast injury: this is caused by the powerful shock wave that spreads from the site of the explosion. The most commonly injured organs are those containing air (lungs and ears), but any tissue can be damaged by the pressure wave passing through the body. Urogenital injuries as a direct result of primary blast have not been described in survivors of blast injuries.
- Secondary blast injury: this is produced by the debris and projectiles set in motion by the explosion. Penetrating injuries to the urogenital system, as to any organ, have been described.
- Tertiary injury: this occurs when the victim displaced by the blast wave hits a fixed object. An acceleration-deceleration mechanism produces severe injuries to organs, large blood vessels, and bones. Blunt renal, ureteral, and bladder injuries are induced by this mechanism. The patterns and severity of injury after explosions differ according to the location of the event. Explosions in confined spaces (e.g. buildings or buses) are more devastating than those that occur in open spaces because of amplification of the blast wave by reflection, and structural collapse, which can cause further injury.

### 7.4 Triage

Triage after mass casualty events is difficult, controversial, and full of difficult ethical and moral questions.

Disaster triage requires one to differentiate the few critically injured that can be saved by immediate intervention from the many with non-life-threatening injuries for whom treatment can be delayed.

Triage divides patients into four groups (4,5):

1. Patients with life-threatening injuries that require immediate intervention, presenting with airway compromise, Breathing failure and/or circulatory compromise from ongoing external haemorrhage.
2. Patients with severe but non-life-threatening injuries, in whom treatment can be acceptably delayed: major fractures, vascular injuries of the limbs and large soft tissue wounds.
3. 'Walking wounded' with minimal injuries.
4. Patients who are so severely injured that treatment would require allocation of resources and time that would deny other, more salvageable patients, timely care. These patients are given minimal or no treatment, and are re-evaluated when resources become available. There is no absolute definition for this group because triage is individualised according to the number and severity of casualties related to the available resources.

Triage contradicts the everyday principles of care, in which the goal is maximal and optimal care for every individual patient. Triage is necessary in mass casualty scenarios because of the need to provide effective treatment to the maximum number of salvageable patients within the limited resources.

#### 7.4.1 Primary triage

Primary triage begins when trained medical teams arrive at the event. It is concerned with the initial stabilisation and rapid evacuation of the prioritised victims to the nearest hospital.

#### 7.4.2 Secondary triage

Secondary triage begins at the medical facility that is receiving the mass casualties. The most experienced trauma surgeon who is not taking part in surgical or resuscitation procedures performs triage.

#### 7.4.3 Re-triage

Re-triage is performed frequently. After all the victims have undergone triage, the senior surgeon repeats triage and reclassifies patients as necessary.

Repeat triage is important. It avoids under-triage, which results in serious injury being missed, or over-triage, which results in some patients being assigned for immediate care when in fact they do not have critical injuries. The surgeon in charge is responsible for directing specialty surgical consultants, including urologists, and assigning them responsibility for specific patients as dictated by the specific injuries.

### 7.5 Principles of 'damage control'

Damage control is a prioritised three-phase approach to patients with major injuries (6). The first phase

consists of rapid control of haemorrhage, wound contamination, and faecal spillage using simple measures and temporary abdominal closure. The second phase is resuscitation in the intensive care unit (ICU), with the goal of restoring normal temperature, coagulation, perfusion, and oxygenation of tissues. Then, in the third stage, definitive surgery and abdominal wall closure is performed in stable patients.

Damage control is a life-saving strategy for patients with multiple injuries that has been adopted by trauma surgeons as a result of the observation that such patients often die from hypothermia, coagulopathy, and acidosis-induced physiological insults (7-9). In unstable patients, extensive and time-consuming reconstructive procedures could further destabilise the patient beyond recovery.

Identifying those critically injured patients who are candidates for damage control is difficult. The most senior trauma surgeon should make the decisions, in co-operation with other specialist surgeons.

Damage control principles have also been successfully adopted in the context of civilian mass casualty events, military field surgery, and initial treatment in rural areas with long-range transfers (9,10).

## **7.6 Urological aspects of 'damage control'**

In events involving mass casualties, the principles of triage and damage control are the same. Damage control can theoretically lower the mortality rates by allowing a limited number of qualified personnel to treat more patients.

Urologists are frequently consulted in patients with multiple injuries, and should be familiar with the damage control approach. Damage control is well suited to urological trauma, and should result in more efficient interaction with the trauma team, improved patient survival and lower morbidity.

In fact, because urological surgery is often elective, management of urological trauma has traditionally consisted of temporary measures followed by definitive surgery later on, which meshes well with modern damage control principles (8). It is important to be aware of damage control opportunities, and to maximise the quality of care with creative improvisation.

### **7.6.1 The urological consultation in the emergency room during mass casualty events**

#### **7.6.1.1 Responsibility and primary overall assessment**

After primary assessment and triage by the surgeon in charge, a urological consultation might be required for patients triaged to groups 2 (severe but not immediately life-threatening injuries) and 3 ('walking wounded' with mild injuries). The urologist might even become primarily responsible for these patients if they are stable and have few other injuries.

It is important to remember that under-triage can happen during a mass casualty event. A complete re-assessment of the patient assigned must therefore be performed, paying attention to the whole body so as to detect previously unnoticed injuries. This assessment should be quick but comprehensive. Conduct a rapid ABCDE survey (Airway, Breathing, Circulation, Disability or neurological status, Exposure) as dictated by advanced trauma life support (ATLS) principles (3). Urological care should begin only after the patient is cleared for the presence of other injuries.

#### **7.6.1.2 Imaging**

Evaluation of patients with penetrating and blunt abdominal or pelvic trauma usually includes imaging procedures such as contrast CT scans or retrograde cystourethrography (11,12). However, when mass casualty protocols are instituted, decisions on care must be made with a minimum of imaging procedures. In those situations, create a unidirectional flow of patients in order to avoid the bottleneck that usually occurs in imaging departments. The 'normal' pattern of sending patients for imaging and then returning them to the accident and emergency department for re-evaluation may not be feasible.

#### **7.6.1.3 Primary management**

Following initial primary evaluation, there are several possible scenarios:

1. Haemodynamically unstable patients with suspected intra-abdominal bleeding are transferred urgently to the operating theatre without any pre-operative imaging.
2. Stable patients with suspected renal injuries (penetrating trauma to the upper abdomen/flanks/lower chest, blunt abdominal trauma, and gross haematuria) should have delayed imaging once the protocols of mass casualties are cancelled, or when resources become available. These patients should be transferred to surgical wards and re-evaluated by the urologist as soon as possible.
3. Patients with suspected bladder or urethral injuries (pelvic fractures, high riding prostate on rectal examination, blood at the urethral meatus and/or inability to void) need to undergo imaging of the lower urinary tract, but this is not urgent as these injuries are not considered life-threatening (13).

4. In cases of suspected urethral injuries, the 'minimal acceptable treatment' will be one gentle trial of catheterising the bladder or insertion of a suprapubic cystostomy, followed by transfer of the patient to the surgical ward for later evaluation (14).
5. Bladder injuries following blunt or penetrating trauma are usually associated with other severe injuries (15) and thus require a prioritising surgical approach. The first priority in this scenario is the treatment of the associated life-threatening injuries. Bladder drainage is a sufficient first measure, but should be followed by delayed evaluation aiming to obtain accurate diagnosis and to distinguish between intraperitoneal and extraperitoneal bladder rupture.
6. Blunt injuries of the external genitalia are often isolated and can be managed conservatively. On the other hand, penetrating injuries of the genitalia are often associated with injuries of adjacent abdominal organs and haemodynamic instability (7). In mass casualty scenarios, external genital injuries should be operated on only if they have resulted in major haemorrhage. Surgery can be performed in the operating theatre or in a well-equipped shock room in the accident and emergency department. Compression dressings, or clamping/ligation of bleeding vessels are highly efficient manoeuvres that require a minimum of time. When severe haemorrhage is not present, any further diagnostic steps can be postponed. The patient can be transferred to the surgical ward for later re-evaluation followed by delayed reconstruction.

Urological consultations during a mass casualty scenario should be performed according to the following principles:

1. Rule out under-triage by the surgeon in charge, and perform a rapid primary survey of every patient.
2. Avoid unnecessary imaging procedures such as CT scans and retrograde urethrography. These procedures should be performed later, after re-evaluation of the patient, and after mass casualty protocols have been suspended.
3. Treat unstable patients who are to have surgery using damage control principles.
4. Stable patients with suspected renal injuries should be transferred to the surgical ward without imaging procedures. Re-evaluate if there is any change in their haemodynamic status, or when possible as dictated by the constraints of the mass casualty event. Patients managed in this delayed fashion should be treated according to traditional trauma management protocols.
5. 'Minimal acceptable' procedures should be performed in order to transfer patients to the surgical wards, e.g. suprapubic drainage of the bladder when bladder or urethral injuries are suspected, clamping and ligation of bleeding vessels from wounds to the external genitalia, etc.

#### **7.6.2 The urological consultation in the operating room during mass casualty events**

During emergency laparotomy, urologists are usually present in the operating theatre along with the general surgeons.

During mass casualty events, the principle of 'minimum acceptable intervention' for the 'maximum salvageable outcome' applies. Procedures should be directed at the rapid control of active bleeding, and management of urinary extravasation by simple diversion measures. Complex and time-consuming reconstructive procedures should be delayed whenever possible.

##### **7.6.2.1 Renal trauma**

The ultimate goal of all renal exploration in the setting of major traumatic renal injury is to control life-threatening bleeding and to preserve the maximal amount of viable renal parenchyma (16).

Renal reconstruction might be too time-consuming in the context of an unstable, multiply injured patient, or in the scenario of mass casualties in which the operating theatre should not be occupied by time-consuming reconstructive procedures (17).

Whenever major active haemorrhage of renal origin can be ruled out, it is best not to explore the injured kidney, even if a secondary delayed laparotomy will eventually be needed (18).

In unstable patients, packing the renal fossa with laparotomy pads and transferring the patient to the surgical ICU is best. Later, a planned second-look laparotomy is better than time-consuming reconstruction (19).

Alternatively, especially in briskly bleeding patients, speedy nephrectomy may be required.

Haemostatic techniques, many of which were developed for hepatic surgery and splenic trauma, can be used to control renal parenchymal bleeding (20):

- Mattress sutures through the parenchyma (renorrhaphy), similar to the sutures used in extensive hepatorrhaphy (7).
- Packing with dry folded laparotomy pads as described for peri-hepatic tamponade (7).
- Fibrin hemostatic agents, may be used to control bleeding.

- Absorbable mesh kidney bags maintain renal parenchymal fragments in contact with each other and ensure lasting haemostasis (21).
- Urinary extravasation may be ignored during the acute phase; acutely, urine leak will be drained by intraoperatively placed drains; defer ureteral stents or percutaneous nephrostomies.
- The abdomen is temporarily closed with towel clips or other measures.

Following urgent primary exploration, patients should be carefully monitored in an ICU. When they are sufficiently stable, begin radiological assessment of their injuries and plan their definitive operative management accordingly.

Delayed imaging is obtained by CT scan. If the extent of renal injury has not been clearly defined at the initial laparotomy (by choosing not to explore the retroperitoneal haematoma), a CT scan performed before the second laparotomy can help in decision-making. Computed tomography allows the existence and function of the contralateral kidney to be documented, the kidney injury to be graded according to traditional protocols, and a clinical plan to be created, which will then determine the selection of operative or non-operative management of the renal trauma, and whether nephrectomy or reconstruction is to be attempted.

In patients who are haemodynamically unstable after the initial acute damage control laparotomy, or in patients with deteriorating haemodynamic parameters (indicating ongoing or delayed bleeding), the management options are angiographic embolisation of the bleeding kidney or re-operation. This decision should be made according to several factors:

- The general status of the patient.
- The presence of associated injuries that have been treated according to damage control principles (bowel injuries, packed liver, or splenic injuries) and that need re-operation irrespective of the renal injury.
- The availability of angiography.

#### 7.6.2.2 Ureteral injuries

Although excellent results can be achieved with acute ureteral reconstruction, the surgery is time-consuming and might not be appropriate in the mass casualty setting.

During mass casualty events, diagnostic procedures such as the intraoperative injection of indigo carmine, intraoperative IVP or retrograde ueretropyelography that are intended to evaluate ureteral injuries should be discouraged.

If a ureteral injury is suspected but not clearly identified, a drain may be left in place. If urine leaks, a nephrostomy tube can be placed postoperatively.

If a partial ureteral tear is identified (less than half circumference) and the ureter looks viable, a double J-stent may be inserted over a guide wire through the tear, and the tear quickly closed with interrupted absorbable stitches.

When complete ureteral injuries are identified, definitive repair should not be performed. Dissection of the ureteral stumps should be avoided as it interferes with the blood supply. Instead:

- place a single J or 8 French feeding tube into the ureter;
- tie the distal end of the ureter over the tube;
- exteriorise it through a small stab incision;
- tie it to the skin.

The distal ureteral stump does not need to be ligated, and any unnecessary manipulation should be avoided.

Tying off the injured ureteral segment and inserting a percutaneous nephrostomy postoperatively (22,23) is a viable alternative, but is not the procedure of choice.

In rare, selected cases, nephrectomy is required to treat ureteral injury, but only in cases of severe associated injuries of the ipsilateral kidney (24).

Ureteral injuries are rarely life-threatening and should be addressed only after other injuries have been attended to. In an unstable patient, temporary measures to control urine spillage should be performed, for example:

- tying off of the injured ureteral segment and post-operative insertion of percutaneous nephrostomy (15,19);
- placement of a single J or feeding tube into the ureter, tying the distal end of the ureter over the tube and exteriorising it (15,19,23).

Intraoperative placement of a nephrostomy tube is time-consuming and should be avoided (15,19).

### 7.6.2.3 Bladder injury

Bladder injuries should be classified, when time and resources allow, as extraperitoneal or intraperitoneal. Extraperitoneal injuries can usually be managed with bladder drainage alone. Intraperitoneal injuries require surgical exploration and layered closure of the bladder wall (13). The degree to which penetrating bladder injury can be treated non-surgically is not known. However, non-surgical management of iatrogenic bladder injuries has been reported, and could be effective after penetrating injury (11,19).

Bladder injury was present in 1.15% of soldiers suffering a combat trauma. The main causes of injury were explosive devices, followed by high-velocity weapons (25).

- The majority of ruptures are extraperitoneal ( 54-86%, while 14-40% are intraperitoneal, with combined intra- and extraperitoneal ruptures account for 1.7-8% of all bladder ruptures (26-31).

#### 7.6.2.3.1 Auxiliary damage control measures

Examples of auxiliary damage control measures that could be applicable include:

- the placement of externalised ureteral stents can provide external urinary drainage in extensive bladder rupture (19);
- packing or arteriography and selective embolisation can be applied in cases of bladder haemorrhage in patients who are unsuitable for urgent pelvic exploration (13,19);
- the placement of a pelvic suction drain for urinary evacuation (19).

### 7.6.2.4 Urethral injury

Urethral injury of any kind is never life-threatening per se, but the associated injuries might cause haemodynamic instability. The patient is usually seen by the urologist during an operation performed because of the other injuries. In this situation, no matter whether the urethral tear is posterior or anterior, partial or complete, drainage through a suprapubic or urethral catheter should be obtained without prior imaging.

### 7.6.2.5 Injury of the external genitalia

Traumatic injuries of the external genitalia are much more common in men than in women, probably because of the anatomical differences (11,31). Blunt injuries of the genitalia are usually isolated, and can be managed conservatively. Penetrating injuries of the genitalia are often associated with injuries of adjacent abdominal organs and related haemodynamic instability (12). In mass casualty events, both types of injury should be managed by watchful waiting. Urethral or testicular imaging and surgical exploration should be deferred.

#### 7.6.2.5.1 Temporary damage control measures

Temporary damage control measure that might be applicable include:

- compression dressing of the penis;
- packing of penetrating testicular injuries;
- tampons for vulvar lacerations.

## 7.7 Summary

- Damage control surgery has become the standard approach in the management of unstable patients, and is especially useful in a mass trauma event.
- Medical teams should be well prepared ahead of time to deal with mass casualty events.
- All surgical sub-specialists involved in trauma management should be very familiar with the principles of triage and damage control.

## 7.8 References

1. Slater MS, Trunkey DD. Terrorism in America. An evolving threat. Arch Surg 1997 Oct;132(10):1059-66.  
<http://www.ncbi.nlm.nih.gov/pubmed/9336502>
2. Caro D. Major disasters. Lancet 1974 Nov;30(2(7892):1309-10.  
<http://www.ncbi.nlm.nih.gov/pubmed/4139541>
3. Weight JA, Krantz BE, Ali J, et al. Advanced Trauma Life Support Student Course Manual. American College of Surgeons Committee on Trauma, 6th edn. Chicago, 1997.
4. Frykberg ER. Medical management of disasters and mass casualties from terrorist bombings: how can we cope? J Trauma 2002 Aug;53(2):201-12.  
<http://www.ncbi.nlm.nih.gov/pubmed/12169923>
5. Jacobs LM Jr, Ramp JM, Breay JM. An emergency medical system approach to disaster planning. J Trauma 1979 Mar;19(3):157-62.  
<http://www.ncbi.nlm.nih.gov/pubmed/458880>

6. Rotondo MF, Schwab CW, McGonigal MD, et al. 'Damage control': an approach for improved survival in exsanguinating penetrating abdominal injury. *J Trauma* 1993 Sep;35(3):375-82.  
<http://www.ncbi.nlm.nih.gov/pubmed/8371295>
7. Feliciano DV, Moore EE, Mattox KL. Trauma damage control. In: Mattox KL, Feliciano DV, Moore EE (eds). *Trauma*, 4th edn, New York: McGraw-Hill, 2000, Chapter 39, pp. 907-931.
8. Hirshberg A, Mattox KL. 'Damage control' in trauma surgery. *Br J Surg* 1993 Dec;80(12):1501-2.  
<http://www.ncbi.nlm.nih.gov/pubmed/8298911>
9. Rignault DP. Recent progress in surgery for the victims of disaster, terrorism, and war--Introduction. *World J Surg* 1992 Sep-Oct;16(5):885-7.  
<http://www.ncbi.nlm.nih.gov/pubmed/1462624>
10. Holcomb JB, Helling TS, Hirshberg A. Military, civilian and rural application of the damage control philosophy. *Mil Med* 2001 Jun;166(6):490-3.  
<http://www.ncbi.nlm.nih.gov/pubmed/11413725>
11. Lynch TH, Martínez-Piñero L, Plas E, et al. EAU guidelines on urological trauma. *Eur Urol*. 2005 Jan;47(1):1-15.  
<http://www.ncbi.nlm.nih.gov/pubmed/15582243>
12. Krieger JN, Algood CB, Mason JT, et al. Urological trauma in the Pacific Northwest: etiology, distribution, management and outcome. *J Urol* 1984 Jul;132(1):70-3.  
<http://www.ncbi.nlm.nih.gov/pubmed/6726964>
13. Pansadoro A, Franco G, Laurenti C, et al. Conservative treatment of intraperitoneal bladder perforation during transurethral resection of bladder tumor. *Urology* 2002 Oct;60(4):682-4.  
<http://www.ncbi.nlm.nih.gov/pubmed/12385934>
14. Peterson NE. Genitourinary trauma, in Mattox KL, Feliciano DV, Moore EE (eds). *Trauma*, 4th edn, New York: McGraw-Hill, 2000, Chapter 37, pp. 839-79.
15. McAninch JW, Santucci RA. Genitourinary trauma, In: Walsh PC., Retik AB, Darracott Vaughan E, Jr., Wein AJ (eds). In: *Campbell's Urology*, 8th edn. Philadelphia: W.B. Saunders, 2002, Chapter 105, pp. 3707-3744.
16. Brandes SB, McAninch JW. Renal trauma: a practical guide to evaluation and management. *Digital Urology Journal*.  
<http://www.ncbi.nlm.nih.gov/pubmed/15349524>
17. Brandes SB, McAninch JW. Reconstructive surgery for trauma of the upper urinary tract. *Urol Clin North Am* 1999 Feb;26(1):183-99.  
<http://www.ncbi.nlm.nih.gov/pubmed/10086060>
18. Wessells H, McAninch JW, Meyer A, et al. Criteria for nonoperative treatment of significant penetrating renal lacerations. *J Urol* 1997 Jan;157(1):24-7.  
<http://www.ncbi.nlm.nih.gov/pubmed/8976207>
19. Coburn M. Damage control for urologic injuries. *Surg Clin North Am* 1997 Aug;77(4):821- 34.  
<http://www.ncbi.nlm.nih.gov/pubmed/9291984>
20. Shekarris B, Stoller ML. The use of fibrin sealant in urology. *J Urol* 2002 Mar;167(3):1218-25.  
<http://www.ncbi.nlm.nih.gov/pubmed/11832701>
21. Chaabouni MN, Bittard M. [Application of peri-renal prosthesis (vicryl mesh) in the conservative treatment of multiple ruptured kidney fragments.] *Ann Urol* 1996;30(2):61-3.  
<http://www.ncbi.nlm.nih.gov/pubmed/8767808>
22. Brandes S, Coburn M, Armenakas N, et al. Diagnosis and management of ureteric injury: an evidence based analysis. *BJU Int* 2004 Aug;94(3):277-89.  
<http://www.ncbi.nlm.nih.gov/pubmed/15291852>
23. Best CD, Petrone P, Buscarini M, et al. Traumatic ureteral injuries: a single institution experience validating the American Association for the Surgery of Trauma-Organ Injury Scale grading scale. *J Urol* 2005 Apr;173(4):1202-5.  
<http://www.ncbi.nlm.nih.gov/pubmed/15758748>
24. Hirshberg A, Wall MJ Jr, Mattox KL. Planned reoperation for trauma: a two year experience with 124 consecutive patients. *J Trauma* 1994 Sep;37(3):365-9.  
<http://www.ncbi.nlm.nih.gov/pubmed/8083894>
25. Serkin FB, Soderdahl DW, Hernandez J, et al. Combat urologic trauma in US military overseas contingency operations. *J Trauma* 2010 Jul;69 Suppl 1:S175-8.  
<http://www.ncbi.nlm.nih.gov/pubmed/20622614>
26. Deibert CM, Spencer BA. The association between operative repair of bladder injury and improved survival: results from the National Trauma Data Bank. *J Urol* 2011 Jul;186(1):151-5.  
<http://www.ncbi.nlm.nih.gov/pubmed/21575961>



27. Gomez RG, Ceballos L, Coburn M, et al. Consensus statement on bladder injuries. *BJU Int* 2004 Jul;94(1):27-32.  
<http://www.ncbi.nlm.nih.gov/pubmed/15217426>
28. Wirth GJ, Peter R, Poletti PA, et al. Advances in the management of blunt traumatic bladder rupture: experience with 36 cases. *BJU Int* 2010 Nov;106(9):1344-9.  
<http://www.ncbi.nlm.nih.gov/pubmed/20438556>
29. Avey G, Blackmore CC, Wessells H, et al. Radiographic and clinical predictors of bladder rupture in blunt trauma patients with pelvic fracture. *Acad Radiol* 2006 May;13(5):573-9.  
<http://www.ncbi.nlm.nih.gov/pubmed/16627198>
30. Rödder K, Olianias R, Fisch M. [Bladder injury. Diagnostics and treatment]. *Urologe A* 2005 Aug;44(8):878-82. [Article in German].  
<http://www.ncbi.nlm.nih.gov/pubmed/15959610>
31. Van der Horst C, Martinez Portillio FJ, Seif C, et al. Male genital injury: diagnostics and treatment. *BJU Int* 2004 May;93(7):927-30.  
<http://www.ncbi.nlm.nih.gov/pubmed/15142139>

## 8. ABBREVIATIONS USED IN THE TEXT

*This list is not comprehensive for the most common abbreviations*

|         |   |
|---------|---|
| AAST    | American Association for the Surgery of Trauma                |
| ATLS    | advanced trauma life support                                  |
| AVF     | arteriovenous fistulae  |
| BT      | transperineal, interstitial, permanent prostate brachytherapy |
| BUN     | blood urea nitrogen   |
| CT      | computed tomography   |
| DMSA    | dimercaptosuccinic acid                                       |
| EBRT    | external beam radiotherapy                                    |
| ePTFE   | polytetrafluoroethylene                                       |
| FAST    | focussed assessment with sonography for trauma                |
| GR      | grade of recommendation                                       |
| HIV     | human immunodeficiency virus                                  |
| hpf     | high-power field  |
| IBT     | iatrogenic bladder trauma                                     |
| ICU     | intensive care unit   |
| IED     | improvised explosive device                                   |
| IRT     | iatrogenic renal trauma                                       |
| ISS     | injury severity score   |
| IUhT    | iatrogenic urethral trauma                                    |
| IVP     | intravenous pyelography/pyelogram                             |
| IVU     | intravenous urography   |
| KUB     | kidney-ureter-bladder   |
| LE      | level of evidence   |
| MRI     | magnetic resonance imaging                                    |
| m/s     | metres per second   |
| MVA     | motor vehicle accident  |
| PCNL    | percutaneous nephrolithotomy                                  |
| rbc/hpf | red blood cells per high-power field                          |
| TOT     | transobturator tape   |
| TURP    | transurethral resection of the prostate                       |
| TVT     | tension-free vaginal tape                                     |
| UPJ     | ureteropelvic junction  |
| US      | ultrasonography   |

### **Conflict of interest**

All members of the Urological Trauma Guidelines working group have provided disclosure statements of all relationships that they have that might be perceived as a potential source of a conflict of interest. This information is publically accessible through the European Association of Urology website. This guidelines document was developed with the financial support of the European Association of Urology. No external sources of funding and support have been involved. The EAU is a non-profit organisation and funding is limited to administrative assistance and travel and meeting expenses. No honoraria or other reimbursements have been provided.