



Παροχέτευση ούρων: pigtail

Σταύρος Σφουγγαριστός, MD, PhD

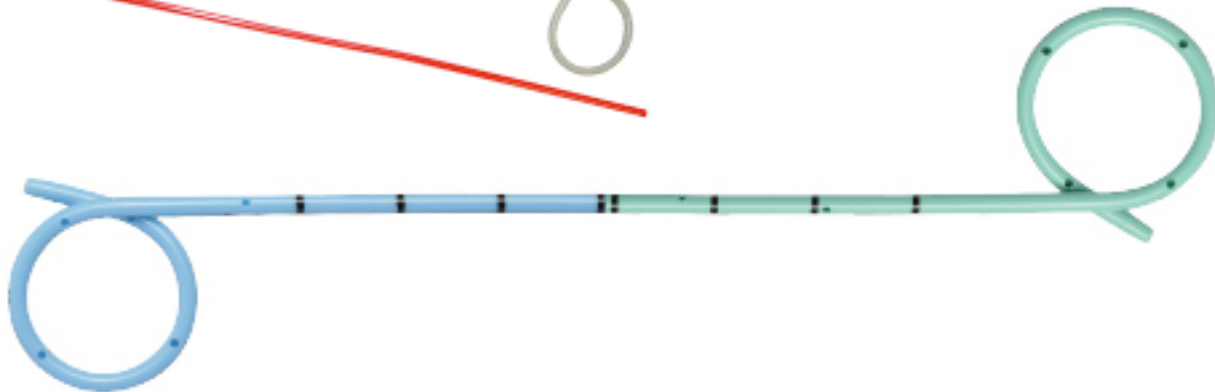
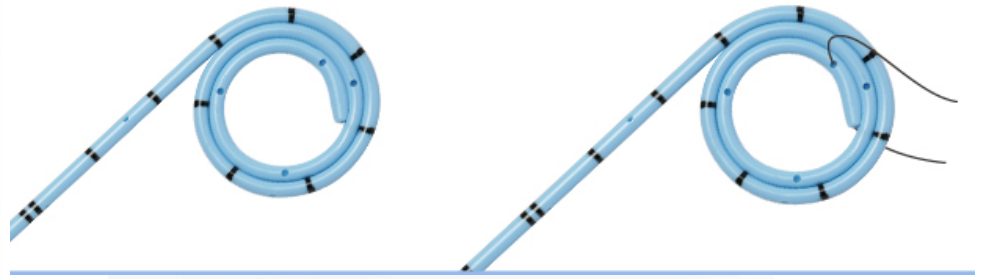
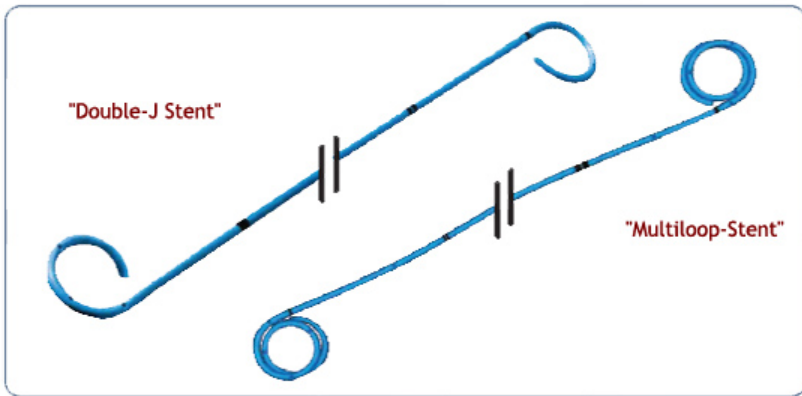
Ακαδημαϊκός Υπότροφος Α' Ουρολογικής Κλινικής ΑΠΘ

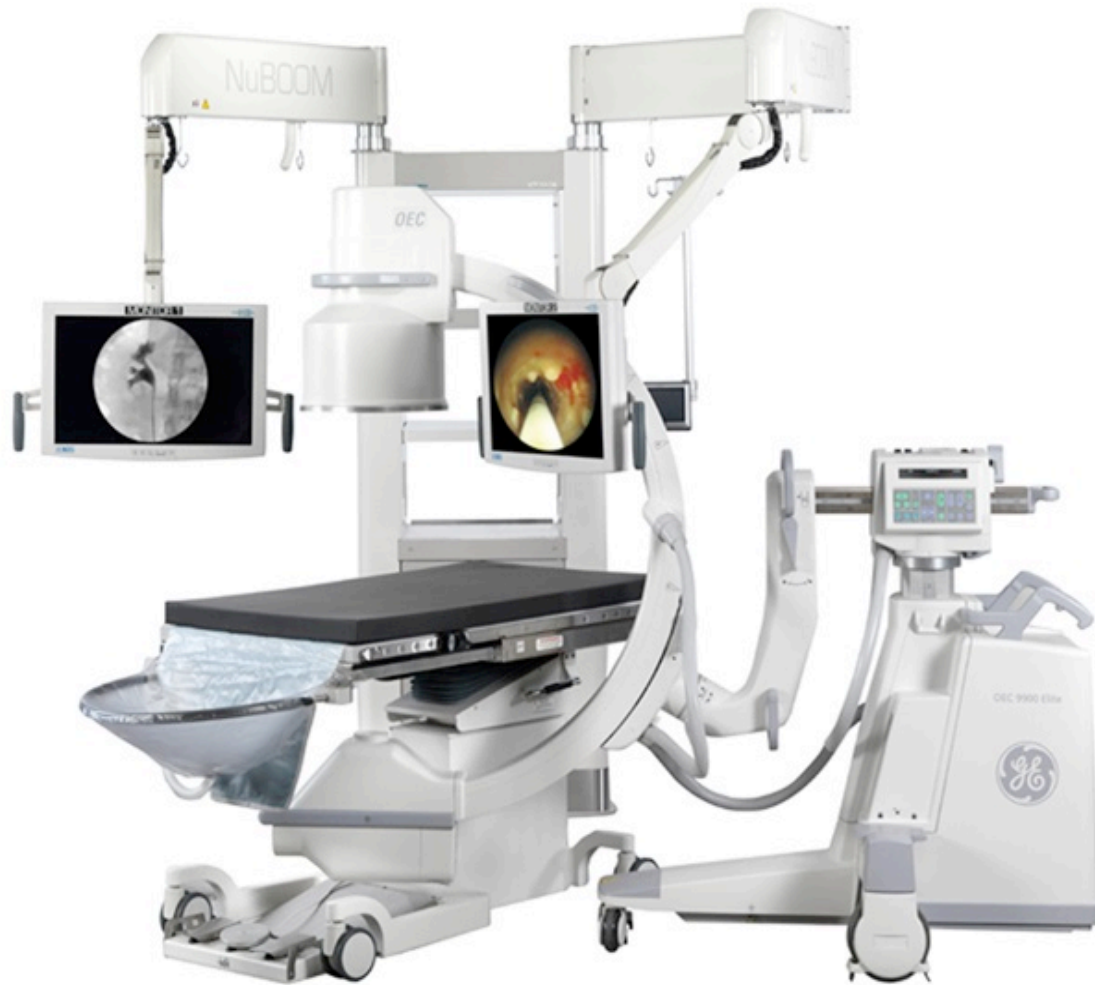



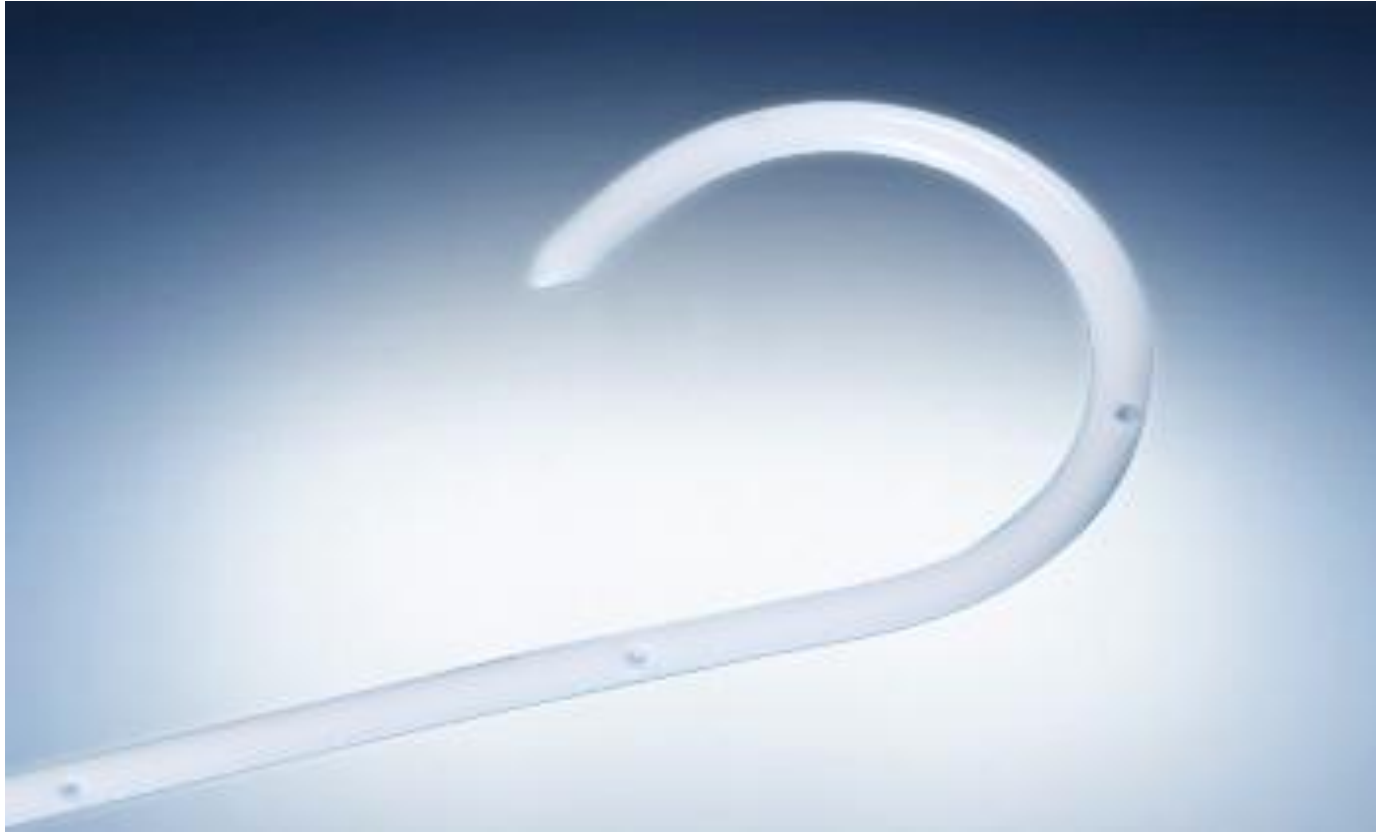no conflicts of interest








Κλειστού άκρου – Τέλος εποχής



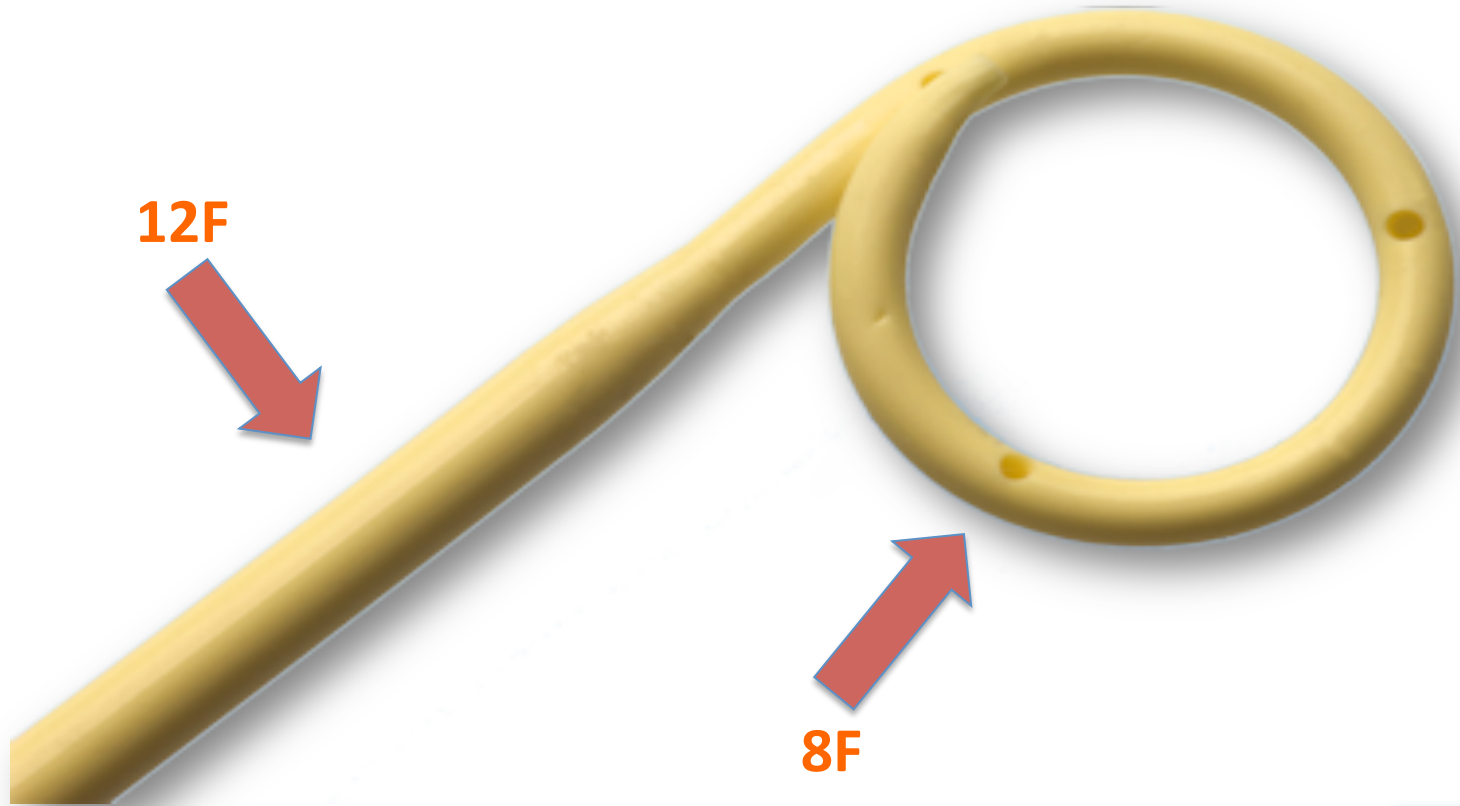
Βραχείας παραμονής



Μακράς παραμονής




Stents για στενώματα




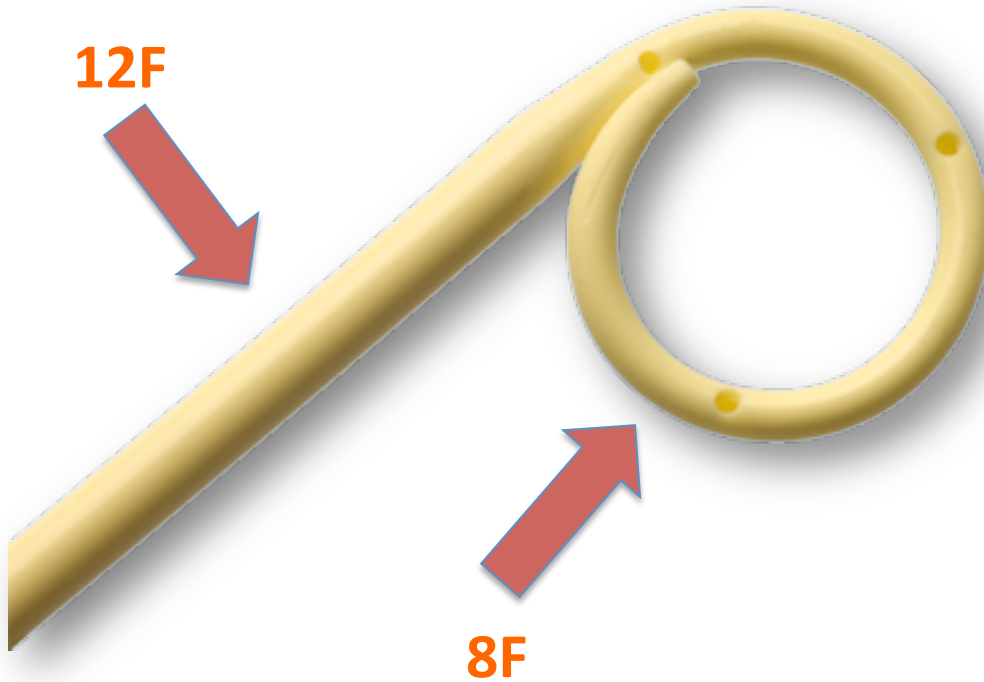
Tumor stents





Multi-loops stents




Post-pyelotomy stents




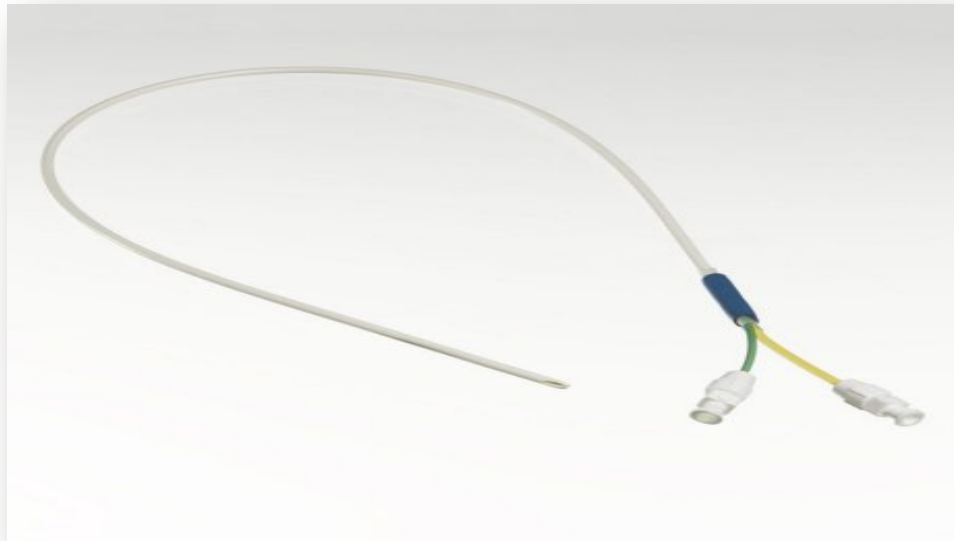
Σύρματα



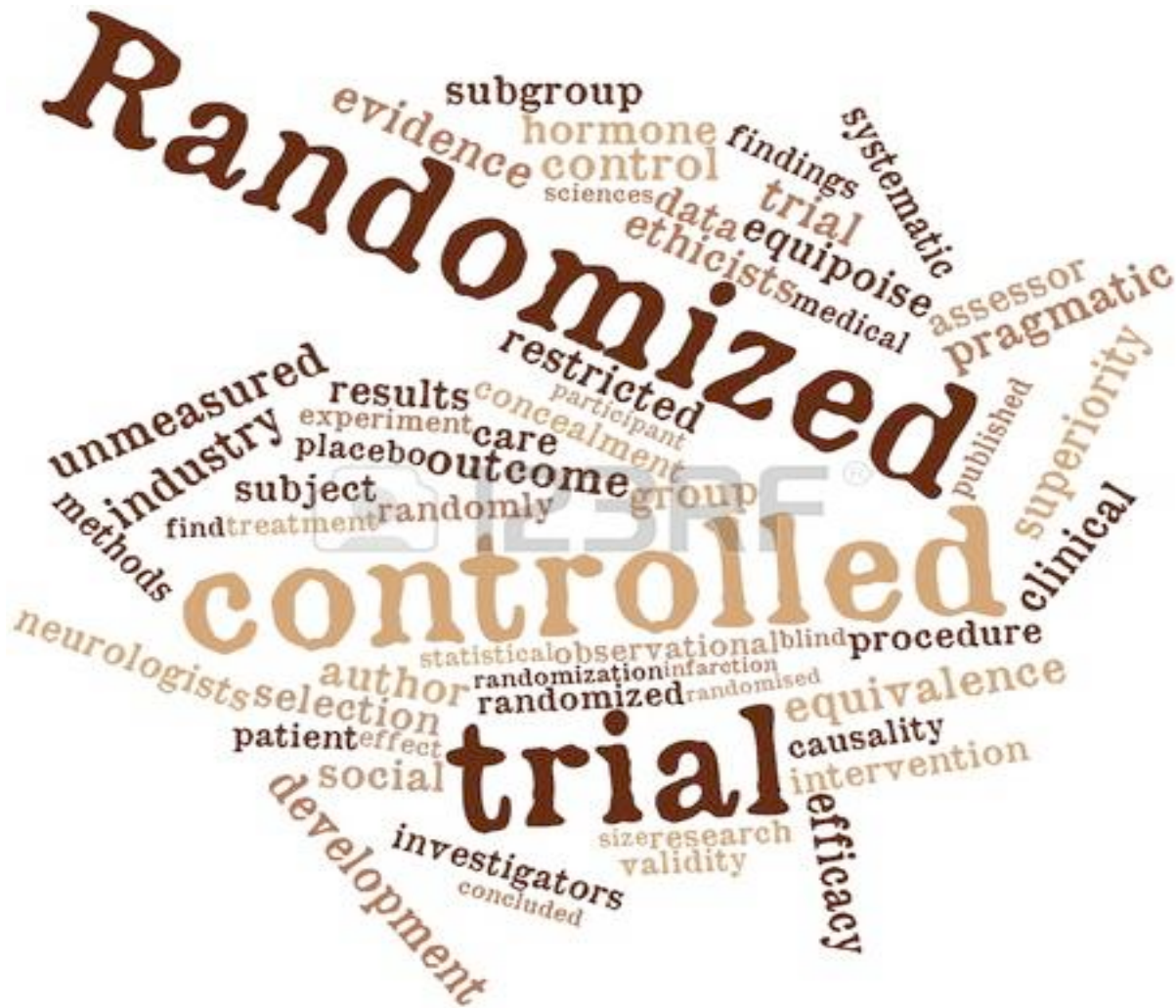Ουρητηρικοί καθετήρες



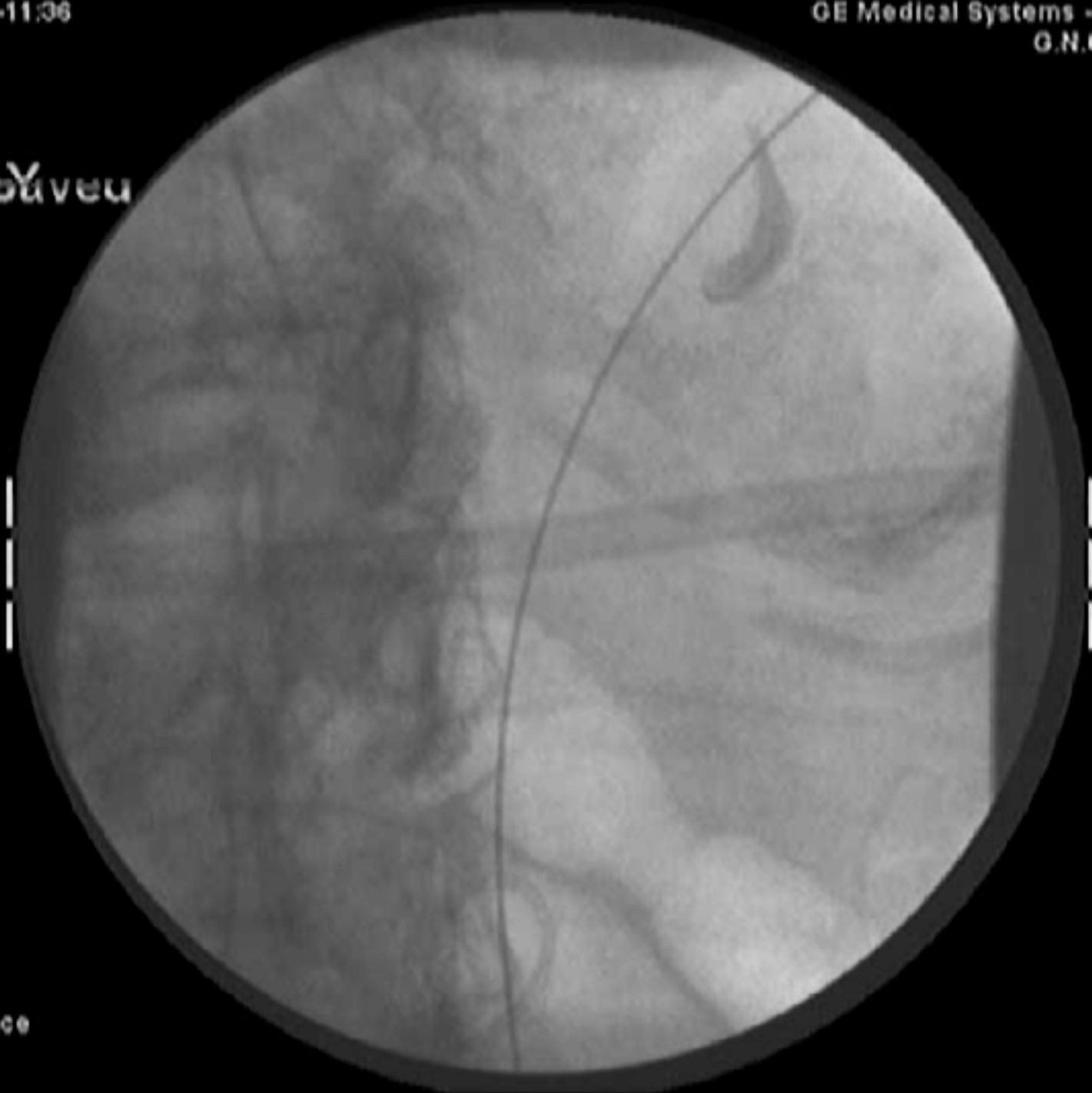Ουρητηρικοί καθετήρες



Αναισθησία;;;



ΝΟΤΑΥΕΝ



FNR : 4

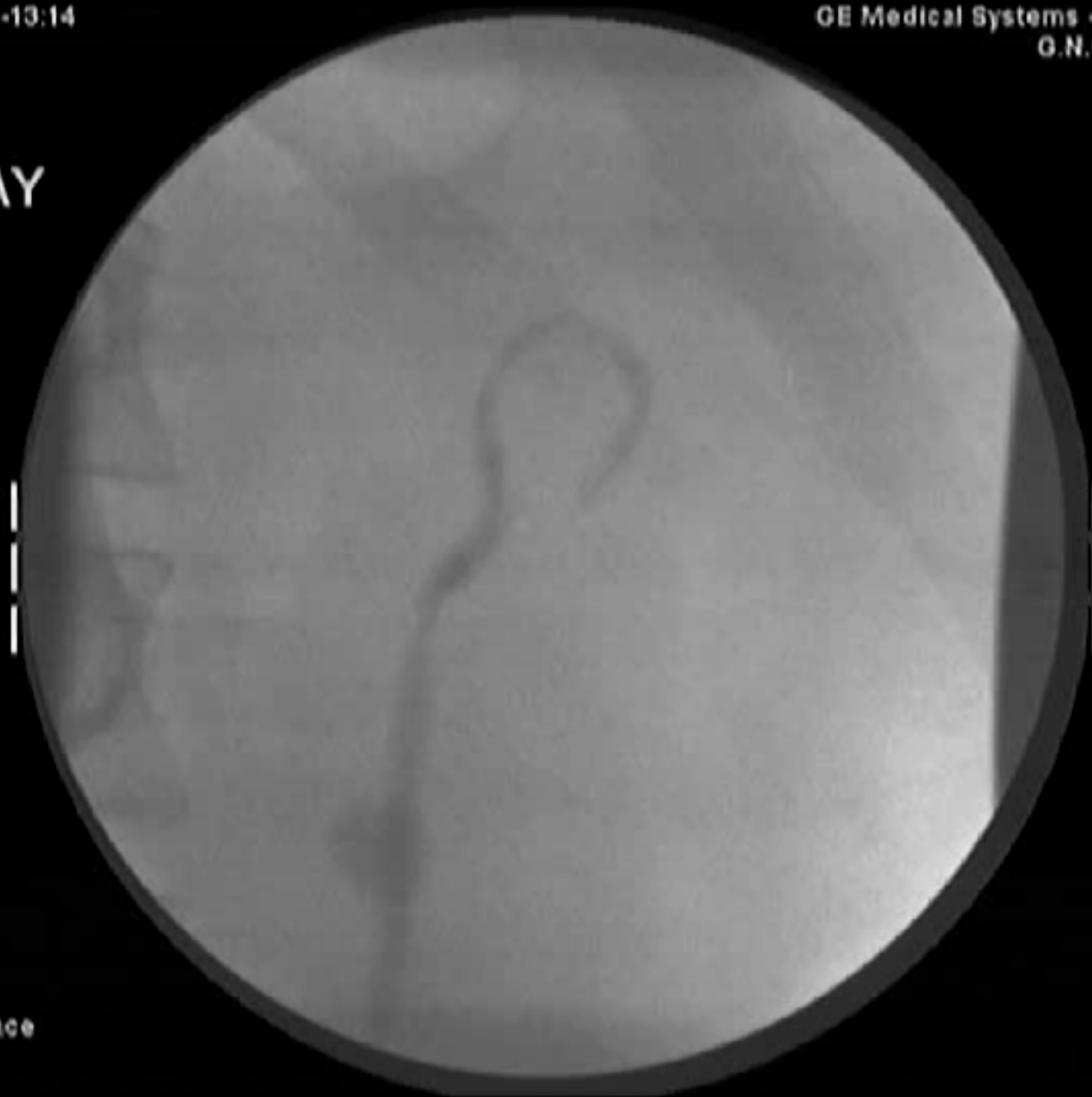Edge: 00

Free space
62

Def10/02-13:14

GE Medical Systems - Stenoscop
G.N.GENIMATAS


X-RAY



FNR: 4

Edge: 00

Free space
60



Def10/02-13:14

GE Medical Systems - Stenoscop
G.N.GENIMATAS

Not Saved

FNR: 4

Edge: 00

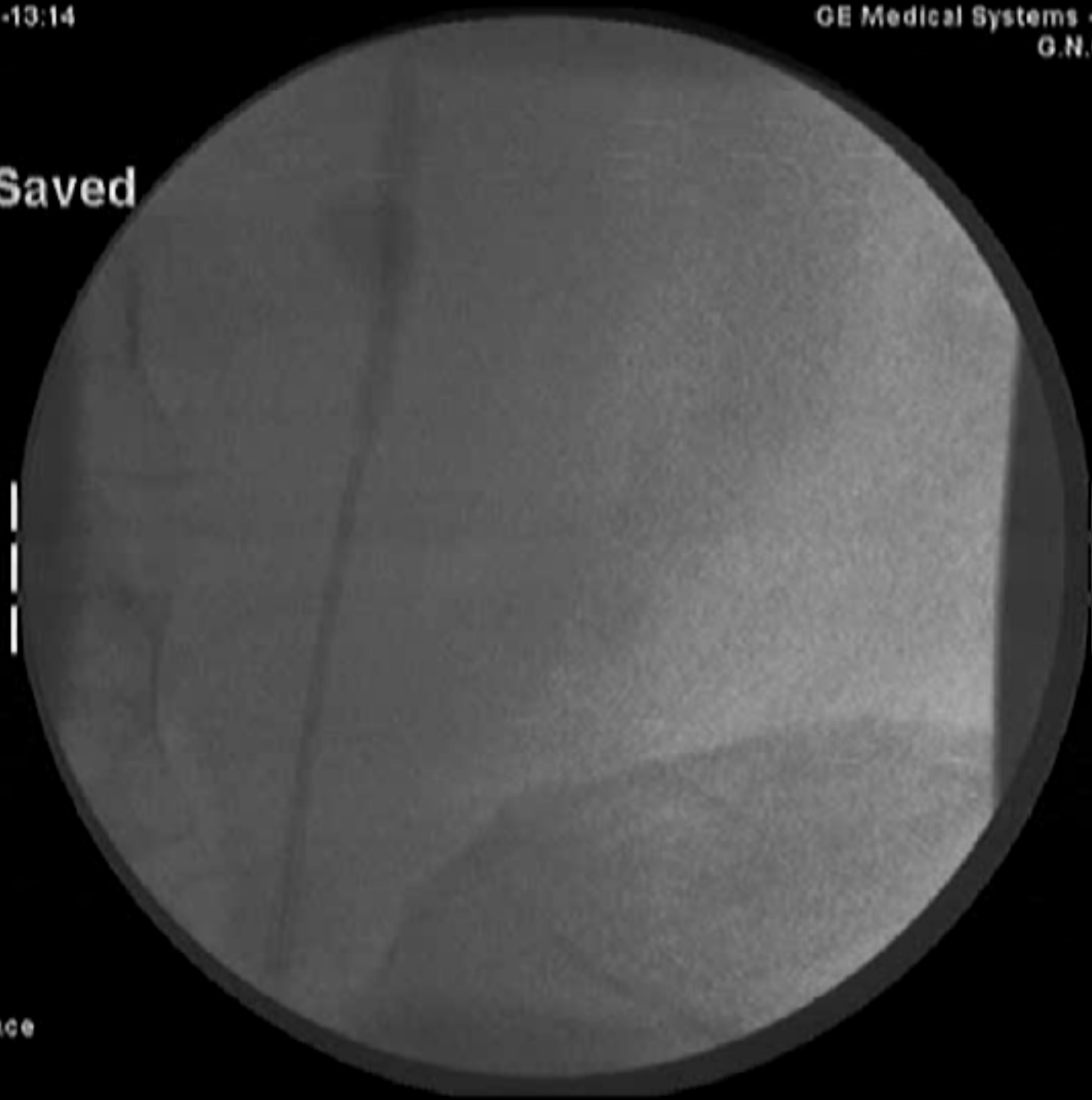Free space
60



Def10/02-13:14

GE Medical Systems - Stenoscop
G.N.GENIMATAS

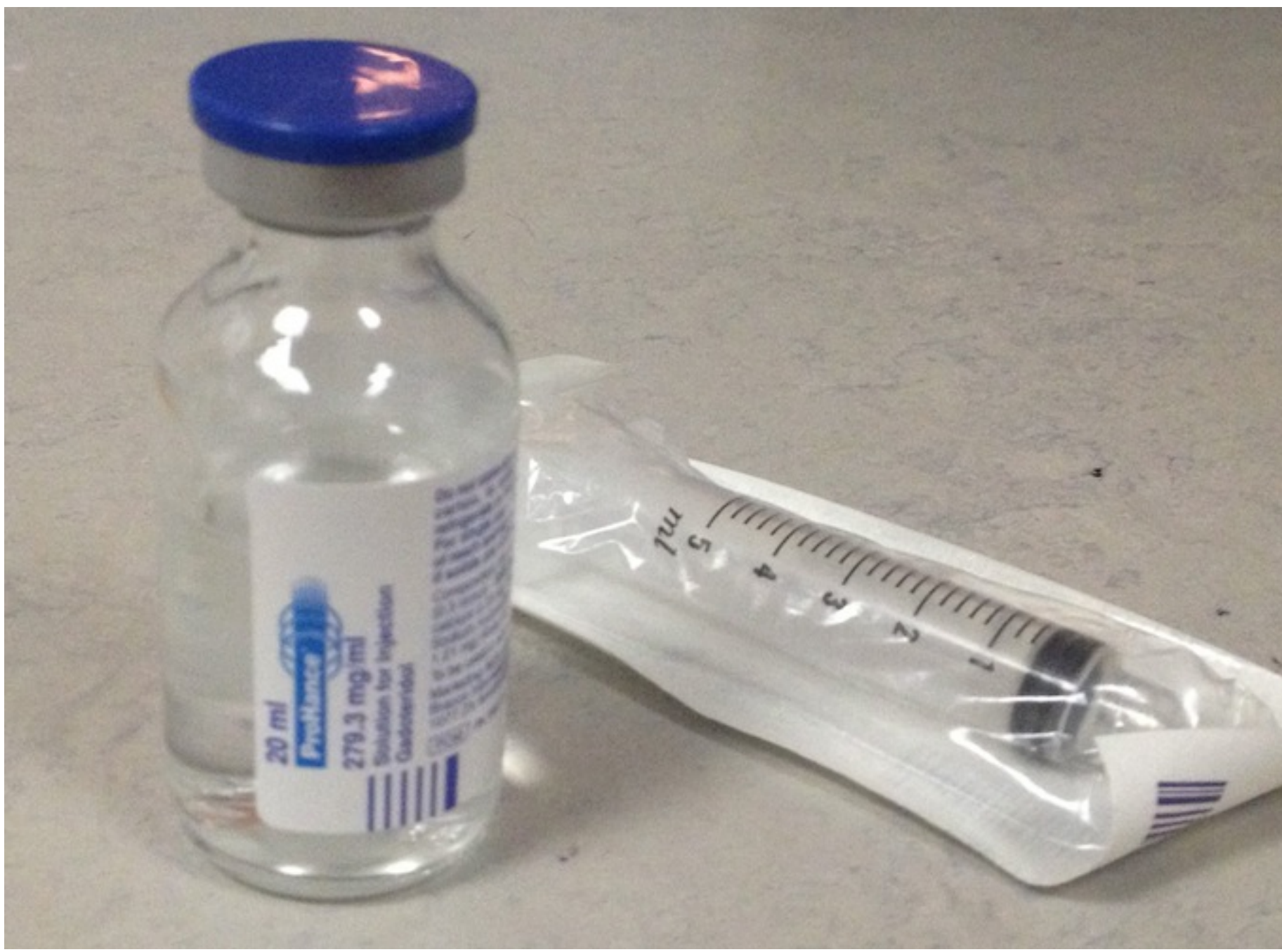Not Saved



FNR: 4

Edge: 00

Free space
60



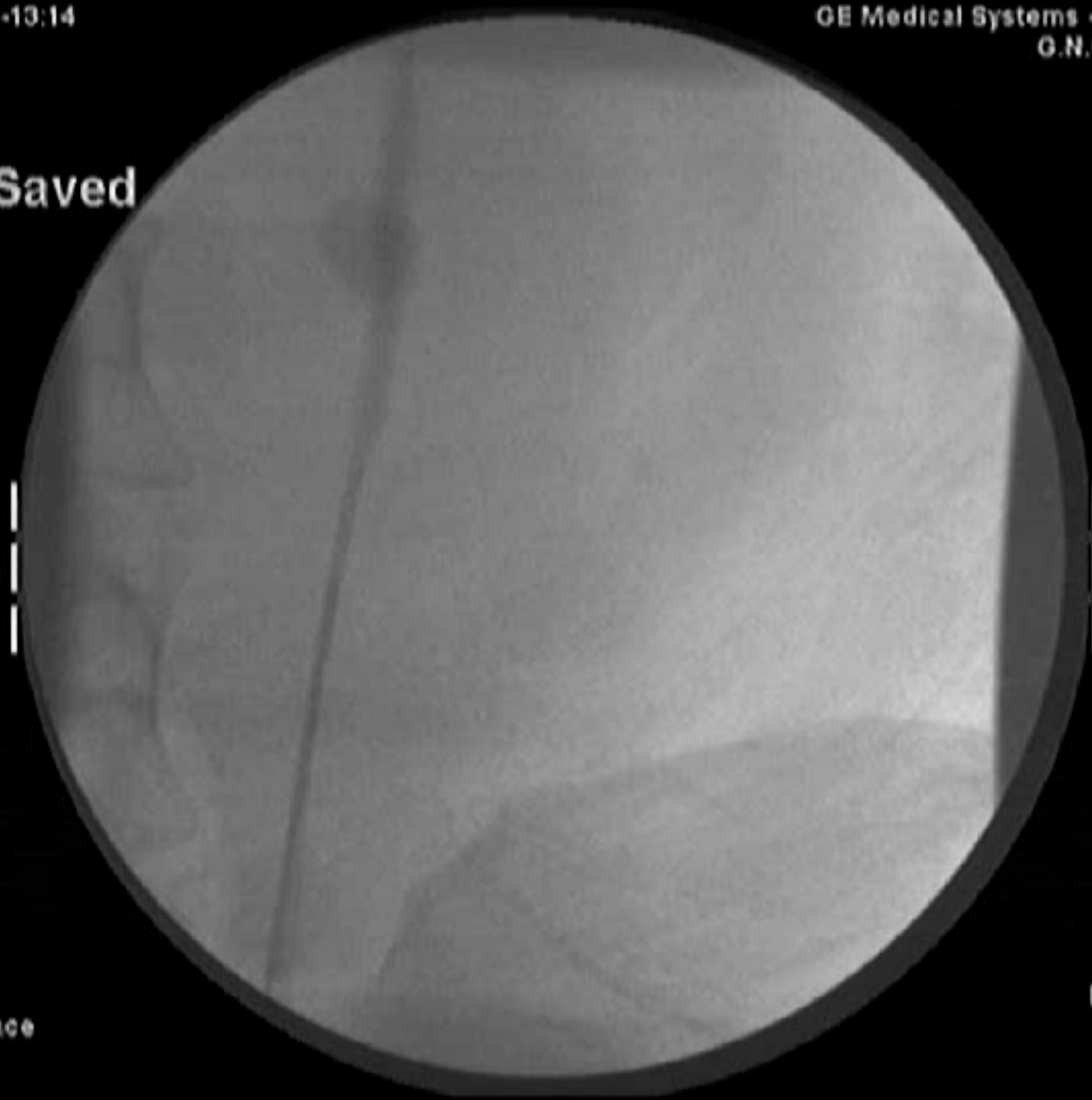20 ml
ProHance
279.3 mg/ml
Solution for Injection
Gadoteridol

5 ml
4
3
2
1

Def10/02-13:14

GE Medical Systems - Stenoscop
G.N.GENIMATAS


Not Saved



FNR: 4

Free space
60

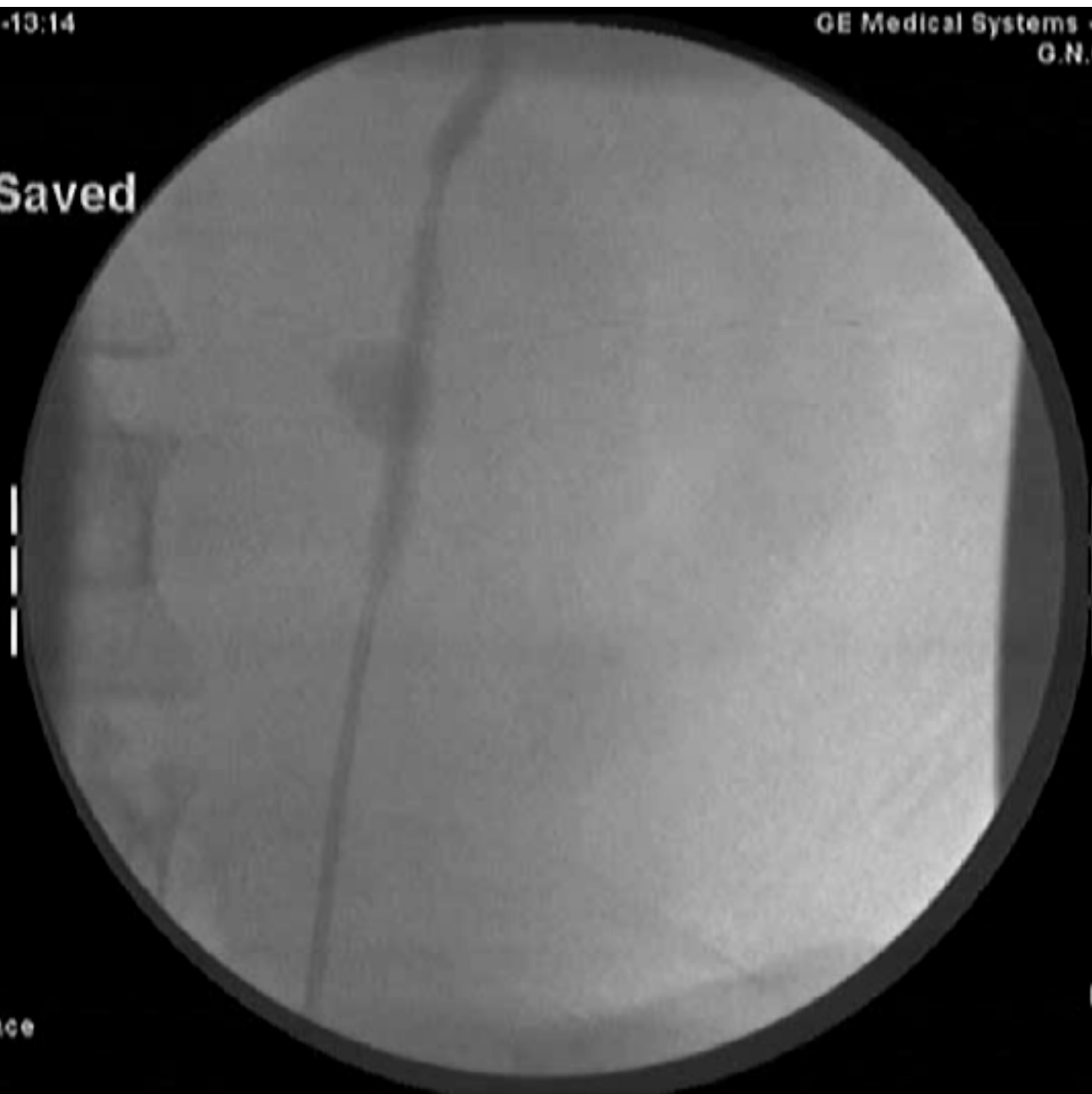Edge: 00
Zoom: 1.0
Bright: 100
Cont: 100



Def10:02-13:14

GE Medical Systems - Stenoscop
G.N.GENIMATAS

Not Saved



FNR: 4

Free space
60

Edge: 00
Zoom: 1.0
Bright: 100
Cont: 100

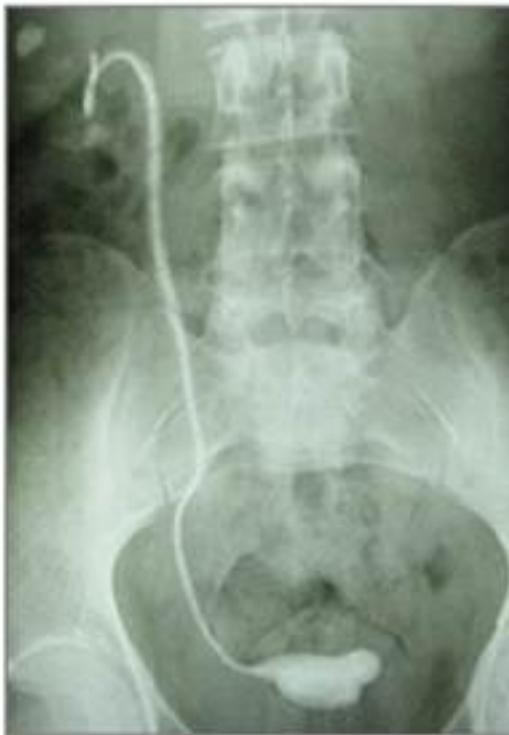The indwelling ureteric stent: a 'friendly' procedure with unfriendly high morbidity

S. RICHTER, A. RINGEL, M. SHALEV and I. NISSENKORN


Department of Urology, Sapir Medical Center, Kfar Sava, Sackler Faculty of Medicine, University of Tel Aviv, Israel

Table 1 The reasons for ureteric stenting, and the morbidity and complications of the 110 stents


<i>Indication/complication</i>	<i>No. of patients or stents (%)</i>	<i>Stent removed</i>
<i>Indication</i>		
Nephro-ureterolithiasis	88	
After abdominopelvic surgery	11	
Cancer of the prostate	5	
Retroperitoneal fibrosis	4	
After irradiation	2	
<i>Morbidity/complication</i>		
Fever and bacteriuria	34/110 (31)	19
Hydronephrosis on stenting	27/34	16/27
Unchanged	21	
Worse	3	
De novo	3	
Flank pain	17/110 (15.5)	8
Migration	9/110 (8)	
Fragmentation	11/110 (10)	11
Forgotten	5/110 (4.5)	



Νέα υλικά



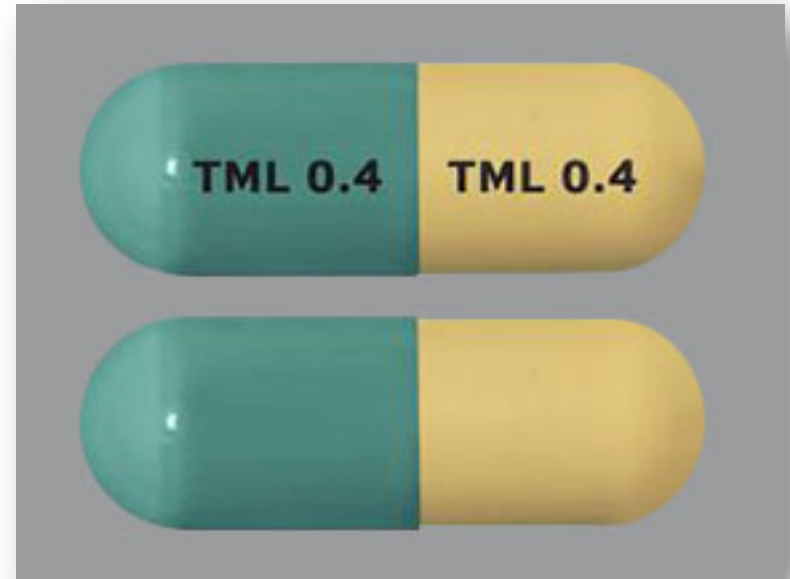Νέα υλικά



Lingeman et al. Assessing the impact of ureteral stent design on patient discomfort. J Urol 2009



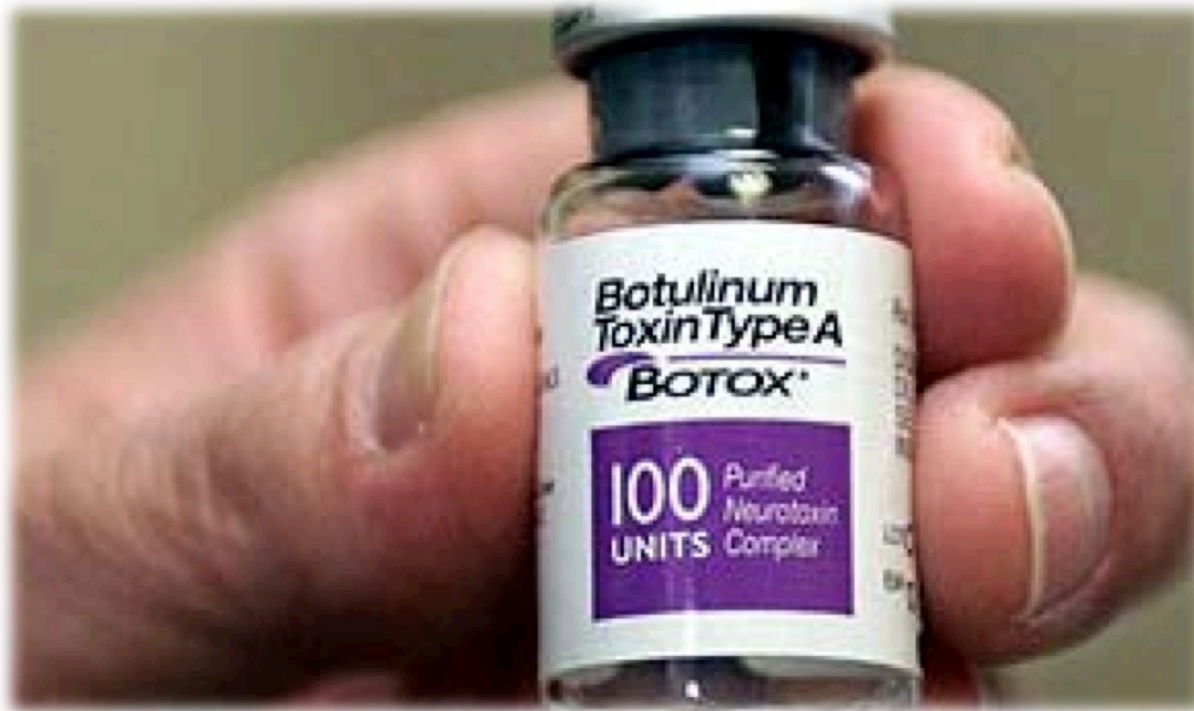Προφύλαξη



Yakoubi et al. Is there a role for α -blockers in ureteral stent related symptoms?
A systematic review and meta-analysis. J Urol 2011

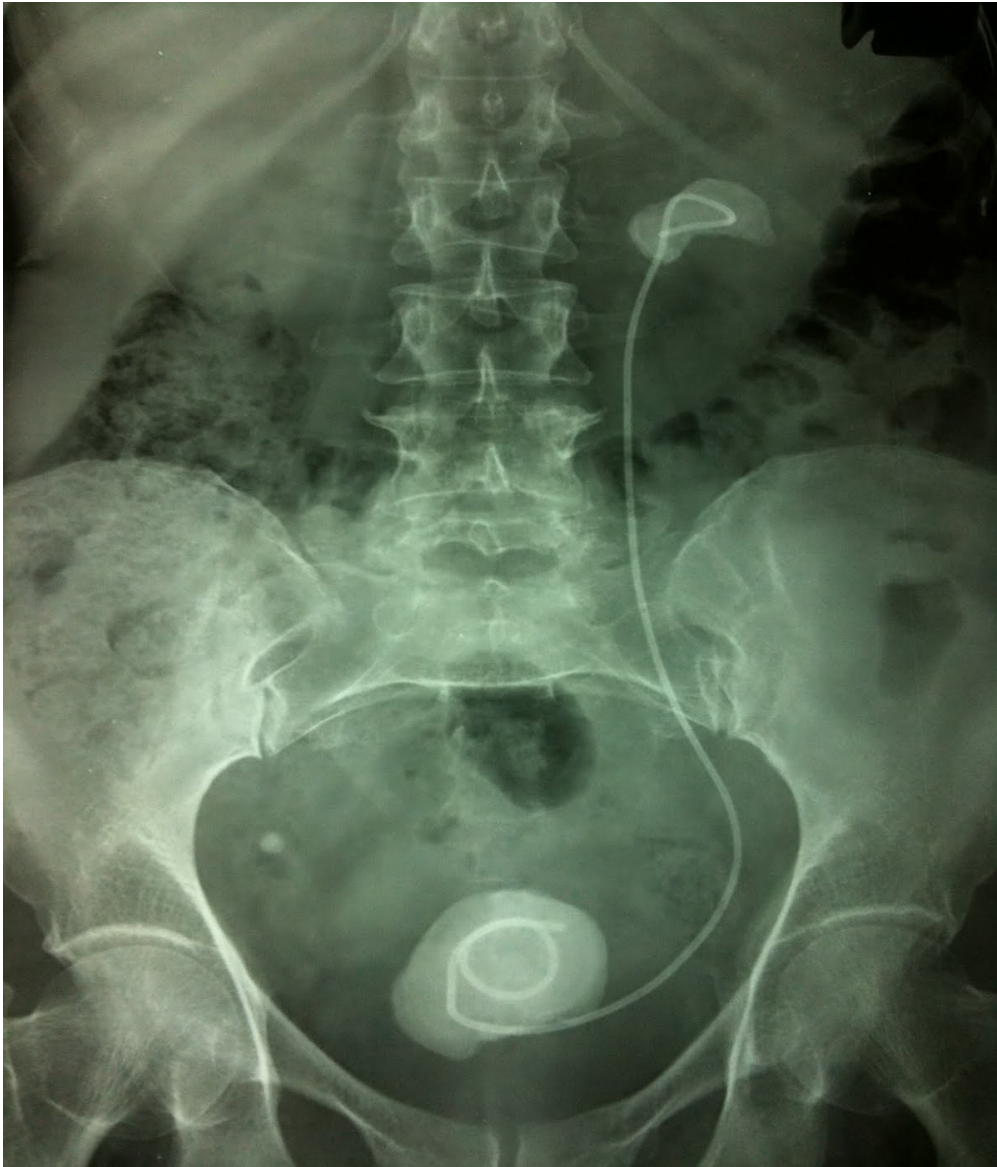

Προφύλαξη



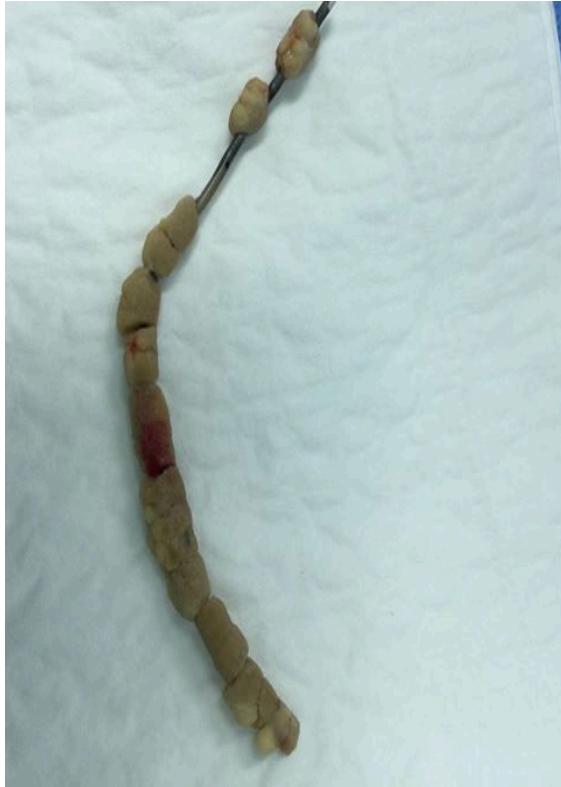Gupta et al. Prospective randomized evaluation of periureteral botulinum toxin type A Injection for ureteral stent pain reduction. J Urol 2010





Sighinolfi et al. Chemical and Mineralogical Analysis of Ureteral Stent Encrustation and Associated Risk Factors. Urology 2015

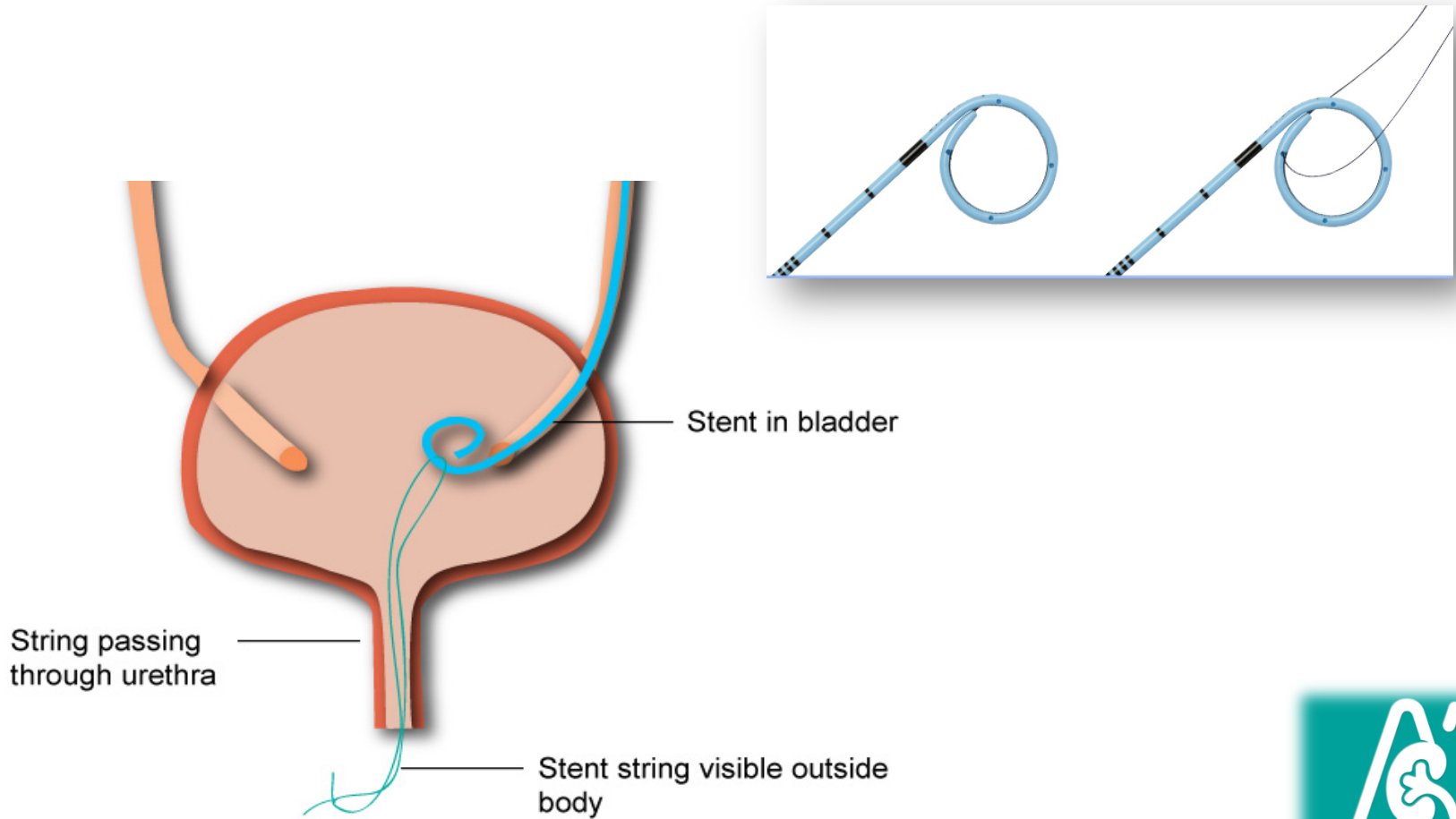




- ✓ **47% encrustation rate**
- ✓ **Time-dependent**
 - 26.8% at <6 weeks
 - 56.9% at 6-12 weeks
 - 75.9% at >12 weeks
- ✓ **13.9% resisted removal**
 - median indwelling time was 72d
- ✓ **3 stents irremovable**
 - median indwelling time 31d

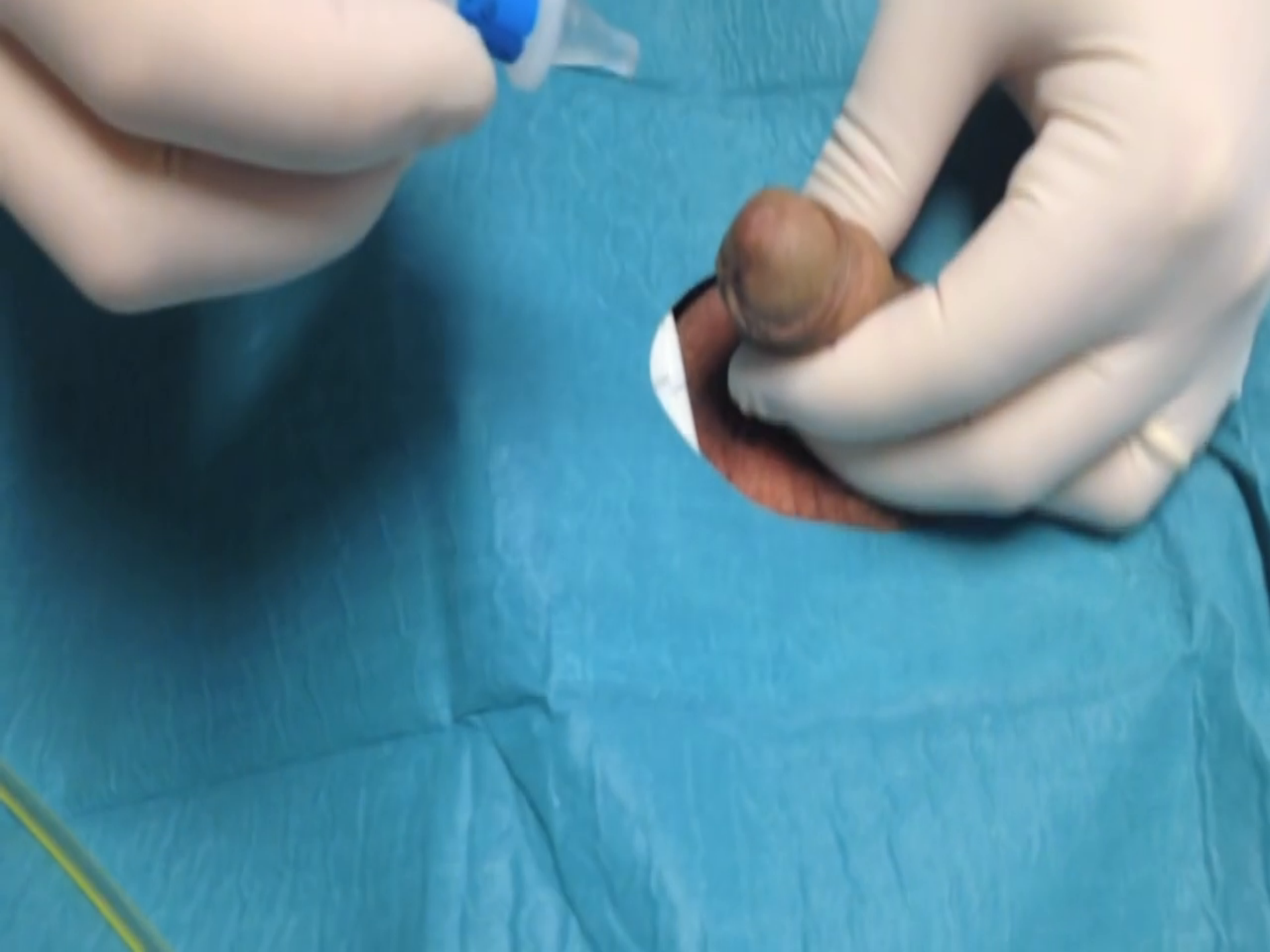

Νήμα αφαίρεσης

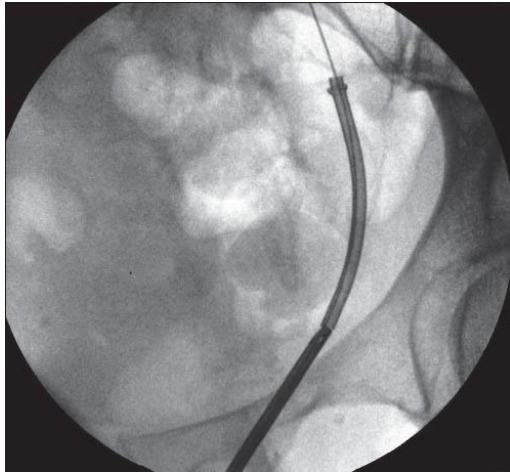


Magnetic black star

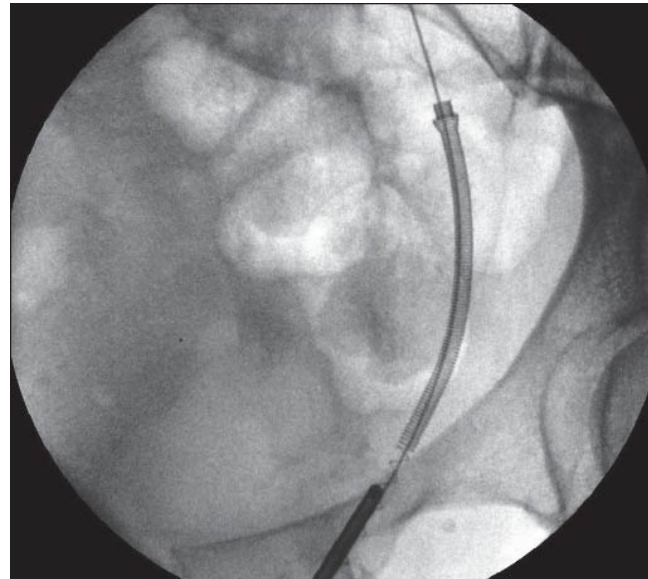




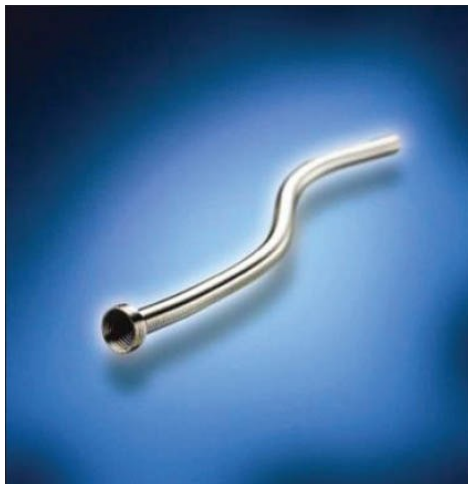Metallic stents



Wallstent



Memokath 051



Uventa



Resonance

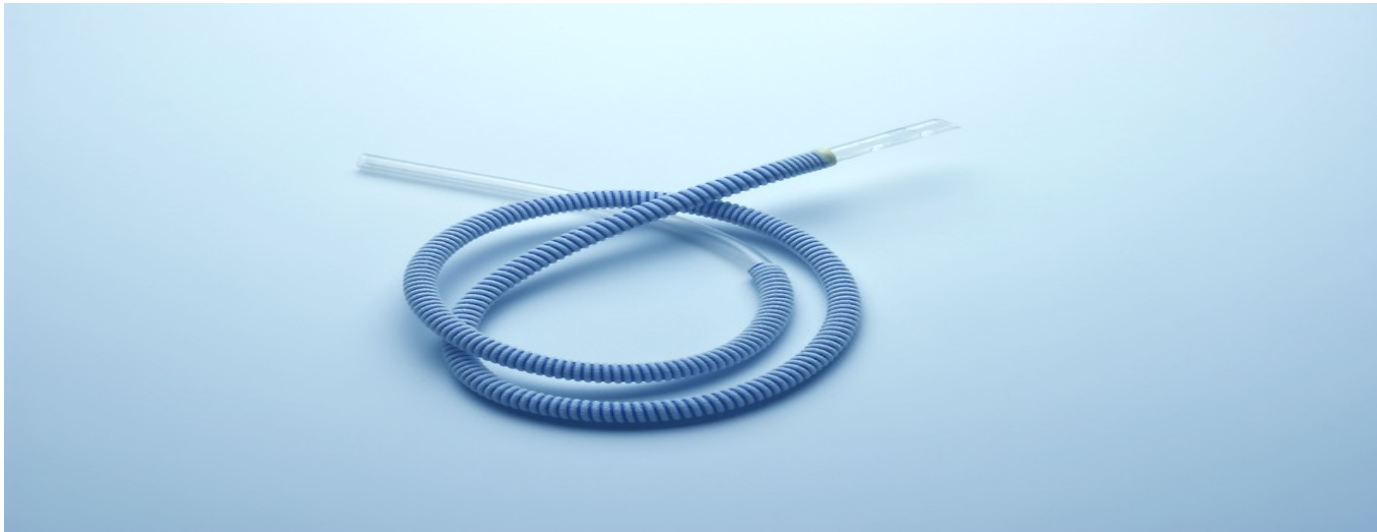

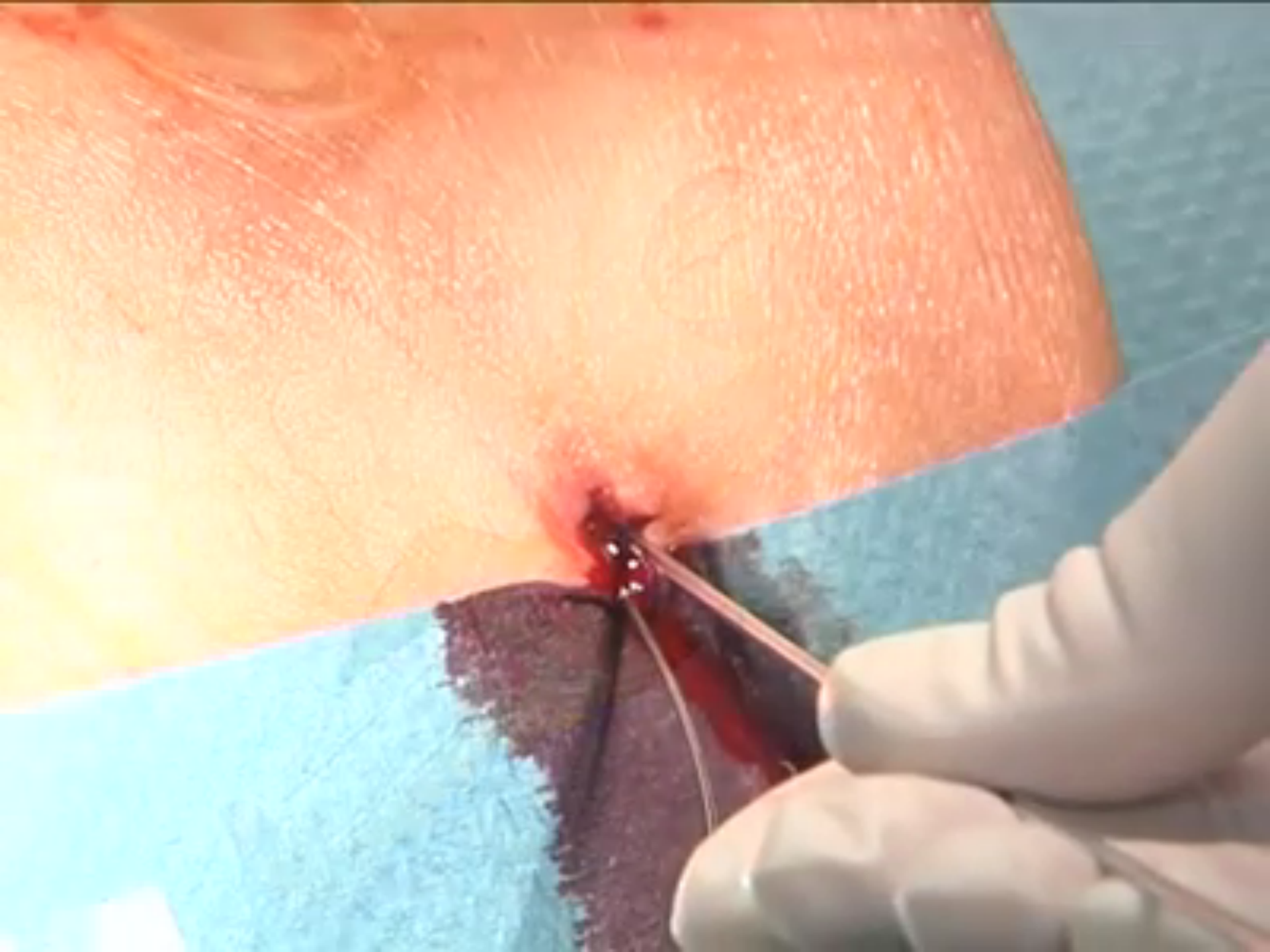
Allium ureteral stent





Υποδώρα ουρητηρική παράκαμψη





Ευχαριστώ!

